

5-1-2012

## **Hypertropia following Spontaneous Resolution of Brown's Syndrome**

Jerrold S. Kent  
*Western University*

Inas Makar  
*Western University, inas.makar@lhsc.on.ca*

Follow this and additional works at: <https://ir.lib.uwo.ca/paedpub>

---

### **Citation of this paper:**

Kent, Jerrod S. and Makar, Inas, "Hypertropia following Spontaneous Resolution of Brown's Syndrome" (2012). *Paediatrics Publications*. 2022.  
<https://ir.lib.uwo.ca/paedpub/2022>

This is an Open Access article licensed under the terms of the Creative Commons Attribution-NonCommercial-NoDerivs 3.0 License ([www.karger.com/OA-license](http://www.karger.com/OA-license)), applicable to the online version of the article only. Distribution for non-commercial purposes only.

# Hypertropia following Spontaneous Resolution of Brown's Syndrome

Jerrod S. Kent Inas Makar

Ivey Eye Institute, University of Western Ontario, London, Ont., Canada

## Key Words

Brown's syndrome · Hypertropia · Spontaneous resolution of Brown's syndrome

## Abstract

**Purpose:** To report a case of bilateral Brown's syndrome with unilateral spontaneous resolution causing hypertropia and significant head tilt.

**Case Report:** A 3 ½-year-old girl presented with bilateral typical Brown's syndrome and orthophoria in the primary position; she presented with unilateral resolution of right Brown's syndrome 6 months later, causing right hypertropia and gradually deteriorating left head tilt. She benefited from right superior rectus muscle recession to help correct her head posture.

**Conclusion:** This is the first report of a patient presenting with known bilateral Brown's syndrome with subsequent documented unilateral resolution causing a significant hypertropia of the resolved side and contralateral head tilt. Our case provides evidence in support of Clark and Noël's [Can J Ophthalmol 1993;28:213–216] hypothesis that patients who present with unilateral Brown's syndrome and contralateral inferior oblique muscle overaction might originally have had bilateral Brown's syndrome with spontaneous resolution of 1 side only.

## Introduction

Brown's syndrome is characterized by limited elevation in adduction with positive forced duction testing. The congenital form of Brown's syndrome has a constant restriction present in early childhood. The underlying etiology is controversial, but it is generally believed to be due to an abnormality of the superior oblique tendon as it passes through the trochlea. The incidence of spontaneous resolution of Brown's syndrome varies in the literature from 11 to 75% and can occur after years of follow-up. This report describes a child diagnosed with bilateral congenital Brown's syndrome who later on developed spontaneous unilateral resolution of Brown's syndrome.

Significant hypertropia was noted in the resolved side which required surgical intervention for an anomalous head posture.

## Case Report

A healthy 3½-year-old girl presented to the Pediatric Ophthalmology Service with bilateral restricted elevation in adduction. Her parents first noted an abnormal appearance of her eyes when she looked up. There were no preceding illnesses and the patient's birth history, family history and past medical history were non-contributory. On examination, the child's initial visual acuity was 20/30 in each eye. Ocular motility testing was notable for severe (–4) restriction of elevation of either eye in adduction, consistent with the clinical picture of bilateral Brown's syndrome. In the primary position, she was orthophoric, both at distance and near, with a cover test measuring 10 prism diopters (PD) of exotropia in upgaze. There was no evidence of abnormal head posture. She had evidence of fusion on the Worth 4-dot test at distance and near and stereopsis measuring 100 s of arc on the Titmus test. Surgery was not considered as the child was completely asymptomatic. A 6-month follow-up was scheduled.

At her 6-month follow-up appointment, she presented with full resolution of Brown's syndrome on the right side, although her parents had not noticed the change. There was no palpable click nor did she describe any pain or discomfort. She continued to have left-sided severe restriction of elevation in adduction (–4), moderate restriction of elevation in direct upgaze (–2) and mild restriction of elevation in abduction (–1) ([fig. 1](#)). Ocular movements were full in the right eye with evidence of increased elevation in adduction of the right eye on levoelevation, simulating mild inferior oblique overaction on the right side (+2). She showed fixation preference with the left eye. A cover test showed an incomitant intermittent right hypertropia measuring 18 PD in the primary position, 25 PD in right gaze and 20 PD in left gaze ([fig. 2](#)). Her right hypertropia was worse on right head tilt than on left head tilt. As a result, she adopted left head tilt to maintain alignment, which gradually deteriorated over the following 3 years as evidenced by clinical examination and according to her parents' observations. Her visual acuity remained at 20/30 in each eye and her stereopsis was stable, measuring 100 s of arc on the Titmus test, and she maintained evidence of fusion on the Worth 4-dot test at near only. Fundus examination showed no evidence of excyclotorsion in either eye. Subsequent follow-up visits showed gradual worsening of her left head tilt.

At the age of 6½ years, her parents requested surgical intervention to correct the constant significant left head tilt which was affecting her school activities. Measurements of her ocular motility prior to surgery showed constant right hypertropia in all positions of gaze, which measured more in upgaze and right gaze ([fig. 3](#)). The only position in which she was able to maintain good alignment was with a significant left head tilt. The child had surgery in the form of right superior rectus recession of 7 mm. Forced duction testing was performed under anesthesia before surgery, which showed mechanical restriction to elevation of the left eye in adduction, but was negative for the right eye in all directions. Postoperatively, the left head tilt improved significantly. She was able to maintain control of a residual intermittent right hypertropia of 16 PD in the primary position and the measurement of right hypertropia on right head tilt reduced significantly ([fig. 3](#)). She continued to demonstrate left Brown's syndrome in her latest follow-up appointment 2 years postoperatively, had no evidence of head tilt ([fig. 4](#)) and showed stable findings regarding stereopsis and fusion as measured preoperatively.

## Discussion

Spontaneous resolution of Brown's syndrome has been previously reported with an incidence ranging from 11 to 75% [1–5], although the 75% quoted included partial resolutions [3]. Our patient had a clinical presentation of bilateral Brown's syndrome with spontaneous resolution of the right side only. She subsequently developed a right hypertropia, which was initially intermittent in the primary position, but over a 3-year period she developed a progressively worsening head tilt, which became constant.

Because she preferred to fixate with the left eye, we postulated that she might have developed contracture of the right superior rectus muscle over the preceding 3-year period. Thus, we recessed the right superior rectus muscle to help reduce the right hypertropia across horizontal gaze, improve depression of the right eye and improve the head tilt.

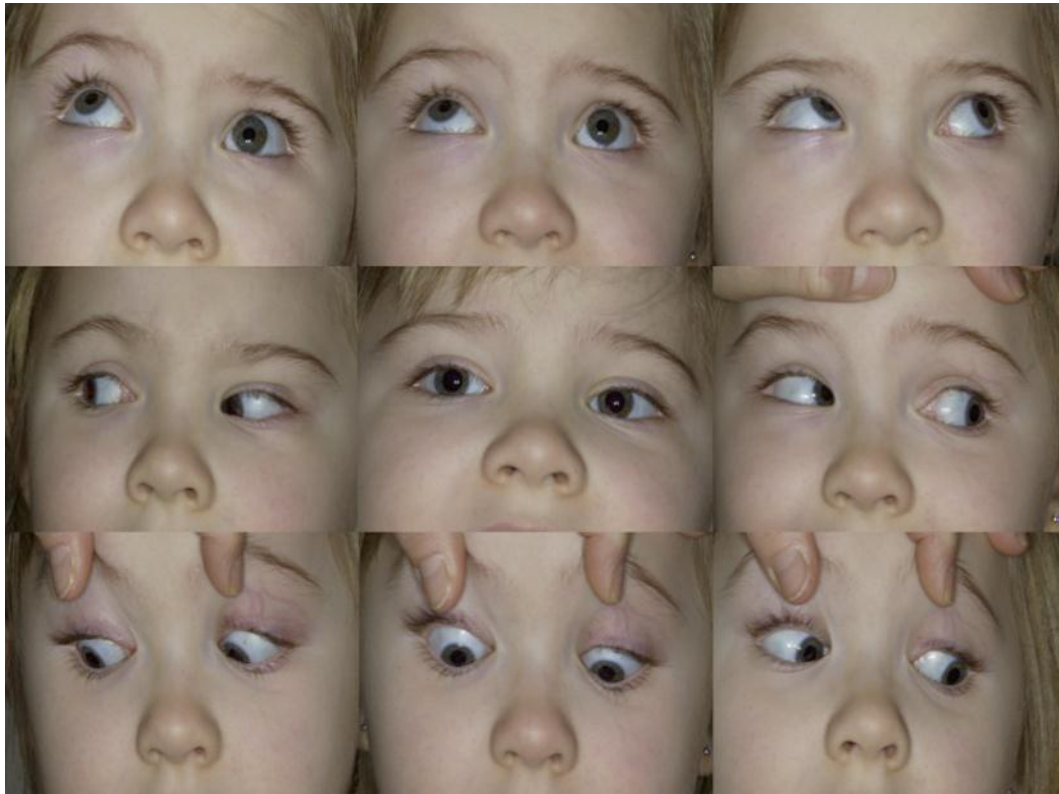Surgical options for Brown's syndrome that have been previously described include ipsilateral superior oblique muscle tenotomy, ipsilateral tendon expanders. Our patient could have received contralateral inferior oblique myectomy to address head posture and reduce hypertropia in the primary position and lateral gaze in the affected eye [6, 7]. Surgery on the ipsilateral superior oblique muscle, however, carries the risk of inducing an ipsilateral superior oblique palsy or scarring, while surgery on the contralateral inferior oblique muscle would not reduce the hypertropia in right gaze. Therefore, a contralateral superior rectus recession was chosen for this patient to try to improve hypertropia in all positions, allow fusion in the primary position and improve head posture. Performing right superior rectus recession of more than 7 mm may have offered a better postoperative result but, given the unusual presentation, a more conservative surgical approach was chosen.

Clark and Noël [6] suggested that patients with unilateral Brown's syndrome and contralateral inferior oblique muscle overaction may initially have had bilateral Brown's syndrome in infancy and undergone spontaneous resolution in 1 eye prior to first being examined and documented as bilateral. They postulated that in Brown's syndrome, the antagonist inferior oblique muscle contracts in an isometric fashion causing it to become contracted and fibrotic. With spontaneous resolution, they suggested that an imbalance of contractile forces results in the superior oblique muscle becoming relatively paretic compared to the inferior oblique, leading to an up-shoot in adduction. Our patient first presented with documented bilateral Brown's syndrome, but had a subsequent right-sided spontaneous resolution, leaving her with unilateral left Brown's syndrome and an apparent contralateral inferior oblique muscle overaction, just as previously postulated by Clark and Noël [6]. We suspect that the apparent right inferior oblique muscle overaction on levelevation could be explained by the mild limitation of elevation in abduction of the left eye with non-resolved left Brown's syndrome, rather than a true paresis of the right superior oblique muscle. Although an MRI was performed, the quality of the scan failed to show sufficient detail of the right superior oblique-trochlea complex to add an additional explanation for this clinical presentation.

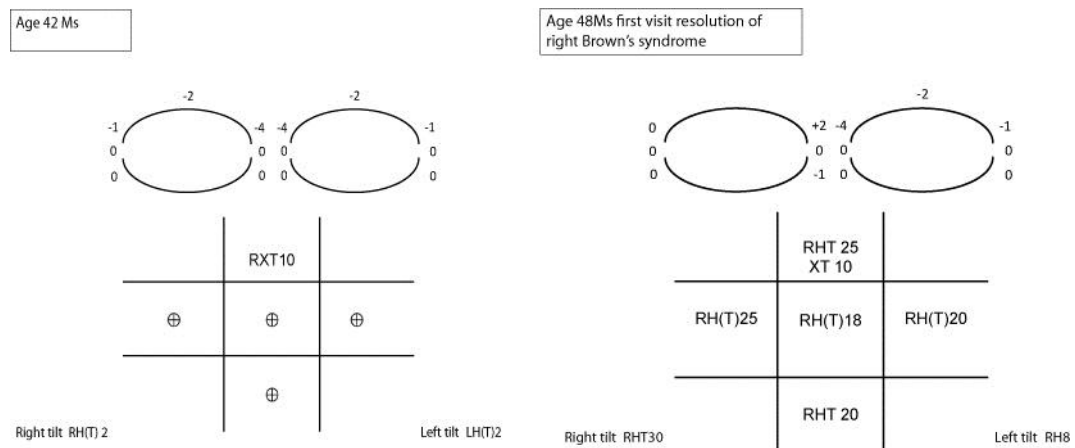
To our knowledge, this is the first report of a patient presenting with known bilateral Brown's syndrome with subsequent documented unilateral resolution causing a significant hypertropia of the resolved side and contralateral head tilt. Our case provides evidence in support of Clark and Noël's [6] hypothesis that patients who present with unilateral Brown's syndrome and contralateral inferior oblique muscle overaction might originally have had bilateral Brown's syndrome with spontaneous resolution of 1 side only.

#### Disclosure Statement

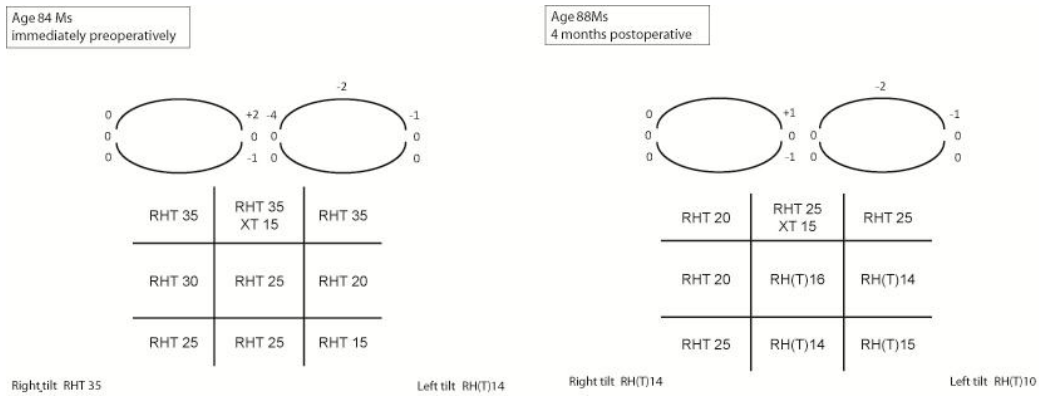
The authors declare that they have no conflict of interest.



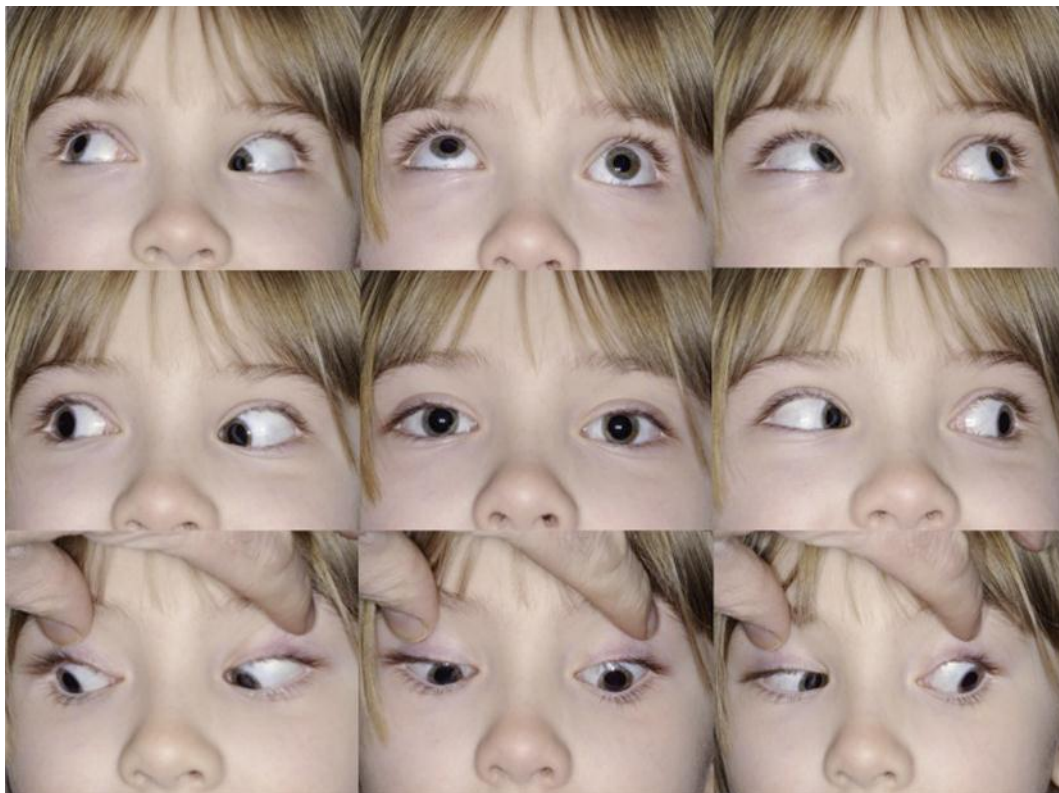**Fig. 1.** Preoperative photo showing left head tilt (center photo) and right hypertropia.



**Fig. 2.** Strabismus measurements at presentation and 6 months later.



**Fig. 3.** Strabismus measurements 1 week pre- and postoperatively.



**Fig. 4.** Postoperative photo showing resolution of the head tilt in the primary position.

## References

- 1 Wilson ME, Eustis HS Jr, Parks MM: Brown's syndrome. *Surv Ophthalmol* 1989;34:153–172.
- 2 Kaban TJ, Smith K, Orton RB, et al: Natural history of presumed congenital Brown syndrome. *Arch Ophthalmol* 1993;111:943–946.
- 3 Dawson E, Barry J, Lee J: Spontaneous resolution in patients with congenital Brown syndrome. *J AAPOS* 2009;13:116–118.
- 4 Lambert SR: Late spontaneous resolution of congenital Brown's syndrome. *J AAPOS* 2010;14:373–375.
- 5 Lowe RF: Bilateral superior oblique tendon sheath syndrome. Occurrence and spontaneous recovery in one of uniovular twins. *Br J Ophthalmol* 1969;53:466–471.
- 6 Clarke WN, Noël LP: Brown's syndrome with contralateral inferior oblique overaction: a possible mechanism. *Can J Ophthalmol* 1993;28:213–216.
- 7 Wright KW: Brown's syndrome: diagnosis and management. *Trans Am Ophthalmol Soc* 1999;97:1023–1109.