

1-1-2010

The utility of renal ultrasonography in the diagnosis of renal colic in emergency department patients

Marcia L. Edmonds
Western University, marcia.edmonds@lhsc.on.ca

Justin W. Yan
Western University

Robert J. Sedran
Western University

Shelley L. McLeod
Western University

Karl D. Theakston
Western University

Follow this and additional works at: <https://ir.lib.uwo.ca/paedpub>

Citation of this paper:

Edmonds, Marcia L.; Yan, Justin W.; Sedran, Robert J.; McLeod, Shelley L.; and Theakston, Karl D., "The utility of renal ultrasonography in the diagnosis of renal colic in emergency department patients" (2010). *Paediatrics Publications*. 1205.
<https://ir.lib.uwo.ca/paedpub/1205>

The utility of renal ultrasonography in the diagnosis of renal colic in emergency department patients

Marcia L. Edmonds, MD, MSc; Justin W. Yan, MD; Robert J. Sedran, MD, MSc; Shelley L. McLeod, MSc; Karl D. Theakston, MD, MSc

ABSTRACT

Objective: Computed tomography (CT) is an imaging modality used to detect renal stones. However, there is concern about the lifetime cumulative radiation exposure attributed to CT. Ultrasonography (US) has been used to diagnose urolithiasis, thereby avoiding radiation exposure. The objective of this study was to determine the ability of US to identify renal colic patients with a low risk of requiring urologic intervention within 90 days of their initial emergency department (ED) visit.

Methods: We completed a retrospective medical record review for all adult patients who underwent ED-ordered renal US for suspected urolithiasis over a 1-year period. Independent, double data extraction was performed for all imaging reports and US results were categorized as "normal," "suggestive of ureterolithiasis," "ureteric stone seen" or "disease unrelated to urolithiasis." Charts were reviewed to determine how many patients underwent subsequent CT and urologic intervention.

Results: Of the 817 renal US procedures ordered for suspected urolithiasis during the study period, the results of 352 (43.2%) were classified as normal, and only 2 (0.6%) of these patients required urologic intervention. The results of 177 (21.7%) renal US procedures were suggestive of ureterolithiasis. Of these, 12 (6.8%) patients required urologic intervention. Of the 241 (29.5%) patients who had a ureteric stone seen on US, 15 (6.2%) required urologic intervention. The rate of urologic intervention was significantly lower in those with normal results on US ($p < 0.001$) than in those with abnormal results on US.

Conclusion: A normal result on renal US predicts a low likelihood for urologic intervention within 90 days for adult ED patients with suspected urolithiasis.

Keywords: renal colic, urolithiasis, urologic intervention, ultrasonography, emergency department

RÉSUMÉ

Objectif : Le tomodensitogramme est une technique d'imagerie utilisée pour détecter les calculs rénaux. Cependant, on se préoccupe de l'exposition cumulative aux rayonnements associés aux appareils de tomodesitométrie. On utilise les échographies pour diagnostiquer l'urolithiase, évitant ainsi l'exposition aux rayonnements. L'objectif de cette étude était de déterminer la capacité des échographies à repérer les patients atteints de colique néphrétique et présentant un faible risque de devoir subir une intervention urologique dans les 90 jours suivant leur visite à l'urgence.

Méthodes : Nous avons réalisé une étude rétrospective des dossiers médicaux pour tous les patients adultes qui avaient subi, sur une période d'un an, une échographie rénale prescrite à l'urgence pour suspicion d'urolithiase. Nous avons procédé à l'extraction de données en double pour tous les rapports d'imagerie, et les résultats des échographies ont été classés ainsi : normaux, évocateurs d'une urolithiase, calcul rénal détecté, ou maladie non associée à une l'urolithiase. Nous avons examiné les dossiers médicaux pour déterminer combien de patients avaient subi ultérieurement une tomodesitométrie et une intervention urologique.

Résultats : Parmi les 817 échographies rénales prescrites pour suspicion d'urolithiase au cours de la période de l'étude, les résultats de 352 échographies (43,2 %) ont été classés comme étant normaux et de ce nombre, seulement 2 patients (0,6 %) ont dû subir une intervention urologique. Les résultats de 177 échographies rénales (21,7 %) étaient évocateurs d'urolithiase. De ce nombre, 12 patients (6,8 %) ont dû subir une intervention urologique. Parmi les 241 patients (29,5 %) pour qui l'échographie a permis de détecter un calcul rénal, 15 (6,2 %) ont dû subir une intervention urologique. Le taux d'intervention urologique était significativement plus faible chez les patients dont les résultats de l'échographie étaient normaux ($p < 0,001$) que chez ceux dont les résultats étaient anormaux.

Conclusion : Des résultats normaux d'une échographie rénale indiquent qu'il est peu probable qu'une intervention urologique soit nécessaire dans les 90 jours suivant la visite à l'urgence d'adultes chez qui l'on soupçonne une urolithiase.

From the Division of Emergency Medicine, University of Western Ontario, London, Ont., and the Schulich School of Medicine and Dentistry, University of Western Ontario, London, Ont.

Submitted Nov. 25, 2008; Revised Jul. 10, 2009; Accepted Aug. 24, 2009

This article has been peer reviewed.

CJEM 2010;12(3):201-6

INTRODUCTION

Renal colic is a common diagnosis in the emergency department (ED).¹ Controversy still exists as to the ED investigation of these patients, particularly with respect to deciding which patients require diagnostic imaging and which imaging modality is most appropriate.

Early renal colic imaging studies focused on the utility of intravenous pyelography (IVP) to confirm the presence or absence of calculi.^{2,3} These studies have shown that IVP is limited in its use and effectiveness because of the relatively high frequency of missing nonradiolucent stones. Additionally, IVP is time-consuming and requires intravenous contrast, which may cause adverse reactions in some patients. Plain radiography of the kidneys, ureter and bladder (KUB) has low reported sensitivities of 20% to 60%.^{4,5} KUB radiography is unable to detect radiolucent stones and does not provide any information about renal anatomy, but may be used in the follow-up of patients with identified radiopaque stones.

More recent studies have investigated the utility of computed tomography (CT) in the diagnosis of renal colic. A recent meta-analysis comparing CT and IVP demonstrated that nonhelical CT was superior to IVP in diagnosing acute urolithiasis.⁶ The sensitivity of CT to detect stones ranges from 91% to 100%, with specificities ranging from 91% to 97%.⁷⁻⁹ Because of its high sensitivity and specificity, CT is considered to be the gold standard for visualizing urinary calculi.¹⁰⁻¹³ Computed tomography has also been shown to be useful in identifying alternate diagnoses, particularly in older patients.¹⁴ Although the high diagnostic accuracy of CT is acknowledged, there is increasing concern about patient radiation exposure from CT.¹⁵ Several studies have shown that patients with renal colic are likely to undergo CT on multiple occasions, resulting in a potentially dangerous cumulative lifetime radiation exposure.^{16,17} Lee and colleagues¹⁸ demonstrated that ED physicians significantly underestimated the radiation dose from a single CT procedure. Most of these physicians did not believe that CT increased the lifetime risk of cancer. Given that ureterolithiasis is a benign and recurrent disease, emergency physicians should consider diagnostic strategies that limit radiation exposure.

Ultrasonography (US) is an imaging modality that may be used to investigate renal colic that does not expose the patient to radiation or contrast material.¹⁹ Although reported estimates of the sensitivity of US to visualize ureteral calculi vary widely and are lower than that of CT (12%–93%),^{20,21} US is highly accurate in

detecting hydronephrosis, perinephric fluid and abnormal urinary jets, which often indicate the presence of calculi with sensitivity nearing 100%.^{22,23} The specificity of US for direct or indirect findings compatible with ureterolithiasis is greater than 90% in some studies.^{15,21,24} Additionally, US has been recognized as a useful imaging tool for patients in whom radiation exposure should be avoided.²⁵

The objective of this study was to determine the ability of US to identify renal colic patients with a low risk of requiring urologic intervention within 90 days of their initial ED visit.

METHODS

We conducted a retrospective medical record review of all ED-ordered renal US procedures for suspected urolithiasis from 2 academic EDs (combined annual volume 110 000) over a 1-year period (Jan. 1–Dec. 31, 2006). The study protocol was approved by our institution's Health Sciences Research Ethics Board.

This study was conducted at a multicampus academic tertiary care centre affiliated with the University of Western Ontario, where 43 emergency physicians work at 2 ED sites. Our hospital has a specific protocol for renal US, which includes views of the KUB as well as observation for ureteric jets and postvoid scans where indicated. Renal US is available during daytime hours (0800–1600) 7 days a week. A consecutive cohort of all adult (≥ 18 yr) ED patients who underwent ED-ordered renal US for suspected renal colic were included in this study. Patients were identified from the institution's health records electronic database by filtering for adult ED patients who underwent renal US, assigned retrospectively by coding personnel at the hospital using the International Classification of Diseases intervention code 3.PC.30. Patients who underwent renal US for an indication other than suspected renal colic were excluded.

Before any data abstraction, we clearly defined all study variables and developed a standardized data collection tool. Two trained abstractors completed independent, double data extraction for all electronic patient records ($n = 817$) to determine the demographic characteristics, imaging results and need for urologic intervention in patients who underwent ED-ordered renal US.

Results of renal US were categorized into 4 mutually exclusive groups: "normal," "indirect evidence suggestive of ureterolithiasis," "visualized ureteric stone" or "disease unrelated to urolithiasis." The indirect evidence category included US results where hydronephrosis,

perinephric fluid or abnormal ureteric jets were seen, or where a nonobstructing intrarenal stone was identified (as reported by the staff radiologist). Discrepancies were resolved by consensus or review of the US report by a third reviewer. All records were reviewed to determine if any patient had subsequent imaging or a urologic procedure (extracorporeal shockwave lithotripsy, ureteric stent or cystoscopic extraction) within 90 days of their initial ED visit. Because of the retrospective nature of this study, the only adverse outcomes considered were the need for further imaging, hospital admission and need for urologic intervention.

Data were entered directly into a study-specific Microsoft Excel database (Microsoft Corp.). Abstractor inter- and intrarater reliability were calculated using Cohen κ for renal US result classification. Descriptive statistics were summarized using means and standard deviations (SDs) and differences in proportion of patients requiring urologic procedure. Rates of CT were assessed by use of the Pearson χ^2 statistic. Stone sizes were compared by use of Pearson correlation with a 2-tailed level of significance of 0.05. All data analyses were performed using SPSS 13.0 (SPSS Software Inc.).

RESULTS

From Jan. 1 to Dec. 31, 2006, there were 817 ED-ordered renal US procedures for suspected urolithiasis. Demographic characteristics are summarized in Table 1. The mean (SD) age of all patients was 43.6 (16.0) years, and 436 (53.4%) were male. Fifty-one (6.2%) patients were brought to the ED by ambulance, and the mean (SD) length of stay in the ED was 5.6 (3.4) hours. Thirty (3.7%) patients were admitted.

Figure 1 illustrates a flow diagram of 817 ED-ordered renal US procedures and the number of patients who

underwent subsequent CT and urologic intervention within 90 days of their initial ED visit. Of the 817 ED-ordered renal US, 352 (43.2%) were classified as normal, 177 (21.7%) were classified as suggestive of ureterolithiasis

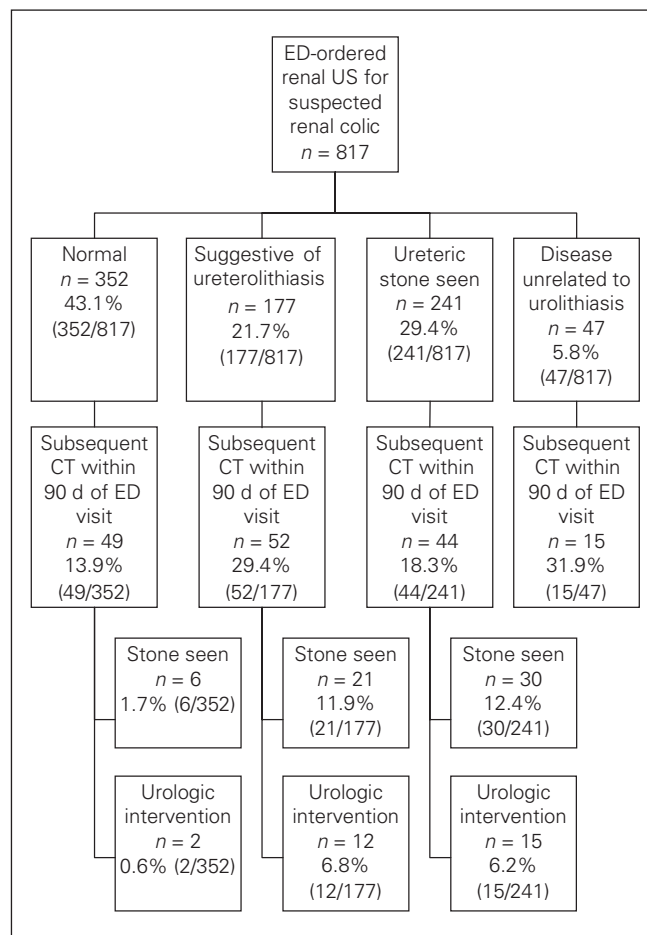


Fig. 1. Flow diagram of 817 renal ultrasonography (US) procedures ordered in the emergency department (ED) for suspected urolithiasis, and the number of patients who underwent subsequent computed tomography (CT) and urologic intervention within 90 days of their initial ED visit.

Table 1. Demographic characteristics of 817 patients who underwent emergency department-ordered renal ultrasonography from Jan. 1 to Dec. 31, 2006, grouped by results

Characteristic	% of patients*				Overall, n = 817
	Normal, n = 352	Suggestive of ureterolithiasis, n = 177	Ureteric stone seen, n = 241	Disease unrelated to urolithiasis, n = 47	
Mean age, yr	42.6	45.3	43.0	48.3	43.6
Male sex	42.9	59.3	67.6	36.2	53.4
Ambulance	4.3	6.2	8.3	10.6	6.2
Admitted	2.3	5.1	1.7	19.1	3.7
No family physician	15.9	17.0	20.8	31.9	18.5
Mean ED LOS, h	5.3	5.4	5.8	6.8	5.6

ED = emergency department; LOS = length of stay.
*Unless otherwise indicated.

and a ureteric stone was visualized in 241 (29.5%). Abnormalities unrelated to urolithiasis were identified in 47 patients (5.8%). Interrater and intrarater reliability values for US result classification were 0.96 and 0.98, respectively, demonstrating excellent agreement.²⁶

Of the 352 patients with normal results on renal US, 49 (13.9%) underwent CT within 90 days of their initial ED presentation, which identified 6 stones that were not seen on US. Only 2 out of 352 patients (0.6%) required a urologic procedure (extracorporeal shock wave lithotripsy).

Of the 177 patients with US findings suggestive of ureterolithiasis, 52 (29.4%) underwent CT within 90 days of their initial ED visit. Of these patients, 21 (11.9%) had stones identified on CT that were not previously found on US, and 12 out of these 177 patients (6.8%) required a urologic procedure within 90 days of their initial ED visit.

Of the 241 patients with ureteric stones visualized with US, 44 (18.3%) underwent subsequent CT within 90 days of their initial ED presentation. Of these 44 patients, 14 did not have a stone seen on CT. Fifteen of the 241 (6.2%) patients with ureteral stones seen on US ultimately required a urologic procedure.

For the 27 patients who had a stone visualized on both US and CT, we compared the stone size measured by each imaging modality (Table 2). Three of these patients had 2 separate stones visualized on both US and CT so that 30 size comparisons were made in total. There was a statistically significant correlation between the stone size reported on US and CT ($r = 0.53$, $p < 0.01$). In 17/30 (56.7%) stones, the size reported on CT and US differed by less than 2 mm. In 19/30 (63.3%) stones, US overestimated the size as compared with CT. In 8/30 (26.7%) stones, US underestimated the size, and in 3/30 (10.0%) stones, the size was exactly the same with US and CT. However, on average, US overestimated the size of the stone by 1.7 (range 0.3–9.0) mm ($p = 0.046$).

Table 2. Reported stone sizes ($n = 30^*$) for patients who underwent renal ultrasonography and computed tomography

Imaging test	Stone size, mm			
	Mean	SD	Mean SE	Range
US	8.23	3.32	0.61	2–15
CT	6.83	4.14	0.76	2–20

CT = computed tomography; SD = standard deviation; SE = standard error; US = ultrasonography.
*Three of the 27 patients had 2 separate stones visualized on both US and CT, resulting in a total of 30 size comparisons.

Of the 47 patients who were found to have diseases unrelated to urolithiasis on US, 15/47 (31.9%) underwent subsequent CT within 90 days of their initial ED visit. The final diagnoses for these 47 patients are presented in Table 3.

DISCUSSION

To our knowledge, this is the largest ED-based renal colic study to date. Our results show that patients who had normal results from ED-ordered renal US for suspected renal colic had a low rate (2/352) of urologic intervention within 90 days. Although most of these patients likely did not have urolithiasis, others may have had undetected small stones that were not visualized and passed without intervention or complication. Conservative management appears to be appropriate in patients with normal results from renal US.

In patients for whom US demonstrated a stone, 44/241 (18.3%) underwent CT and 15/241 (6.2%) required urologic intervention within 90 days of their initial ED visit. The most problematic group were those patients who had US results suggestive of a ureteric stone but with no stone seen. Not surprisingly, this group had the highest rate of CT (52/177, 29.4%). Despite the diagnostic uncertainty of the group with suggestive results on US, the rate of urologic intervention was not different from the group in which a stone was seen (12/177, 6.8% compared with 6.2% for the “suggestive of ureterolithiasis” and “ureteric stone seen” groups, respectively). The optimal approach in this group of patients has yet to be determined. Clinical follow-up or expedited CT may be warranted in this population.

Our results are in agreement with those of previous studies. One relatively small (181 patients) prospective study suggested that although US plus KUB radiography had a lower sensitivity than CT (77% v. 92%),

Table 3. Final diagnoses for 47 patients with abnormal results on ultrasonography unrelated to urolithiasis

Diagnosis	No. (%) of patients
Suspected renal/bladder cancer	12 (25.6)
Ovarian cyst	11 (23.4)
Medical renal disease (hematoma, contusion, end-stage renal disease)	7 (14.9)
Pyelonephritis	7 (14.9)
Cholecystitis or cholelithiasis	3 (6.4)
Crohn disease or diverticulitis	2 (4.2)
Appendicitis	2 (4.2)
Other	3 (6.4)

stones that were missed were generally small and likely to be passed spontaneously.²⁷ The authors concluded that US was a clinically useful diagnostic modality in place of CT where resources were limited. A study by Kobayashi and coauthors,²⁸ which included 238 patients with suspected renal colic with negative or equivocal results on initial US, found that although CT detected stones in 60% of these patients, most stones were small and likely to pass spontaneously. In the same study, the proportion of patients requiring urologic intervention within 1 month was relatively low (6/238, 2.5%), comparable to the overall 90-day intervention rate found in our study.²⁸

A few authors suggest that in patients with a typical presentation and no concerning features, no imaging may be required.² One strategy proposed by Lindqvist and coworkers²⁹ for patients with suspected renal colic is to delay all investigations when the patient's pain is controlled and there are no high-risk features such as fever or solitary kidney. The same study also demonstrated that there was no increased morbidity when renal colic investigations were delayed until 2–3 weeks after initial presentation and reported a lower rate of intervention in patients when imaging was delayed.²⁹ However, one small prospective study suggested that CT provided a significant number of diagnoses that could be missed if imaging was not performed.¹⁴ In the present study, there were 47 (5.8%) patients in whom a diagnosis other than ureterolithiasis was made on initial renal US. No serious missed diagnoses were identified within the 90-day follow-up period of the patients with normal results on US, raising the question as to the imperative of performing urgent CT.

Of the patients who underwent ED-ordered renal US, 160/817 (19.6%) underwent subsequent CT within the 90 days of the initial ED presentation and only 29/817 (3.5%) required urologic intervention. This suggests that suspected renal colic in the majority of patients can be managed without the use of CT, thereby avoiding radiation exposure. The estimated lifetime risk of cancer for a single CT procedure ranges from 1/800 to 1/10 000, depending on the age of the patient and the type of scan performed.^{15,30} Given these findings and the increasing concern about lifetime cumulative radiation exposure attributed to excessive use of CT, it seems prudent for emergency physicians to use alternate imaging modalities whenever practicable to do so.

Limitations

Although this study was a retrospective medical record

review, we feel that the methods were strong, as all study variables were clearly defined a priori and a standardized data collection tool was used by 2 trained abstractors who completed independent, double data extraction for all patient records. We believe this methodologic strategy enhances the validity and reliability of our findings.³¹ Patients were included in this study if they underwent ED-ordered renal US for suspected urolithiasis; however, this criterion would not differentiate between patients presenting with their first episode of flank pain and those with known prior renal colic. Because of the retrospective nature of this study, the only adverse outcomes considered were need for further imaging, need for hospital admission and need for urologic intervention, all of which were defined a priori. We did not capture any additional information on outcomes such as duration of pain, lost time from work or other activities, subsequent visits to the patient's family physician or other health care providers, or need for ongoing analgesia or other treatments apart from urologic intervention.

Our study sample included all patients who underwent ED-ordered renal US for suspected renal colic. Patients who underwent primary CT or those who did not undergo any imaging would not have been captured in our study. It is possible that physicians may have selected primary CT for those thought to be at higher risk of complicated stone disease or other serious pathology, or may have chosen to forgo all imaging for patients presenting with suspected renal colic if they believed they were at low risk of complications. It is unclear how this would affect the overall prevalence of urolithiasis and need for intervention in this retrospective study. However, Dreyer and colleagues³² have previously shown that in our centre US is the preferred imaging modality for patients with suspected renal colic, with about 70% undergoing this form of imaging. During our study period, there were 1085 ED patients with a discharge diagnosis of renal colic, of which 505 (46.5%) had only plain radiography or no imaging. Of the 570 (53.5%) who had ED-ordered imaging, 410 (71.3%) underwent US as the initial imaging test, suggesting that our data include a representative sample of all patients diagnosed with urolithiasis in our region. Although it is possible that some patients received urologic intervention outside of our catchment area, we believe that this is highly unlikely, as our centre is the main referral centre for urolithiasis for southwestern Ontario.

There were some patients (165/1085) with a discharge diagnosis of urolithiasis during the study period who

underwent CT as the initial imaging modality rather than US or no imaging. These patients were significantly older than those who underwent primary US (54.8 v. 43.6, $p < 0.01$), and more arrived to the ED by ambulance (17.5% v. 6.4%).³² This may suggest that the patients who underwent CT as a first diagnostic imaging modality may be different from those in the US group; however, the proportion of patients who were admitted to hospital was not different between the groups.

CONCLUSION

Normal results on renal US predicts a low likelihood for urologic intervention within 90 days for adult ED patients with suspected urolithiasis, suggesting that renal US is a reasonable initial imaging modality in the ED management of suspected renal colic.

Competing interests: None declared.

REFERENCES

- Brown J. Diagnostic and treatment patterns for renal colic in US emergency departments. *Int Urol Nephrol* 2006;38:87-92.
- Tasso SR, Shields CP, Rosenberg CR, et al. Effectiveness of selective use of intravenous pyelography in patients presenting to the emergency department with ureteral colic. *Acad Emerg Med* 1997;4:780-4.
- Chen MYM, Zaporja RJ, Dyer RB. Radiologic findings in acute urinary tract obstruction. *J Emerg Med* 1997;15:339-43.
- Boyd R, Gray AJ. Role of the plain radiograph and urinalysis in acute ureteric colic. *J Accid Emerg Med* 1996;13:390-1.
- Svedström E, Alanene A, Nurmi M. Radiologic diagnosis of renal colic: the role of plain films, excretory urography and sonography. *Eur J Radiol* 1990;11:180-3.
- Worster A, Preyra I, Weaver B, et al. The accuracy of non-contrast helical computed tomography versus intravenous pyelography in the diagnosis of suspected acute urolithiasis: a meta-analysis. *Ann Emerg Med* 2002;40:280-6.
- Eray O, Cubuk MS, Oktay C, et al. The efficacy of urinalysis, plain films, and spiral CT in ED patients with suspected renal colic. *Am J Emerg Med* 2003;21:152-4.
- Greenwell TJ, Woodhams S, Denton ERM, et al. One year's clinical experience with unenhanced spiral computed tomography for the assessment of acute loin pain suggestive of renal colic. *BJU Int* 2000;85:632-6.
- Chen MYM, Zaporja RJ. Can noncontrast helical computed tomography replace intravenous urography for evaluation of patients with acute urinary tract colic? *J Emerg Med* 1999;17:299-303.
- Kenney PJ. CT evaluation of urinary lithiasis. *Radiol Clin North Am* 2003;41:979-99.
- Tamm EP, Silverman PM, Shuman WP. Evaluation of the patient with flank pain and possible ureteral calculus. *Radiology* 2003;228:319-29.
- Gottlieb RH, La TC, Etkurk EN, et al. CT in detecting urinary tract calculi: influence on patient imaging and clinical outcomes. *Radiology* 2002;225:441-9.
- Kirpalani A, Khalili K, Lee S, et al. Renal colic: comparison of use and outcomes of unenhanced helical CT for emergency investigation in 1998 and 2002. *Radiology* 2005;236:554-8.
- Ha M, MacDonald RD. Impact of CT scan in patients with first episode of suspected nephrolithiasis. *J Emerg Med* 2004;27:225-31.
- Brenner DJ, Hall EJ. Computed tomography — an increasing source of radiation exposure. *N Engl J Med* 2007;357:2277-84.
- Mettler FA, Wiest PW, Locken JA, et al. CT scanning: patterns of use and dose. *J Radiol Prot* 2000;20:353-9.
- Broder J, Bowen J, Lohr J, et al. Cumulative CT exposures in emergency department patients evaluated for suspected renal colic. *J Emerg Med* 2007;33:161-8.
- Lee CI, Haims AH, Monico EP, et al. Diagnostic CT scans: assessment of patient, physician, and radiologist awareness of radiation dose and possible risks. *Radiology* 2004;231:393-8.
- Geavlete P, Georgescu D, Cauni V, et al. Value of duplex Doppler ultrasonography in renal colic. *Eur Urol* 2002;41:71-8.
- Teichman JM. Acute renal colic from ureteral calculus. *N Engl J Med* 2004;350:684-93.
- Ripolles T, Agramunt M, Errando J, et al. Suspected ureteral colic: plain film and sonography vs unenhanced helical CT. A prospective study in 66 patients. *Eur Radiol* 2004;14:129-36.
- Watkins S, Bowra J, Sharma P, et al. Validation of emergency physician ultrasound in diagnosing hydronephrosis in ureteric colic. *Emerg Med Australas* 2007;19:188-95.
- Rosen CL, Brown DFM, Sagarin MJ, et al. Ultrasonography by emergency physicians in patients with suspected ureteral colic. *J Emerg Med* 1998;16:865-70.
- Patlas M, Farkas A, Fisher D, et al. Ultrasound vs CT for the detection of ureteric stones in patients with renal colic. *Br J Radiol* 2001;74:901-4.
- Noble VE, Brown DFM. Renal ultrasound. *Emerg Med Clin North Am* 2004;22:641-59.
- Stiell IG, McKnight RD, Greenberg GH, et al. Interobserver agreement in the examination of acute ankle injury patients. *Am J Emerg Med* 1992;10:14-7.
- Catalano O, Nanzati A, Altei F, et al. Suspected ureteral colic: primary helical CT versus selective helical CT after unenhanced radiography and sonography. *AJR Am J Roentgenol* 2002;178:379-87.
- Kobayashi T, Nishizawa K, Watanabe J, et al. Clinical characteristics of ureteral calculi detected by nonenhanced computerized tomography after unclear results of plain radiography and ultrasonography. *J Urol* 2003;170:799-802.
- Lindqvist K, Hellstrom M, Holmberg G, et al. Immediate versus deferred radiological investigation after acute renal colic: a prospective randomized study. *Scand J Urol Nephrol* 2006;40:119-24.
- Katz SI, Saluja S, Brink JA, et al. Radiation dose associated with unenhanced CT for suspected renal colic: impact of repetitive studies. *AJRA Am J Roentgenol* 2006;186:1120-4.
- Gilbert EH, Lowenstein S, Koziol-McLain J, et al. Chart reviews in emergency medicine research: What are the methods? *Ann Emerg Med* 1996;27:305-8.
- Dreyer JF, Edmonds ML, McLeod SL. Diagnostic imaging for renal colic in Ontario emergency departments [abstract 196]. *CJEM* 2007;9:220.

Correspondence to: Dr. Marcia Edmonds, 800 Commissioners Rd. E1-102, London ON N6A 5W9; fax 519 667-6769; marcia.edmonds@lhsc.on.ca