

1970

A Light And Electron Microscopic Study Of Eye Development Of The Rat

Charles Roger Braekevelt

Follow this and additional works at: <https://ir.lib.uwo.ca/digitizedtheses>

Recommended Citation

Braekevelt, Charles Roger, "A Light And Electron Microscopic Study Of Eye Development Of The Rat" (1970). *Digitized Theses*. 392. <https://ir.lib.uwo.ca/digitizedtheses/392>

This Dissertation is brought to you for free and open access by the Digitized Special Collections at Scholarship@Western. It has been accepted for inclusion in Digitized Theses by an authorized administrator of Scholarship@Western. For more information, please contact tadam@uwo.ca, wlsadmin@uwo.ca.

The author of this thesis has granted The University of Western Ontario a non-exclusive license to reproduce and distribute copies of this thesis to users of Western Libraries. Copyright remains with the author.

Electronic theses and dissertations available in The University of Western Ontario's institutional repository (Scholarship@Western) are solely for the purpose of private study and research. They may not be copied or reproduced, except as permitted by copyright laws, without written authority of the copyright owner. Any commercial use or publication is strictly prohibited.

The original copyright license attesting to these terms and signed by the author of this thesis may be found in the original print version of the thesis, held by Western Libraries.

The thesis approval page signed by the examining committee may also be found in the original print version of the thesis held in Western Libraries.

Please contact Western Libraries for further information:

E-mail: libadmin@uwo.ca

Telephone: (519) 661-2111 Ext. 84796

Web site: <http://www.lib.uwo.ca/>



**NATIONAL LIBRARY
OF CANADA**

**CANADIAN THESES
ON MICROFILM**

**BIBLIOTHÈQUE
NATIONALE
DU CANADA**

**THÈSES CANADIENNES
SUR MICROFILM**

No— 6 | 3 | 3 | 8

A LIGHT AND ELECTRON MICROSCOPIC STUDY OF FEATURES
OF EYE DEVELOPMENT OF THE RAT

by

Charlie Roger Braekevelt

Department of Anatomy

Submitted in partial fulfillment
of the requirements for the degree of
Doctor of Philosophy

Faculty of Graduate Studies
The University of Western Ontario

London, Canada.

September, 1969

The work described in this thesis was supported by grants from the Medical Research Council of Canada, the A.E. Baker Foundation for the Prevention of Blindness and Fight for Sight Incorporated. The author wishes to express his appreciation to these organizations for this assistance.

ACKNOWLEDGEMENTS

The assistance of many persons has gone into the present investigation and the author wishes to express his thanks for their time and effort.

Appreciation is extended to Mrs. G. Jones, Mr. P. Gurney, Miss J. Butler and Mr. H. Dickson for technical assistance.

Dr. R.C. Buck kindly provided facilities within the department and offered helpful advice during the work.

Dr. R. Misra and Dr. D. Borwein have helped greatly with mathematical and statistical analysis.

Appreciation is also extended to the Ontario government for Province of Ontario Graduate Fellowships and to the estate of Nellie L. Farthing for the Nellie L. Farthing Memorial Fellowships.

Finally the writer is most deeply indebted to Dr. M.J. Hollenberg for his assistance and unfailing encouragement without which this work would not have been possible.

CONTENTS

	Page
Acknowledgements	iv
List of Tables	vii
List of Text-Figures	viii
List of Figures	ix
Abstract	xiv
I Introduction	1
II Historical Review	5
1. Light Microscopy	5
2. Electron Microscopy	13
III Materials and Methods	21
1. Light Microscopy	21
2. Electron Microscopy	24
IV Observations	27
1. Development of the retina of the albino rat..	27
2. Development of the retinal pigment epithelium, choriocapillaris and Bruch's membrane	49

	Page
3. A comparative study of the develop- ment of the hyaloid and retinal capillaries	62
i) Hyaloid capillaries	62
ii) Retinal capillaries	71
V Discussion	77
1. Development of the retina in the albino rat	77
2. Development of the pigment epithelium, choriocapillaris and Bruch's membrane .	81
3. Development of the hyaloid and retinal capillaries	87
VI Summary	91
Appendix	94
Bibliography	95
Vita	114

List of Tables

Table	Page
1 The relationship between age, development of the retinal layers and retinal volume in the albino rat eye.....	45

List of Text-Figures

Text-Figure	Page
1 Graph showing the changes, during development, in thickness of the retinal layers at the posterior of the retina	46
2 Graph showing the changes, during development, in thickness of the retinal layers at the periphery of the retina.....	47
3 Graph showing the changes, during development, in total thickness of the retina and total retinal volume.....	48

List of Figures

Figure		Page
1	Light micrograph of the optic vesicles on the 11th day of gestation	28
2	Light micrograph of an optic vesicle and lens disc on the 12th day of gestation	28
3	Light micrograph of the optic cup and invaginating lens on the 13th day of gestation	29
4	Light micrograph of the whole eye on the 14th day of gestation	29
5	Light micrograph of the posterior pole of the eye on the 15th day of gestation	31
6	Light micrograph of the posterior pole of the eye on the 17th day of gestation	31
7	Light micrograph of the posterior of the retina on the 18th day of gestation	33
8	Light micrograph of the posterior of the retina on the 20th day of gestation	33
9	Light micrograph of the posterior of the retina on the 21st day of gestation	35
10	Light micrograph of the posterior of the retina on the 4th postnatal day	35

Figure		Page
11	Light micrograph of the posterior of the retina on the 5th postnatal day	37
12	Light micrograph of the periphery of the retina on the 5th postnatal day	37
13	Light micrograph of the posterior of the retina on the 7th postnatal day	39
14	Light micrograph of the periphery of the retina on the 7th postnatal day	39
15	Light micrograph of the posterior of the retina on the 9th postnatal day	40
16	Light micrograph of the periphery of the retina on the 9th postnatal day	40
17	Light micrograph of the posterior of the retina on the 14th postnatal day	42
18	Light micrograph of the posterior of the retina on the 50th postnatal day	42
19	Light micrograph of the posterior of the retina on the 225th postnatal day	43
20	Light micrograph of the periphery of the retina on the 225th postnatal day	43
21	Electron micrograph of the pigment epithelial layer on the 15th day of gestation	50
22	Electron micrograph of pigment epithelial cells on the 16th day of gestation	50

Figure	Page
23 Electron micrograph of pigment epithelial cells and future photoreceptors on the 16th day of gestation	52
24 Electron micrograph of the choriocapillaris on the 17th day of gestation	52
25 Electron micrograph of the pigment epithelium - photoreceptor junction on the 18th day of gestation	54
26 Electron micrograph of the pigment epithelium - photoreceptor junction on the 20th day of gestation	54
27 Electron micrograph of the pigment epithelium on the 21st day of gestation	56
28 Electron micrograph of the pigment epithelium, Bruch's membrane and choriocapillaris on the 21st day of gestation	56
29 Electron micrograph of the pigment epithelium on the 5th postnatal day	59
30 Electron micrograph of pro-pigment granules within the pigment epithelium on the 5th postnatal day	59
31 Electron micrograph of the pigment epithelium - photoreceptor junction on the 8th postnatal day	61

Figure	Page
32 Electron micrograph of the pigment epithelium, Bruch's membrane and choriocapillaris on the 9th postnatal day	61
33 Electron micrograph showing a lamellated body within the pigment epithelium on the 14th postnatal day	63
34 Electron micrograph of the pigment epithelium - photoreceptor junction on the 14th postnatal day....	63
35 Electron micrograph of a hyaloid capillary in the vitreous of the eye on the 16th day of gestation....	64
36 Electron micrograph of a hyaloid capillary on the lens capsule on the 16th day of gestation	64
37 Electron micrograph of hyaloid capillaries near the retina on the 19th day of gestation	66
38 Electron micrograph of a hyaloid capillary on the lens capsule on the 21st day of gestation	66
39 Electron micrograph of a retinal and a hyaloid capillary on the 21st day of gestation	67
40 Electron micrograph of a hyaloid capillary within the vitreous on the 3rd postnatal day	67
41 Electron micrograph of a hyaloid capillary wall on the 3rd postnatal day	69
42 Electron micrograph of the wall of a hyaloid capillary on the 3rd postnatal day	69

Figure	Page
43 Electron micrograph of the wall of a hyaloid capillary on the 4th postnatal day	70
44 Electron micrograph of a hyaloid capillary wall on the 4th postnatal day	70
45 Electron micrograph of the wall of a hyaloid capillary on the 16th postnatal day	72
46 Electron micrograph of a retinal capillary on the 1st postnatal day	72
47 Electron micrograph of a retinal capillary on the 10th postnatal day	74
48 Electron micrograph of a dividing endothelial cell of a retinal capillary on the 10th postnatal day	74
49 Electron micrograph of a retinal capillary on the 14th postnatal day	75
50 Electron micrograph of a retinal capillary on the 14th postnatal day	75

ABSTRACT

The morphogenesis of the retina of the Sprague-Dawley albino rat has been studied by light microscopy from the 11th day of gestation until 225 days after birth. A quantitative analysis of the changes during development in retinal volume, thickness of the entire neural retina and thickness of each of the retinal layers, both posteriorly and peripherally, has been made. The results indicate that initially activity is centered on the formation of a single neuroblastic layer, continually thickened by mitosis at its outer border. The retinal layers then form in sequence, moving from the inner retinal border outward and always beginning posteriorly and then spreading peripherally. The transient layer of Chievitz does not appear. All the adult layers are present by 8 days after birth and each layer thins after it has reached its maximal thickness. Total thickness of the neural retina is greatest on the 5th postnatal day, but retinal volume does not reach a peak until the 7th to the 12th postnatal days.

The development of the retinal pigment epithelium, choriocapillaris, Bruch's membrane, hyaloid and early retinal capillaries has been studied by electron microscopy during the last fetal week and the first two weeks of neonatal life. During this period, the pigment epithelial cell changes from an undifferentiated,

to a highly specialized state, both morphologically and functionally. The apical cytoplasm forms long thin projections that enclose first, the developing photoreceptor inner segments, and later the receptor outer segments. The basal region of the epithelium becomes highly infolded in isolated areas, which later coalesce to cover the entire basal surface. The pigment granules in the albino rat develop normally in the inner epithelial cytoplasm until the stage of melanin deposition, after which they begin to break down. The lamellated inclusion body of the adult pigment epithelium first appears during the second week of postnatal life.

The five layers composing Bruch's membrane are formed in the following order: the basement membrane of the pigment epithelium; the two collagenous layers; the basement membrane of the choriocapillary endothelium on the last prenatal day; and finally, the central lamina densa after birth. The wall of the choriocapillaris changes from a continuous endothelium on the 6th prenatal day, to a thin fenestrated endothelial wall facing the pigment epithelial layer by the 5th neonatal day.

Despite differences in the developmental pattern of the hyaloid and retinal capillary systems and the temporary nature of the mammalian hyaloid vessels, the two capillary systems are basically similar in ultrastructural appearance. Both varieties of capillary possess a continuous endothelium, a multilayered basement membrane and an incomplete pericyte covering. In both types, the endothelium and pericyte covering become thinner as the capillary matures. The hyaloid pericytes, alone possess an

inner cytoplasmic band of fibrillar material and the hyaloid basement membrane never achieves the thickness of its retinal counterpart. An outer glial covering, limited to the retinal capillaries is the last layer of these vessels to be fully developed.

I INTRODUCTION

The following work has been divided into three sections as follows:

- 1) A light microscopic study of the development of the retina.
- 2) An electron microscopic study of the development of the retinal pigment epithelium, choriocapillaris and Bruch's membrane.
- 3) A comparative electron microscopic study of the development of the hyaloid and retinal capillaries.

1. The principal features of development of the mammalian retina have been described in man (Barber, 1955; Duke-Elder, 1963; Mann, 1964) and in a number of laboratory animals (Mann, 1928; Tansley, 1951; Parry, 1953; Noell, 1958; Donovan, 1966) including the rat (Detwiler, 1932; Tansley, 1933; Bourne, Campbell and Tansley, 1938; Paik and Chung, 1966). Particular attention has been paid to the relationship between the structural changes underlying retinal development and functional maturity monitored by electro-retinography (Parry, 1953; Hellström and Zeterström, 1956; Noell, 1958; Horsten and Winkelman, 1960).

Despite the fact that many investigations of retinal development have been published, a comprehensive, sequential analysis of development of the retinal layers in mammals is not available; nor has a detailed description of the morphogenesis of the rat retina

been published. The present investigation explores, quantitatively, the successive development of the intrinsic retinal layers in the rat, from the 11th day of gestation until 225 days after birth. The morphology of the developing rat retina has been studied and a timetable indicating the first appearance and relative changes in thickness of each of the retinal layers has been prepared. The times of development in this strain of rat have been correlated with the standard developmental stages of Christie (1964). It is anticipated that the results will provide necessary background information for future studies of retinal ultrastructure, experimental embryology and teratogenesis.

2. The retinal pigment epithelium, choriocapillaris and Bruch's membrane, in the adult mammal, comprise a highly differentiated and functionally integrated structure charged with several specialized roles indispensable to the visual process. In addition to the absorption of light, these include essential functions related to the storage of Vitamin A ester and the regeneration of visual pigment (Dowling, 1960), the metabolic support of the entire outer retina (Michaelson, 1954; Bernstein, 1961; Bernstein and Hollenberg, 1965b) and the architectural stabilization of the outer portions of the photoreceptor cells (Bernstein, 1961).

A great deal has been learned in recent years concerning the fine structure and function of the mammalian pigment epithelium, Bruch's membrane, and the choriocapillaris in the adult animal (Bernstein, 1960, 1961; Sumita, 1961; Dowling and Gibbons, 1962;

Garron, 1963; Bairati and Orzalesi, 1963; Nakaizumi, 1964; Lasansky and de Fisch, 1965; Leeson and Leeson, 1966, 1967; Nakao, 1968; Leure-du Pree, 1968). In contrast, the detailed morphologic and functional changes accompanying the development of these structures are not well known and have been the subject of only a few publications (Dowling and Gibbons, 1962; Breathnach and Wyllie, 1966; Leeson, 1968; Weidman and Kuwabara, 1968).

The present study closely examines the ontogenic relationship between the retinal pigment epithelium and the adjacent photoreceptor cells. Particular attention was paid to the developmental process at the epithelial photoreceptor junction. In addition, the study explores the time, the sequence and the mode of acquisition of the highly specialized morphological characteristics of the retinal epithelium and its adjacent structures. An albino animal was chosen to examine further the block to melanin granule formation in the retinal epithelium of the albino and the subsequent fate of the non-melanized, pro-pigment granules.

3. It is well known that during the early development of the eye in mammals, the hyaloid and retinal vascular systems have separate roles to play. The two systems, although both derived from mesodermal tissue at the site of the optic stalk, appear at different times, exhibit distinctive directions and patterns of growth and for the most part nourish different intraocular structures (Michaelson, 1954; Mutlu and Leopold, 1964a, b).

The present study seeks to determine whether or not the developmental distinctions between the two systems are reflected

in related morphological differences. The results indicate that despite the foregoing differences and the temporary nature of mammalian hyaloid vessels, the two capillary systems resemble one another in ultrastructural appearance, although each possesses certain structural characteristics of its own.

II HISTORICAL REVIEW

I LIGHT MICROSCOPY

1) A Brief Review of the Most Notable Studies of the Structure of the Adult Retina.

The earliest microscopic investigations of the retina coincide with the beginnings of microscopy itself, for the retina was one of the numerous tissues studied by van Leeuwenhoek. On at least two occasions in 1674 and again in 1684, van Leeuwenhoek wrote letters to the Royal Society of London describing "globular bodies" he had seen within the retina of the frog (Polyak, 1941). His observations were for the most part only cursory studies on the fresh retina, but the year before his death, in 1723, he described the rods and cones of the retina of the frog (Duke-Elder, 1961). In the early 19th century, both Fontana and Ehrenberg (Polyak, 1941) studied retinal structure as a means of gaining a better understanding of the cerebral cortex. In the view of Ehrenberg, the retina, like the brain was composed of very fine fibres, continuous with the fibres of the optic nerve (the cortical substance) and a whitish layer (the medullary substance). Jacob (1819) floated the retina under a glass sphere in water and described the "bacillary layer" as an extremely tenuous but separate membrane.

The first person to make a concerted effort to unravel the complex architecture of the retina was Treviranus (Duke-Elder, 1961). He fixed the retina in alcohol and using this technique produced diagrams of the cross-sectional appearance of the retina. His observations, however, contained a number of errors. He erroneously positioned the nerve fibre layer on the scleral (or outer) aspect of the retina. Papillae, probably ganglion cells which he found towards the vitreal or inner surface of the retina were assumed to be the photoreceptors. Treviranus' work was improved upon by a number of investigators in the next few years. Valentin (1837) was the first to correctly recognize the position of the bacillary layer at the outer edge of the retina. Gottsche (1836) established the inner location of the optic fibre layer which Ehrenberg had shown led to the brain. Hannover (1840) introduced the technique of hardening tissues with chromic acid and this method was quickly adopted by a number of workers. Corti (1850) showed that the processes of the ganglion cells joined with the layer of optic nerve fibres. This observation put an end to speculation that the photoreceptive layer was located at the inner edge of the retina. Huschke (1835) had speculated that the bacillary layer was the actual photoreceptive area of the retina and Müller (1853) proved this by means of a physiological observation; the parallax or displacement of entoptically perceived shadows of retinal blood vessels. With the help of histological data, Müller placed the locus of photoreception in the bacillary layer. Müller's description of the retina was confirmed by Kölliker (1854), in that he arrived at the same conclusions.

Müller (1853) described "radial fibres" within the retina which he initially considered to be the optic nerve fibres passing through the entire width of the retina to become the rods and cones. Soon after Müller's discovery of the "radial fibres" however it was observed by Remak (1854) that they did not merge with the ganglion cells. It was subsequently revealed (Müller, 1856; Schultze, 1866) that side by side with the "radial fibres" which were now considered by Müller to be supportive elements were thinner fibres with all the characteristics of nerve fibres. Schultze (1872) made another important contribution during this era when he elucidated the structure and function of the rods and cones and introduced the duplicity theory of vision which propounded that the rod photoreceptors were for vision in dim light and the cones were for colour and bright light vision. The concept of the retina as outlined by Müller and Kölliker which stated that the optic nerve fibres pass through the width of the entire retina to become the photoreceptor cells, remained essentially unchanged for 30 years. (Nunneley, 1858; Ritter, 1864).

The next great advance in the knowledge of retinal architecture came with the introduction of two new techniques whereby individual neurons in nervous tissue cell could be delineated. These were the silver stains of Golgi (1873) and the methylene blue stain of Ehrlich (1885). Using these techniques as well as his own, and devoting his life to the study, Cajal (1892) showed that nerve impulses were transmitted to the optic nerve fibres by a discontinuous chain composed of synaptically related links, represented by distinct nerve fibres or "neurons". He also showed that the earlier

concept of the retina as a neuro-syncytium in which the nerve fibres were fused was based on inadequate staining and was no longer tenable. Cajal established that the retina, like the whole of the nervous system of higher animals, is made up of a series of independent neurons which normally conduct impulses in only one direction and establish synaptic connections between their axons and dendrites.

After Cajal's classical work, further study of the retina served mainly to corroborate Cajal's findings (Laurens and Detwiler, 1921; Detwiler, 1932; Walls, 1942 etc). The work of Polyak (1941 and 1957) however, stands out as the most monumental contribution to the understanding of retinal structure in modern times. Polyak devoted his life to an attempt to accurately describe the primate and human retina. The 10 layers of the vertebrate retina proper as described by Polyak (1941) are from without inwards, 1) the pigment epithelium 2) the bacillary layer (outer and inner segments of photoreceptive cells) 3) the outer limiting membrane 4) the outer nuclear layer (the nuclei of the rods and cones) 5) the outer plexiform layer (a synaptic layer between the rods and cones and the bipolar cells) 6) the inner nuclear layer (the nuclei of the bipolar cells, Müller cells and other integrative neurons) 7) the inner plexiform layer (a layer of synapses between the cells of the inner nuclear layer and the ganglion cells) 8) the ganglion cell layer 9) the nerve fibre layer 10) the inner limiting membrane.

The pigment epithelium, together with the membrane of Bruch (1844) on which it lies was considered by the old anatomists

such as Ruysch (Duke-Elder, 1961) to be part of the choroid. The morphology of the pigment epithelium was first described by Jones (1833). The physiological significance of the relation of the pigment epithelium to the receptors was first noted by Kuhne (1879), who found that in vitro regeneration of the visual pigment took place only if the pigment epithelium and receptors remained in contact. The pigment epithelium is a single layer of cells in mammals, each containing a round or oval nucleus and a large quantity of pigment (called fuscine by Kuhne, 1879). The inner surface of the pigment epithelial cells have long processes which dip down between the ends of the rods and cones (Kuhne, 1879) but make no direct contact with them (Iwaki, 1958). Recent biochemical studies suggest that the epithelial pigment is produced by the enzymatic oxidation of tyrosine to melanin, a reaction catalysed by tyrosinase. (Miyamoto, and Fitzpatrick, 1957; Mishima and Loud, 1963). The pigment epithelium is important to the process of vision for a number of reasons, perhaps the most obvious being the absorption of random light and hence an increase in resolution.

2) A Brief Review of the Studies on Retinal Development.

The first investigations of retinal development were carried out on lower vertebrates (Huschke, 1832, Remak, 1854). These studies led researchers to believe that the photoreceptors arose from the external layer of the optic cup, that is the uninverted portion of the optic cup. Kölliker (1861), however, was the first

to show that the pigment epithelium alone arose from this outer layer. Babuchin (1863) then demonstrated that in the embryo of the frog, chicken and rabbit, the photoreceptive structures arose from the inner or inverted layer of the optic cup. Ritter (1864) confirmed these findings and made a general study of the development of the various layers of the retina. These studies were elaborated on by various workers, among them Chievitz (1887), Rochon-Duvigneaud (1895), Cameron (1905, a,b,c, and 1911), Magitot (1910), Weyse and Burgess (1906), Seefelder (1910), Mann (1928), Detwiler (1932), Coulombre (1955), and O'Rahilly and Meyer (1959). The combined work of these investigators has shown that the formation of the definitive layers of the retina takes place from within outwards, thus the nerve fibre and ganglion cells layers are the first to differentiate and the photoreceptors the last to develop. Layering begins at the posterior pole of the retina and then spreads peripherally. The main concepts of the morphogenesis of the human eye have been principally coordinated and shaped by Mann (1964) and her interpretation, with minor modifications in some species, is the scheme recognized today. According to Mann (1964), during the development of the human eye, the primary optic vesicle forms as an outpouching of the diencephalon of the brain. This later invaginates upon itself to form an inner (inverted) and outer (uninverted) layer of the wall of the optic cup. The outer layer will form only a single layer of cells, the pigment epithelium, while the inner layer will greatly thicken by mitotic activity at its outer edge and form all the other layers of the retina. The

lens and cornea develop as secondary ingrowths of the superficial ectoderm. The choroid and sclera arise from a concentration of mesenchymal cells about the optic cup. The vascular system of the eye forms from an ingrowth of mesodermal tissue at the site of the optic stalk by a process of budding and the intraocular vascularization forms according to Mann (1964) from pre-existing vessels.

The studies on the development and architecture of the blood supply of the eye date back to early histological work. As early as about 1700, Ruysch (Duke-Elder, 1961) introduced a technique for the injection of blood vessels and determined the main outlines of ocular circulation in the human. Injection techniques were subsequently developed further and numerous substances used as injection media. In the hands of numerous workers, among them Kiss (1942) and Ashton (1951) these techniques have become extremely sophisticated. Kuwabara and Cogan (1960) introduced a trypsin digestion technique which digests the neuroglia and leaves behind only the vascular network. This method has provided further information on the morphology of the blood vessels of the eye. Various other histological techniques such as better fixation and serial sectioning have led to a fairly complete picture of the vascularization of the vertebrate eye at the light microscopic level.

The blood system of the choroid was shown to be the first to become organized and can be seen as a disorganized plexus bordering the optic vesicle as early as the 5 mm. stage in the human (Barber, 1955; Mann, 1964) and the 15th day of gestation in the rat (Berson, 1965).

Duke-Elder (1961) has divided the development of the uveal vascular system into 3 stages, 1) the early formation of a plexus of small vascular channels immediately adjacent to the optic vesicle and then the optic cup (the future choriocapillaris) 2) the formation of venous channels more externally and 3) the final insinuation of arterial elements between the capillary and venous layers. By 5 months the choroidal vasculature of the human is complete.

The formation and subsequent disintegration of the hyaloid system including the tunica vasculosa lentis was especially intriguing to early eye investigators. Henle (1832) and Arnold (1832) noted the complex vascular formations surrounding the fetal lens and the origin of these vessels from a central artery running through the vitreous. Further studies by Fuchs (1905), Seefelder (1909), Bach and Seefelder (1914), Agrawal, Agarwal and Tandon (1964), and Mutlu and Leopold (1964b) clarified the anatomy of these fetal intra-ocular vessels in the human and trace them from their inception to disintegration. According to Mann (1964) the disintegration of the hyaloid system is due mainly to the fact that they come to lag behind the developing eye and become stretched and eventually break. The smaller vessels in the vitreous are the first to be stretched and broken by the growing pressures, with the main trunk being the last to atrophy.

The retinal circulation in the rat was initially investigated by Hesse (1880) and Bruns (1882). They showed the presence of both a deep and a superficial capillary net lying at the level

of the inner nuclear layer and the nerve fibre layer respectively. The two layers of capillaries were joined. The retinal capillaries formed as the hyaloid system was breaking down. Michaelson (1948a, b, 1954) described the development of the superficial net of retinal capillaries in the cat and various other animals, by a process of budding into the nerve fibre layer from pre-existing vessels. Cairns (1959) subsequently showed that the deep capillary net (located around the inner nuclear layer) formed by a process of budding from the superficial net. Various other works on the development of the retinal vasculature tend to support the same idea (Cogan, 1963; Engerman and Meyer, 1965; Henkind and de Oliveira, 1967) that the intra-ocular vascularization is formed entirely from a mesodermal ingrowth.

The monumental works of Polyak (1941, 1957) ably summarize and catalogue the findings of light microscopy of the eye as far as they can logically be expected to carry us. Questions concerning the cellular structure of the photoreceptor cells, the morphology of the retinal synapses and the component parts of the various membranes of the eye could only be answered by the increased resolution provided by the electron microscope.

II ELECTRON MICROSCOPY

1) A Brief Review of the Fine Structure of the Adult Vertebrate Retina.

Research at the level of resolution of the electron microscope has stressed even more the similarity in cytological structure of the retina to other parts of the central nervous system.

As an example, the margins of all cells lining the lumen of the neural tube possess terminal bars (Sauer, 1937; Cohen, 1961). The same is true of all cells lining the cavity of the optic ventricle (Cohen, 1960, 1961; Fine, 1961).

Sjöstrand (1953a, b) was the first to publish an electron microscopic description of the fine structure of the photoreceptor cells of the guinea pig and the perch. His description and those of several other authors (Cohen, 1960; Yamada, 1960; Lasansky and De Robertis, 1960; Moody and Robertson, 1960; Nilsson, 1964; Morris and Shorey, 1967 etc.) have shown a remarkable similarity amongst vertebrate photoreceptor cells. The visual receptors are elongate cells whose scleral halves extend beyond the external limiting membrane, towards and into the pigment epithelium. Two distinct regions of this extended portion, the outer and inner segment are separated by a narrow neck. At and below the external limiting membrane lie the cell nuclei and below the nuclei, cell processes which lead to the synaptic bases of the receptor cells. The outer segment of the photoreceptor cell lies in close association with the inner apical processes of the pigment epithelial cells and is composed of a stack of double membrane discs. In the rod, these membranes are for the most part enclosed by a cell membrane, but in the cone the majority of the membranous discs are continuous with the plasma membrane (Cohen, 1963). The outer segment is almost invariably connected to the inner segment by a typical cilium (Sjöstrand, 1953a; De Robertis, 1956b, Yamada, Tokuyasu and Iwaki, 1958b; Missotten, 1960) however Pedler and Tansley (1963) have found

the connecting cilium to be almost non-existent in the gecko. Yamada et al (1958b) have reported some abnormal photoreceptor cells in man and mouse which also show no connecting cilium. The inner segment of the photoreceptor cell typically contains a concentration of mitochondria at its distal end (Yamada, 1957, 1960; Cohen, 1960, 1963; Dartnall and Tansley, 1963) and a Golgi zone in its proximal part (Cohen, 1960). Some non-mammalian cone inner segments also exhibit an oil droplet at its distal end (Pedler and Tansley, 1963; Meyer and Cooper, 1966). The visual cell body is usually connected to the inner segment by means of a fibre resembling a non-myelinated nerve fibre, while a similar fibre often connects it to the synapse (De Robertis and Franchi, 1956).

An analysis of the fine structure of the synaptic endings of the retinal photoreceptors (De Robertis and Franchi, 1956; Ladman, 1958; Sjöstrand, 1958, 1961; Dowling and Boycott, 1966) has revealed the characteristics of synaptic vesicles and in addition "synaptic ribbons". The function of the latter remains obscure. The rod synapse usually receives dendrites from a single bipolar or horizontal cell and in some cases, at least, is also associated with processes from other rods and cones (Ladman, 1958; Cohen, 1963; Hollenberg and Bernstein, 1966). The cone synaptic pedicle is more complex than that of the rod and it receives several bipolar and horizontal cell dendrites and also makes contact with other visual cells (De Robertis and Franchi, 1956; Yamada et al 1958b; Cohen, 1960; Dowling and Boycott, 1966; Hollenberg and Bernstein, 1966).

One of the main structural differences between rods and cones appears to be in the relative diameters of the inner and outer segments. In the rod they are about equal. In the cones, the inner segment is much thicker than the outer segment. (Dartnall and Tansley, 1963). Other differences include the greater complexity of the cone synaptic pedicle and the fact that more of the membranous discs of the outer segment of the cone are continuous with the plasma membrane than in the rod (Cohen, 1963; Dartnall and Tansley, 1963).

The fine structure of the adult pigment epithelium has also been well described (Bernstein, 1961, 1966; Dowling and Gibbons, 1962; Garron, 1963; Bairati and Orzalesi, 1963; Breathnach and Wyllie, 1966; Leure-du Pree, 1968; Leeson, 1968). These workers have shown that the mature pigment epithelium is a highly specialized layer involved in the transport of metabolites from the choriocapillaris to the receptor cells. The basal surface is highly infolded and mitochondria are located basally to facilitate transport of metabolites to the photoreceptors. The apical surface of the epithelial cells have numerous processes which contain pigment granules and which surround the photoreceptor outer segments.

The other nuclear and synaptic layers of the retina have not been as extensively studied by electron microscopy but some of their fine structural characteristics have been noted. In the human, the four types of cells whose nuclei comprise the inner nuclear layer (bipolar, amacrine, horizontal and Müller cells) can be differentiated by various ultrastructural characteristics

Missotten, 1965). The rod bipolar can be identified in the human by helical tubules adjacent to the cell membrane (Missotten, 1965). The horizontal cells in the periphery of the human retina contains groups of tubular organelles (Missotten, 1965). The plasma membrane of the Müller cells is much less dense than that of a neuron (Missotten, 1965). The fine structure of the Müller cell has in fact been studied by a number of workers (Sjöstrand, 1960; Ladman, 1961; Okuda, 1965; Inomata, 1965; Meller and Glees, 1965; Radnot and Lovas, 1968). It appears to be a glial cell and probably is without neuronal function. The inner plexiform layer appears in electron micrographs as a series of intertwined processes of nerve cells forming the synapses between the cells of the inner and outer nuclear layers (Missotten, 1960; 1965; Kidd, 1962; Dowling and Boycott, 1965; Radnot and Lovas, 1967; Raviola and Raviola, 1967), plus numerous glial processes. The ganglion cell nuclei are easily recognizable with their typical Nissl bodies (Fine, 1963). Typical non-myelinated, fibres form the nerve fibre layer.

The structure of the four membranes of the eye originally described by light microscopy has also been elucidated by electron microscopy. Bruch's membrane located between the choriocapillaris and the pigment epithelium has been shown to be composed of 5 layers; the basement membrane of the pigment epithelium, the basement membrane of the choriocapillaris, an inner and an outer collagen layer separated by a central discontinuous lamina densa (Sumita, 1961; Nakaizumi, 1964; Hollenberg and Burt, 1969). Verhoeff's membrane (Verhoeff, 1903) which runs through the pigment epithelium is composed

of a series of terminal bars joining the lateral aspects of the pigment epithelial cells (Fine, 1961). The external limiting membrane of the retina is also composed of a series of terminal bars joining the inner segments of the photoreceptor cells to adjacent Müller cells (Fine, 1961). The inner limiting membrane of the retina is however considered to be a true membrane as it is composed of the plasma membranes of the flattened ends of the Müller cells and a typical basement membrane located immediately adjacent and internal to the Müller cells (Fine, 1961).

Study of the fine structure of the capillaries of the eye has revealed differences in the morphology of the choriocapillaris, retinal capillaries and the temporary mammalian hyaloid capillaries. The choriocapillaris has a very thin wall bordering Bruch's membrane (Sumita, 1963; Missotten, 1965) and a thicker wall on the choroidal side (Bernstein, 1961; Leeson and Leeson, 1967) tending to facilitate transport towards the pigment epithelium. The endothelial cells also have numerous fenestrae covered by a thin membrane on the side bordering Bruch's membrane (Bernstein and Hollenberg, 1965b). A continuous basement membrane is present but no pericytes are seen. This type of capillary can be classified as Type A-2- α according to the classification established by Bennett, Luft and Hampton (1959) (see Appendix 1). Capillaries of this type are typically found in the glomerulus of the kidney (Rhodin, 1962) and chorioid plexus (Pease, 1956) and other areas where large volumes of fluid are transported across the capillary wall.

The retinal capillaries, on the other hand, have a continuous endothelium with no fenestrations and a continuous basement membrane (Wolter, 1957; Maeda, 1959; Kissen and Bloodworth, 1961; Hogan and Feeney, 1963; Ishikawa, 1963; Bernstein and Hollenberg, 1965a). In addition an incomplete covering of pericytes of mural cells are present around the endothelial cells and are always surrounded in the adult by a layer of basement membrane material (Kuwabara and Cogan, 1963; Bernstein and Hollenberg, 1965a). These capillaries can be classified as Type A-1- α (Bennett et al, 1959).

The hyaloid capillaries have been briefly described by Lasansky (1967) on the surface of the toad retina and the fine structure of the hyaloid capillaries forming the tunica vasculosa lentis has been described in the human by Mikawa (1965). These capillaries, as described by Mikawa, are composed of a continuous endothelium, a thin but continuous basement membrane and a few pericytes. Thus they would be classified as Type A-1- α (Bennett et al, 1959).

2) A Review of Studies on the Fine Structure of the Developing Eye.

Very little work has been done on the fine structure of the developing eye and the majority of this has been on the developing photoreceptor cell (De Robertis, 1956a, 1960; Tokuyasu and Yamada, 1959; Cohen, 1963; Nilsson, 1964; Olney, 1968). The majority of workers who have studied the development of the outer

segment of the rod conclude that the discs of the outer segment are formed by a process of invagination of the plasma membrane of the inner segment which later became oriented in the mature condition. Leeson (1968) however feels that the pigment epithelium may contribute some of the membranous material for the outer segment discs. Young (1965, 1966, 1967, 1968) has done extensive autoradiographic work on the renewal of photoreceptor outer segments and has shown conclusively that discs are constantly being formed at the base of the outer segment. Once formed the discs then move outwards towards the pigment epithelium and eventually are ingested by the pigment epithelium.

Dowling and Gibbons (1962) and Leeson (1968) have investigated the fine structure of the developing pigment epithelium in the rat and have shown that the pigment epithelial layer is mature in advance of the photoreceptor outer segments.

Some work has also been done on the fine structure of the vasculature of the eye during development. Shakib and de Oliveira (1966) and Shakib et al (1968) have studied the developing retinal capillaries in the cat and rat and support the idea of budding as a means of new vessel formation. The basement membrane of the retinal capillaries appears to be formed by both the endothelial cells and the pericytes (Shakib and de Oliveira 1966).

III MATERIALS AND METHODS

The animals used in the study were healthy specimens of the Wisconsin strain of the Sprague-Dawley albino rat (Rattus norvegicus). Rats were fed Purina lab chow and water ad libitum and in addition, nursing females were fed rolled oats. To determine the age of the prenatal rats, daily vaginal smears of the breeding females were used. The first day of gestation was taken to be the day when spermatozoa were first detected in the smear. The degree of development of each specimen prior to the 20th day of gestation, was determined by reference to the system of standard developmental stages of Christie (1964).

1. Light Microscopy

Beginning on the 10th day of gestation, pregnant females were anesthetized with an intraperitoneal overdose of pentobarbital (Nembutal) and the prenatal rats were surgically removed from the uterus. Embryonic eyes were obtained in this manner at daily intervals from the 10th day of gestation until birth. The eyes were removed intact from the embryo and fixed whole in either Bouin's fixative or 10% phosphate-buffered formalin for 24 hours. In the case of small embryos the whole head was fixed and in the earliest stages (10th-14th day of gestation) the whole embryo was fixed. Following fixation, the eyes (or

embryos) were dehydrated in graded ethyl alcohols, cleared in Terpeneol (Fisher Scientific Co.) and embedded in paraffin (Tissue-mat m.p. 56.5, Fisher Scientific Co.).

Rats after birth were sacrificed at daily intervals up to 10 days after birth, every second day from 12 to 20 days and on the 40th, 50th, 100th and 225th day after birth. The rats were anesthetized with an intraperitoneal overdose of pentobarbital, their eyes removed, fixed whole and processed in the same manner as the embryonic material. Serial sections of the eyes studied were cut at 5μ and stained with Ehrlich's alum hematoxylin (Gray 1954 p. 289) and Bowie's Eosin.

Measurements were made on the width of the retinal layers, both posteriorly and peripherally within each eye studied, using a calibrated eye piece. To insure that the plane of section was horizontal and through the greatest width of the globe, measurements were taken only on sections which showed the optic nerve, pupil and cornea. On each day studied, a total of 10 measurements were taken both posteriorly and peripherally from the eyes of at least 2 rats. The measurements were averaged and the standard error for each mean calculated (Table 1 and Text-Figs. 1 and 2). The posterior measurements were taken immediately adjacent to the optic disc and the peripheral measurements were taken at a point halfway between the equator and the ora serrata. Except in the case of the ganglion cell layer, initial measurements of the thickness of each retinal layer were taken as soon as the layer appeared as a distinct entity. Measurements of the thickness of the ganglion cell layer on the 16th

and 17th days of gestation were taken prior to the appearance of the inner plexiform layer. On these days, the ganglion cell layer arbitrarily was taken to include the group of spherical nuclei forming at the inner edge of the neuroblastic layer, since almost all of these nuclei eventually become nuclei of ganglion cells. Measurements of the thickness of the whole retina extended from the inner limiting membrane to the outer border of the neural retina and did not include the pigment epithelium.

An estimate of retinal volume (Table 1, Text-Fig. 3) was calculated using the formula $V_{sp} = (1 + \cos x) \frac{2}{3} r^3$, where V_{sp} is the volume of a sphere, radius r from which a cone angle x has been removed. Assuming angle x to be constant, this formula reduces to $V_{sp} = Kr^3$ where K is a constant. In order to apply this formula to the volume of the retina, let radius r_1 , extend from the center of the globe to the scleral edge of the retina and let radius r_2 extend from the center of the globe to the vitreal edge of the retina. Thus $r_1 - r_2 = d$, the thickness of the retina. Using the above formula we get, $V_{retina} = K(r_1^3 - r_2^3) = K(r_1 - r_2)(r_2^2 + r_1r_2 + r_1^2)$. Since the difference d , between r_1 and r_2 is small in relation to the radius r , $V_{retina} \doteq K(r_1 - r_2) 3r^2 \doteq 3Kd r^2$. Since the circumference is proportional to the radius, V_{retina} is proportional to $d l^2$ where l is the circumference of the retina. The value for l was obtained by measuring with an odometer the length of the retina from ora serrata to ora serrata in projected sections passing through the optic nerve, pupil and cornea. For each day, 10 such measurements were made from at least two different

rats and averaged. The value d was obtained by averaging the posterior and peripheral thickness of the retina on each day studied (Table 1). All measurements were taken on Bouin's fixed material and no attempt was made to correct for shrinkage. However the values obtained should be comparable with one another as a standard technique was employed throughout.

A Wild M20 microscope equipped with fluotor objective lenses was used throughout the study. All light micrographs were taken on Kodak Panatomic X film using a Kodak #58 green filter and developed in Kodak Microdol X at 68°F for 9 minutes. The terminology used to describe the developing eye is that suggested by O'Rahilly (1966).

2. Electron Microscopy

In the case of the prenatal rats, each pregnant female was anesthetized with an intraperitoneal injection of pentobarbital (Nembutal) and the fetal rats removed surgically. Fetal eyes were obtained at daily intervals from the 15th day of gestation until birth. The prenatal eyes were removed intact, opened at the equator with a razor blade and fixed whole, in either cold 4% glutaraldehyde in Sorensen's phosphate buffer (0.2 - 0.5M at pH 7.3) for 5 hours, or in cold 2% osmium tetroxide in Sorensen's or Zetterquist's phosphate buffer (0.2 - 0.5M at pH 7.3) for 2 hours. Eyes fixed initially in glutaraldehyde were washed in 5% sucrose in the same phosphate buffer for 2-18 hours and cut into small pieces with a razor blade while in the sucrose wash. The tissue was then post-

fixed for 2 hours in 1% or 2% osmium tetroxide in Sorensen's buffer (0.2 - 0.5M at pH 7.3), dehydrated in graded alcohols, transferred to acetone, then to styrene and embedded in Vestopal W. In the case of the tissue fixed in osmium tetroxide alone, the tissue was cut into small pieces in the 30% alcohol stage and then dehydrated and cleared as above.

Rats after birth, taken at daily intervals up to 16 days after birth, were anesthetized with an intraperitoneal overdose of pentobarbital (Nembutal) and their eyes removed intact. The globe was opened at the equator with a razor blade and fixed whole by either of the two methods outlined above.

The capillaries and the pigment epithelium were located by examining thick (1-2 μ) sections cut from the embedded tissue and stained with hot cresyl fast violet. Thin sections were then cut of areas containing the capillaries and/or pigment epithelium. Hyaloid capillaries were located and sectioned on the lens, retina and within the vitreous. Retinal capillaries were sectioned in a number of sites throughout the retina.

Thin sections were cut on a Porter Blum MT-1 or a Reichert Om U2 ultramicrotome and placed on formvar coated grids. The sections were stained with both uranyl acetate and lead citrate and examined by a Phillips 100C electron microscope operated at 60 Kv. The 35 mm. fine grain positive photographic film was developed in D-19 (Kodak) for 5 min. at 22°C.

Hyaloid capillaries were arbitrarily taken to be those capillaries lying internal to the inner limiting membrane of

the retina. Retinal capillaries were those capillaries located within the substance of the retina. The term "pericytes" is used in this study to refer to those cells lying immediately external to the endothelial cells of both the hyaloid and retinal capillaries and forming a part of the capillary wall. The pericytes are the same cells which Cogan and Kuwabara (1967) have called mural cells and Ashton and de Oliveira (1966) have termed intramural pericytes, when referring to retinal capillaries.

IV OBSERVATIONS

1. Development of the Retina of the Albino Rat.

11th day of gestation (Stage 20-Christie 1964) (Fig. 1)

The optic vesicles of the Madison Wisconsin strain of the Sprague-Dawley rat are well formed by the 11th day of gestation but have not reached the single layer of surface ectoderm cells. The walls of each of the optic vesicles contain 3 to 4 layers of nuclei and display mitotic figures crowded centrally. Numerous cilia protrude inwards into the optic ventricle.

12th day of gestation (Stage 21-Christie 1964) (Fig. 2)

Early on the 12th day of gestation increased mitotic activity and thickening within the surface ectoderm highlights the appearance of the lens disc. Also at this stage, the optic vesicles show the first signs of invagination.

13th day of gestation (Stage 22B-Christie 1964) (Fig. 3)

On the 13th day the optic cup is well formed and the lens vesicle has invaginated from the surface ectoderm. Mitoses are common within the walls of the lens vesicle and both the external and inverted layers of the optic cup. Mitoses in the retina are always seen at the surface adjacent to the optic ventricle. The external layer of the optic cup, or future pigment epithelium, appears stratified and contains tall columnar cells

Figure 1. 11th day of gestation, (Stage, 20, Christie 1964)

The two optic ventricles (V) are well developed.

Mitotic figures (arrows) are numerous at the luminal edge of the optic vesicles (VE).

Fixative: Bouin's (X 575)

Figure 2 12th day of gestation, (Stage, 21, Christie 1964)

The lens disc (arrow) is present as a thickening of the surface ectoderm. The optic vesicle has enlarged and displays continued mitotic activity centrally.

Fixative: Bouin's (X 575)

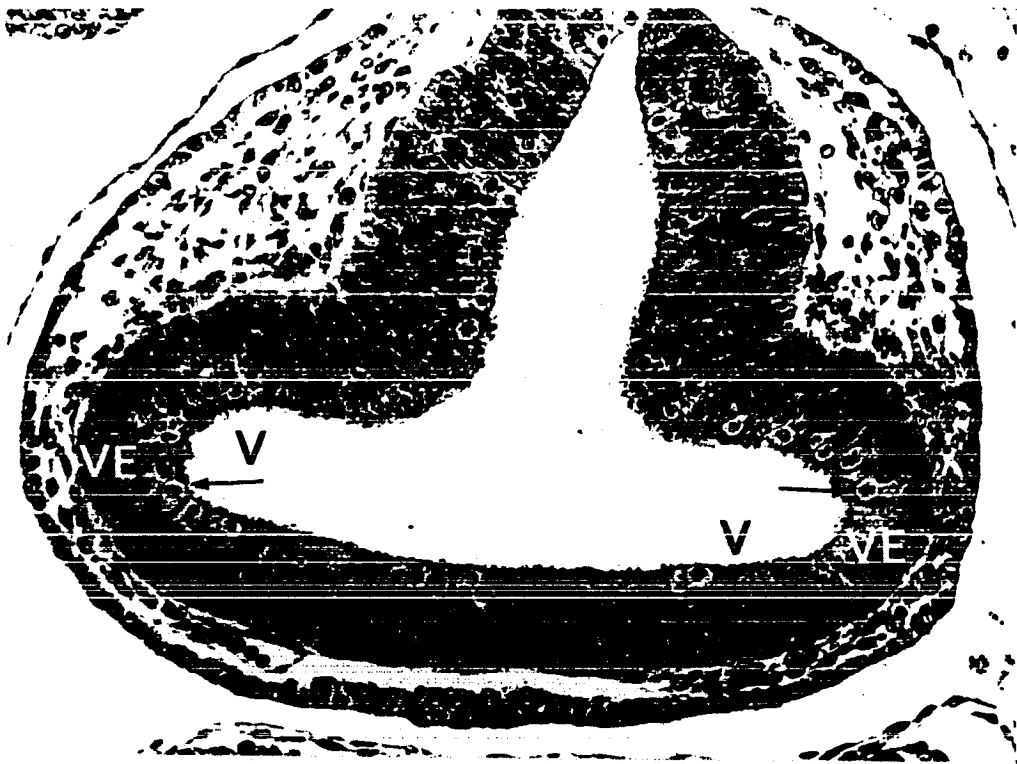


FIGURE 1

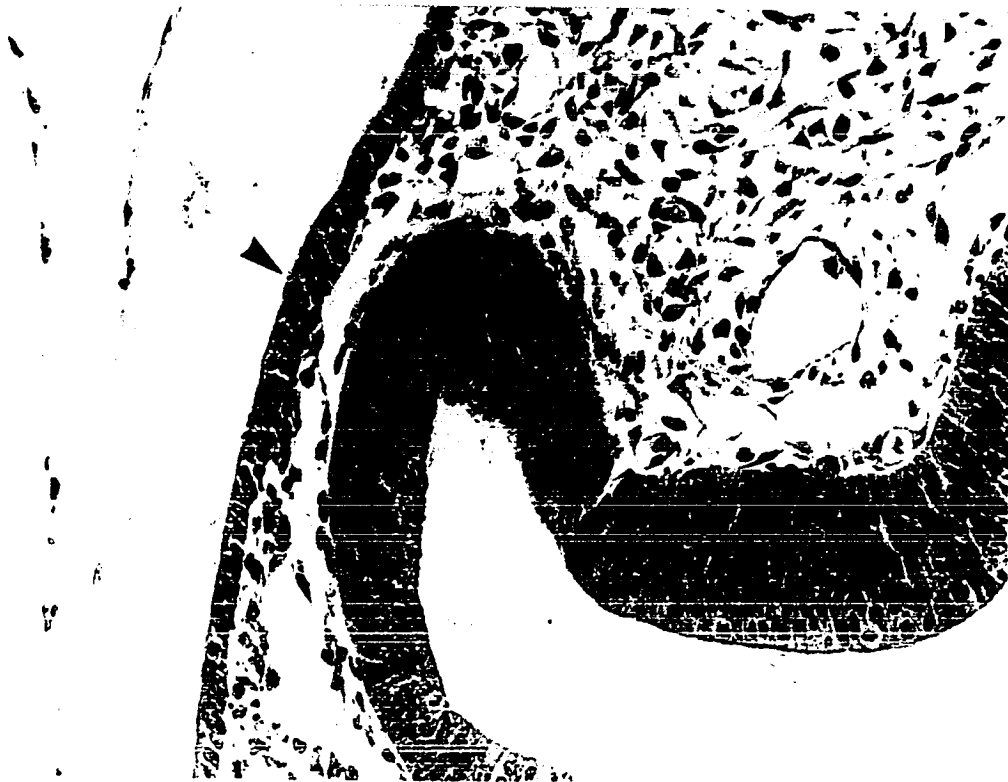

FIGURE 2

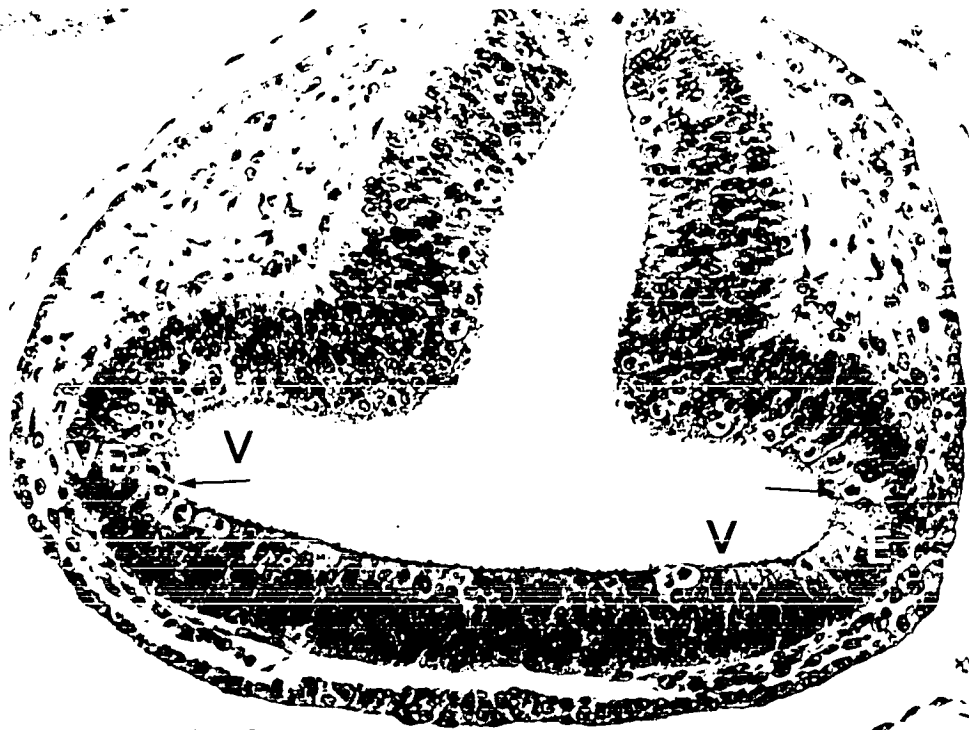


FIGURE 1

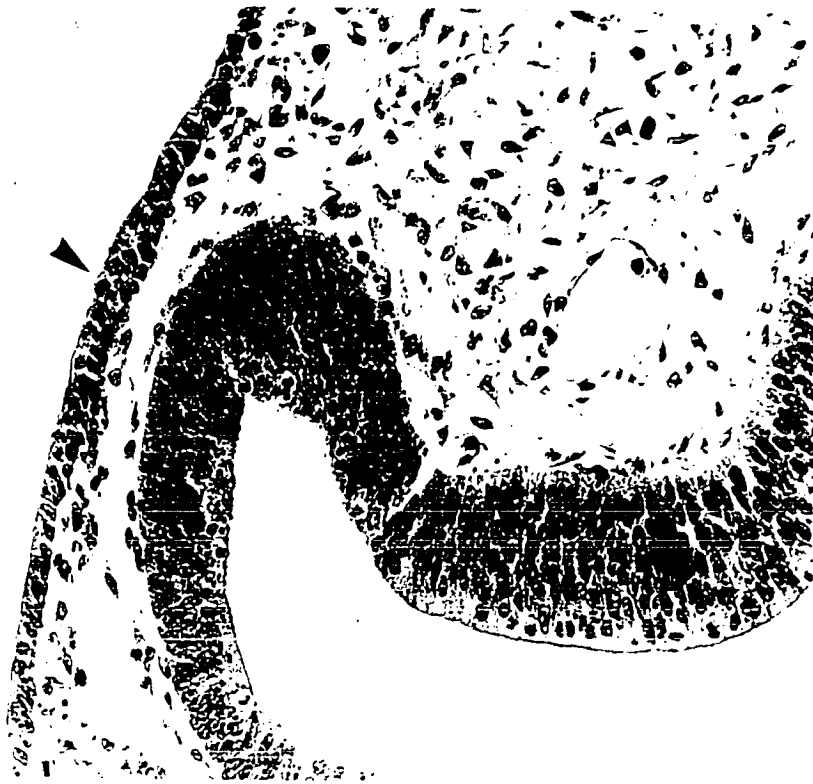


FIGURE 2

Figure 3 13th day of gestation, (Stage 22B, Christie 1964)

The optic cup has formed and both its external and inverted layers are evident. The optic ventricle remains open. The lens has invaginated but has not yet closed off from the surface.

Fixative: Bouin's

(X 575)

Figure 4 14th day of gestation, (Stage 23C, Christie 1964)

Mitoses remain common in the neuroblastic layer (NBL) and the pigment epithelium (PE). Hyaloid vessels (arrows) are seen within the future vitreal cavity. The lens vesicle is completely closed.

Fixative: Bouin's

(X 575)

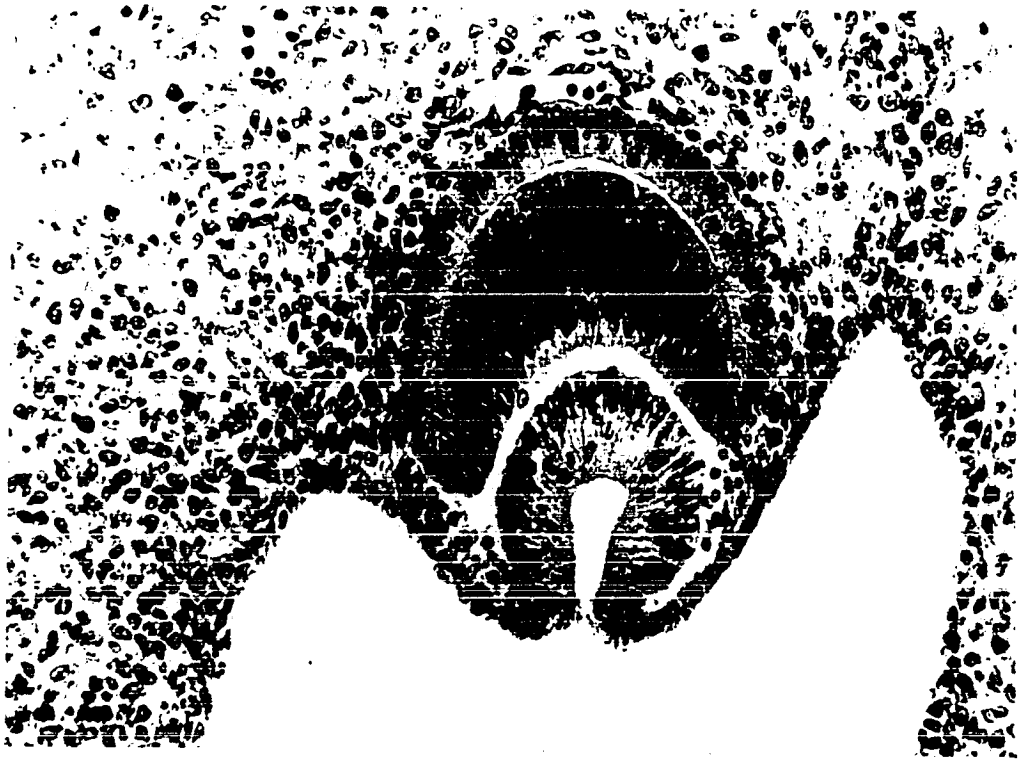

FIGURE 3

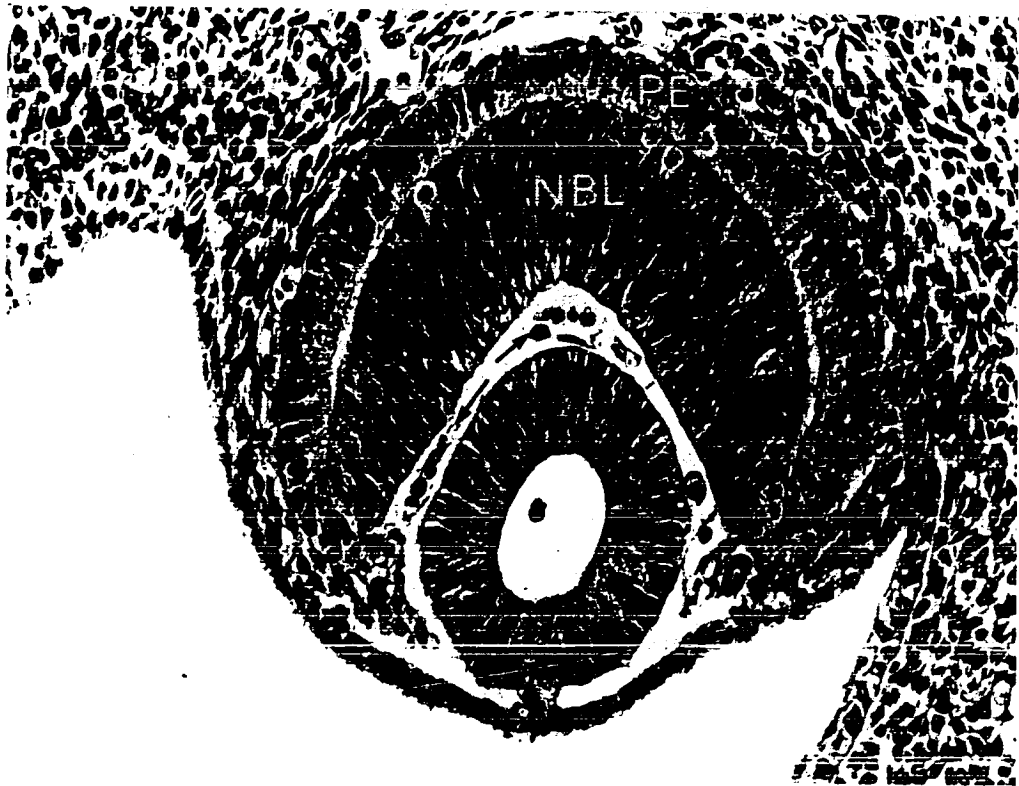


FIGURE 4

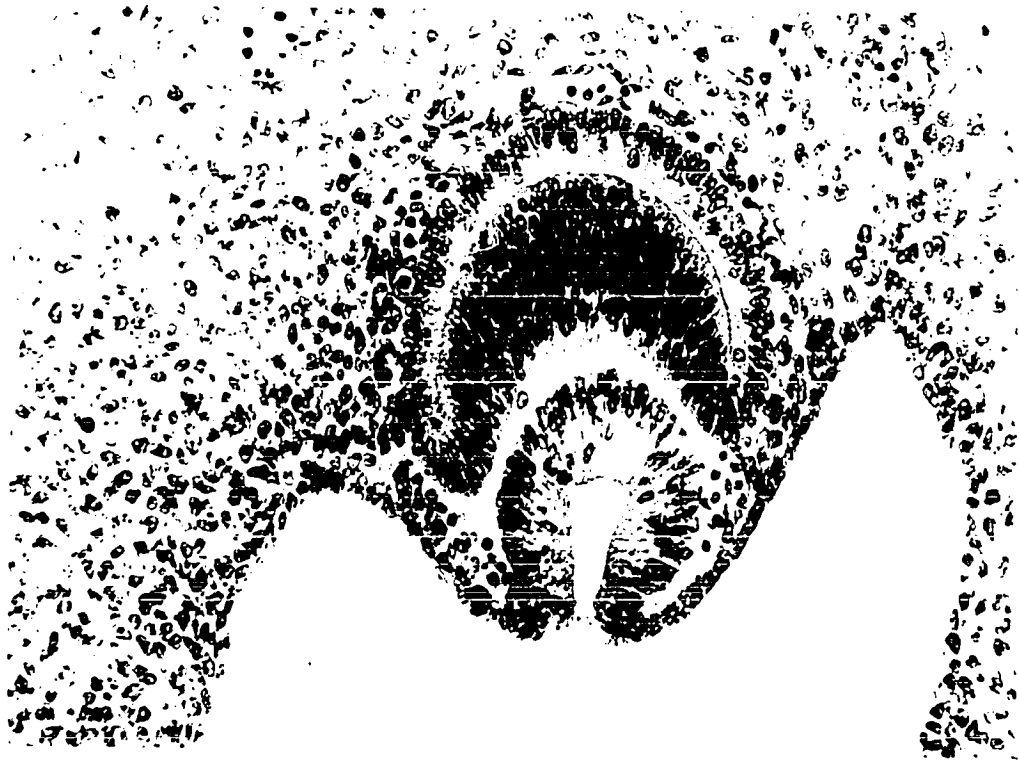


FIGURE 3

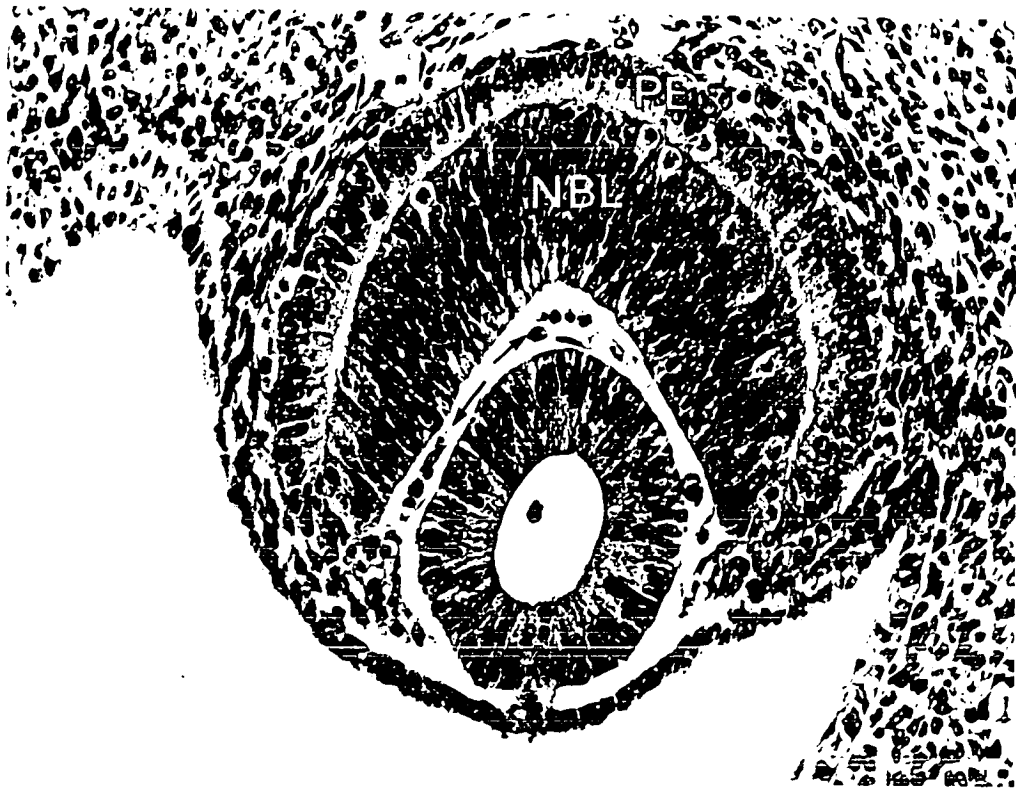


FIGURE 4

with large oval nuclei in the long axis of each cell. The inverted layer of the optic cup consists of several layers of columnar cells with indistinct borders and large oval nuclei. A narrow marginal zone free of cell nuclei is visible within the inverted layer bordering the antrum of the optic cup or the future vitreal cavity. Elements of the hyaloid system are present within the antrum and a few capillaries of the future choriocapillaris are visible in the mesoderm bordering the external layers of the optic cup.

14th day of gestation (Stage 23C-Christie 1964) (Fig. 4)

Early on the 14th day of gestation, the lens vesicle separates from the surface ectoderm and the cells of the deep wall of the vesicle begin to grow forward. The optic ventricle is now almost obliterated and the external and inverted layers of the optic cup are in contact in most places. The inverted layer of the retina continues to thicken and mitotic figures are regularly encountered at its choroidal edge. The nuclei free zone at the inner border of the inverted layer has spread peripherally to the equatorial region of the developing eye. Hyaloid vessels are now plentiful on the surface of the lens vesicle and within the antrum of the optic cup.

15th day of gestation (Stage 26-Christie 1964) (Fig. 5)

By the 15th day of gestation, the primary lens fibres are well formed. The pigment epithelial layer of the retina is now present as an uneven, single layer of roughly cuboidal cells with round nuclei. Mitoses are scarce in this layer, even at the

Figure 5 15th day of gestation, Posterior retina (Stage 26,
Christie 1964)

The innermost nuclei of the neuroblastic layer are beginning to become spherical in shape (arrows). Mitotic figures are still common at the outer border of the neuroblastic layer but are no longer evident in the pigment epithelium posteriorly. The primary lens fibres have grown forward.

Fixative: Bouin's (X 575)

Figure 6 17th day of gestation, Posterior retina (Stage 30,
Christie 1964)

The inner six to seven layers of nuclei within the neuroblastic layer have become more spherical and somewhat less dense. The nerve fibre layer (NFL) is now well formed and can be traced to the developing optic nerve. The hyaloid artery (H) is obvious.

Fixative: Bouin's (X 575)




FIGURE 5

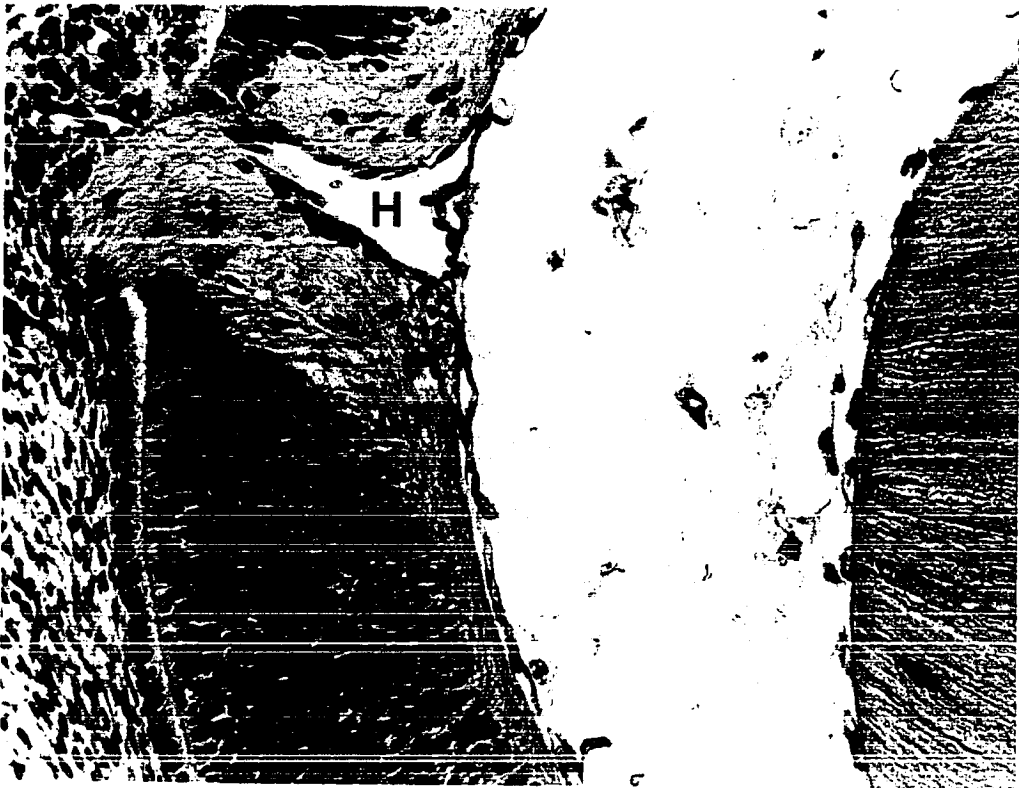

FIGURE 6

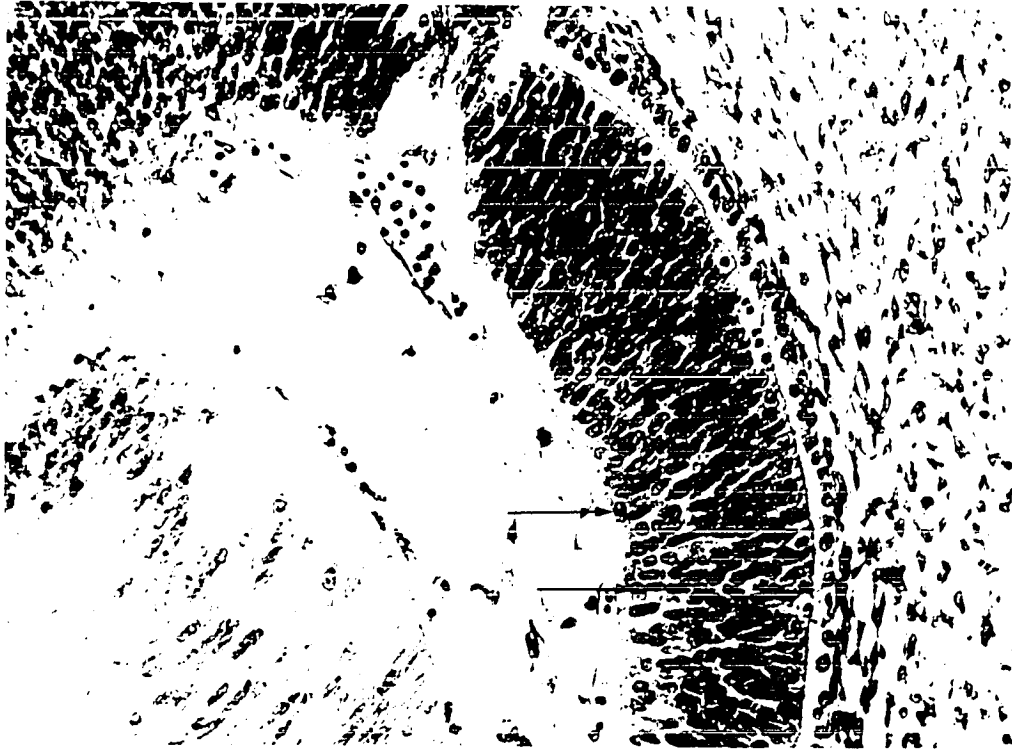


FIGURE 5

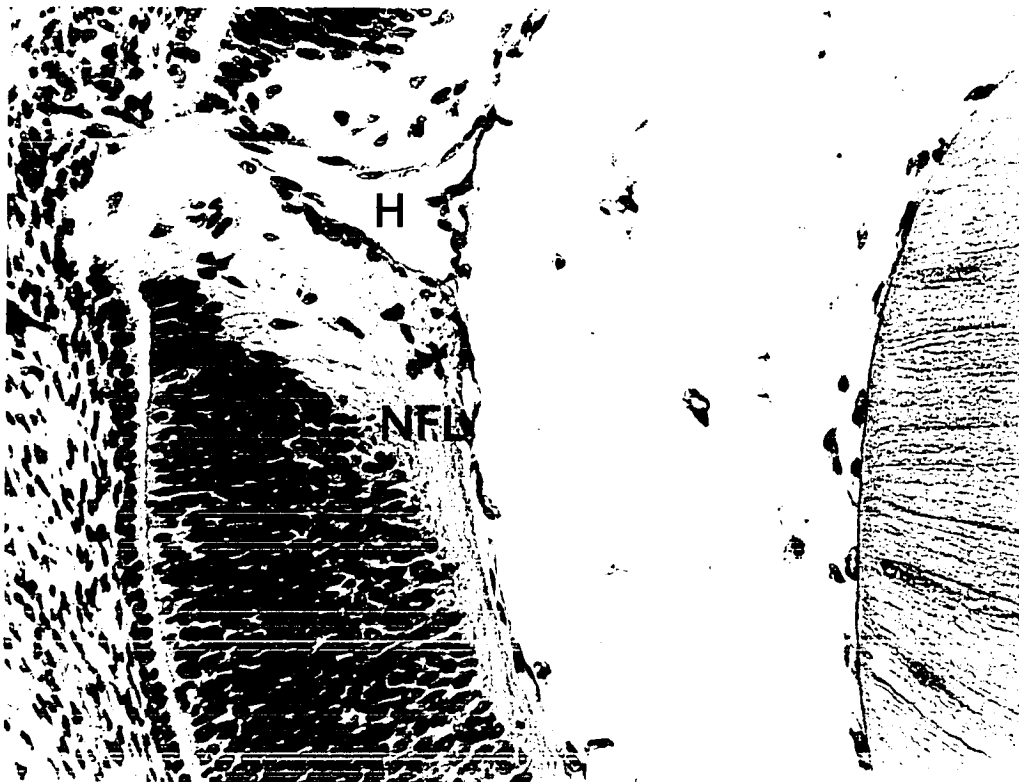


FIGURE 6

periphery. The inverted layer of the retina, containing a single nuclear or neuroblastic layer, is constantly thickened by extensive mitotic activity at its choroidal edge. The marginal zone, separating the inner edge of the neuroblastic layer from the vitreous, now contains nerve fibres running parallel to the internal limiting membrane as they pass towards the optic nerve. Although the main bulk of the nuclei within the neuroblastic layer remain oval in shape, the inner 2 or 3 layers of nuclei have become slightly rounder.

17th day of gestation (Stage 30-Christie 1964) (Fig. 6)

By the 17th day of gestation, several layers of paler round nuclei are present at the inner border of the neuroblastic layer. Almost all of these cells with round nuclei will become ganglion cells. The central processes of the ganglion cells now form a distinct nerve fibre layer and can be traced to the optic nerve. The differentiation of ganglion cells as a distinct layer begins posteriorly adjacent to the optic nerve, spreads peripherally, and reaches almost to the edge of the retina by the end of the 17th day.

18th day of gestation (Stage 32-Christie 1964)
(Fig. 7, posterior retina)

At this stage, the ganglion cells begin to move inwards away from the main bulk of the neuroblastic layer. The inner plexiform layer first appears posteriorly as a relatively clear zone between the round, lighter staining, ganglion cell nuclei and the oval more darkly staining and compact nuclei com-

Figure 7 18th day of gestation, Posterior retina (Stage 32,
Christie 1964)

The inner plexiform layer (IPL) makes its appearance as the paler, innermost nuclei of the neuroblastic layer (NBL) move inwards.

Fixative: Bouin's (X 575)

Figure 8 20th day of gestation, Posterior retina

The inner plexiform (IPL), ganglion cell (GCL) and nerve fibre layers (NFL) are now well established. Cells are still being added to the outer border of the neuroblastic layer.

Fixative: Bouin's (X 575)




FIGURE 7




FIGURE 8




FIGURE 7

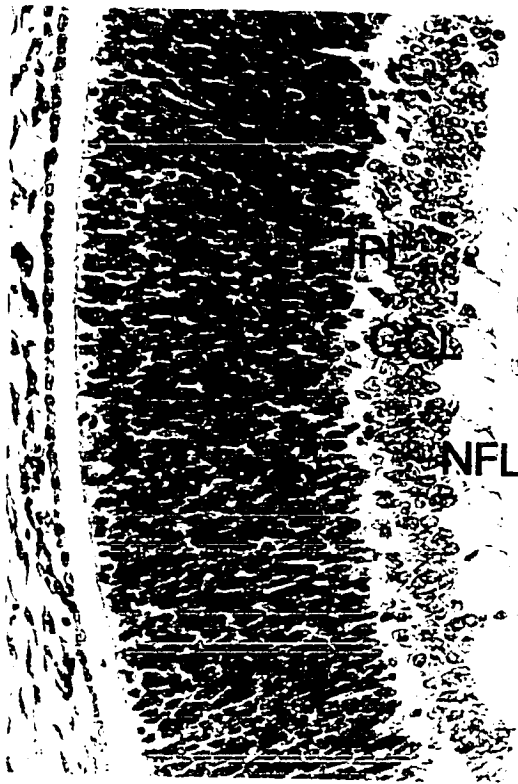


FIGURE 8

prising the main portion of the neuroblastic layer. Numerous mitotic figures are still present at the choroidal edge of the neuroblastic layer. Elements of the hyaloid system are plentiful in the vitreal cavity.

20th day of gestation (Fig. 8, posterior retina)

By the 20th day, the inner plexiform layer is prominent posteriorly but still contains migrating nuclei within it. The ganglion cell layer, which has now completely separated from the neuroblastic layer posteriorly, is composed of 6 to 7 layers of loosely arranged cells. The ganglion cell nuclei are roughly spherical and stain less intensely but are larger than the nuclei of the more undifferentiated cells of the neuroblastic layer. Cell margins remain indistinct. Müller cell processes contributing to the internal limiting membrane are now visible within the nerve fibre layer. The vessels of the hyaloid system are still obvious at the inner edge of the retina but do not appear as numerous as before. The pigment epithelial layer is now a single layer of low cuboidal cells. Mitoses remain numerous at the outer border of the neuroblastic layer as the latter continues to grow in thickness. The nuclei of the neuroblastic cells remain oval and contain dense, compact chromatin.

21st day of gestation (Fig. 9, posterior retina)

On the last day of gestation, the nerve fibre layer, ganglion cell layer, inner plexiform layer and single neuroblastic layer are present within the neural retina and are distinct to the retinal periphery. A few nuclei which resemble those of the ganglion cell layer, can be made out scattered within the inner

Figure 9 21st day of gestation, Posterior retina

The inner plexiform layer (IPL) is distinct and contains very few nuclei. Mitoses remain common at the choroidal edge of the thickening neuroblastic layer.

Fixative: Bouin's

(X 575)

Figure 10 4th postnatal day, Posterior retina

The neuroblastic layer (NBL) has increased greatly in thickness. The inner plexiform layer has also increased in width but the ganglion cell layer has thinned. Capillaries of the superficial retinal capillary net are obvious for the first time in the nerve fibre layer (arrows).

Fixative: Bouin's

(X 575)




FIGURE 9

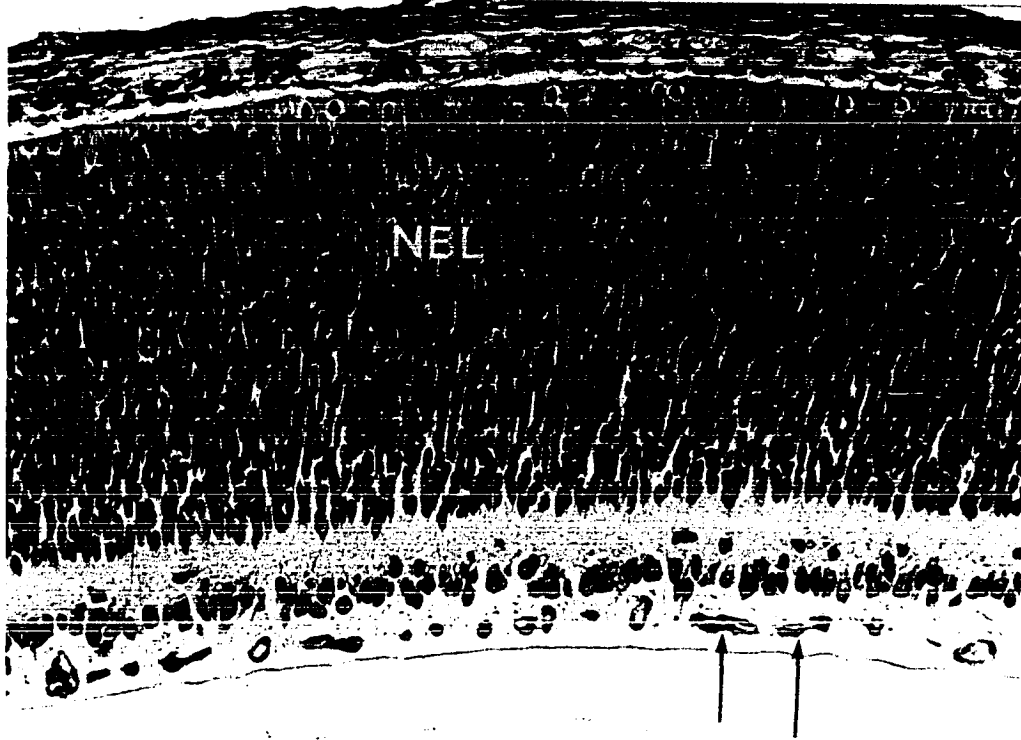


FIGURE 10




FIGURE 9

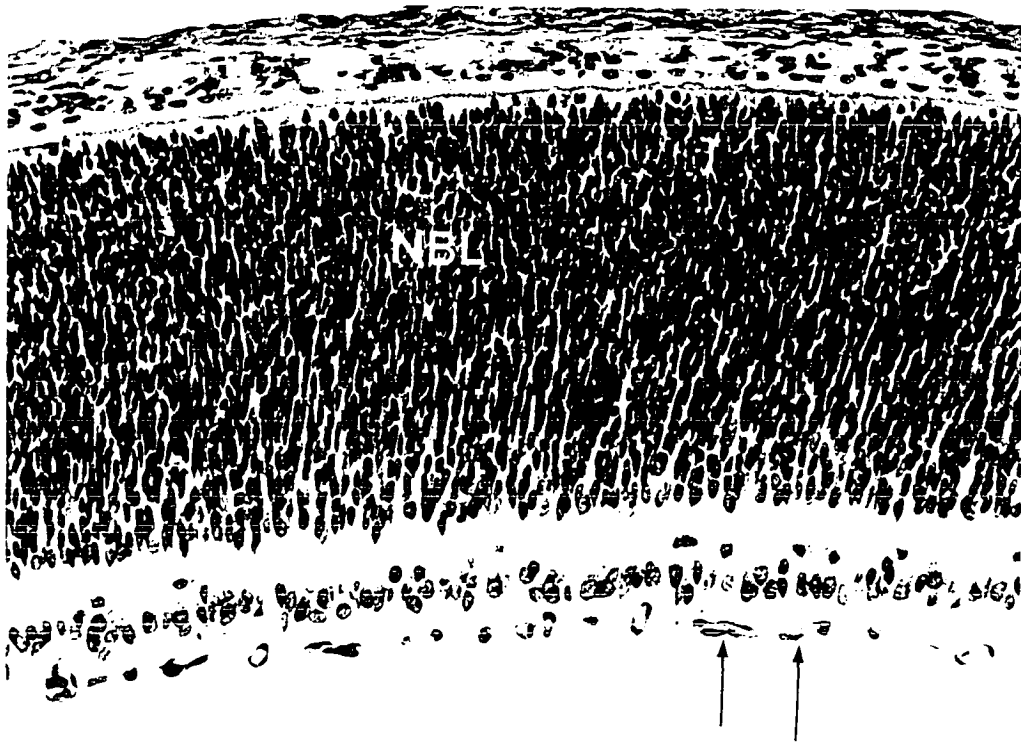


FIGURE 10

plexiform layer. It is impossible to determine, however, whether or not these nuclei belong to ganglion cells or cells from the ganglion cell layer moving back to the neuroblastic layer. The bulk of the nuclei of the neuroblastic layer remain darkly stained and compact and mitotic figures are still common at the choroidal edge. The pigment epithelium at this time is a single, distinct layer of cuboidal cells in which no mitoses are seen.

4th postnatal day (Fig. 10, posterior retina)

During the first 4 days after birth, mitoses at the outer border of the neural retina increase in frequency and the neuroblastic layer is considerably thickened. The nuclei of the neuroblastic layer remain dark and oval but have become less tightly packed close to the inner plexiform layer. The ganglion cell layer during the first 4 postnatal days thins considerably and on the 4th day contains only 2 or 3 layers of large, irregularly placed nuclei. The inner plexiform layer has become more distinct but occasional nuclei can still be made out within its boundaries. The nerve fibre layer has thickened slightly during the first 4 days after birth and in the posterior regions of the eye now contain a rich capillary network.

5th postnatal day (Fig. 11, posterior retina)
(Fig. 12, peripheral retina)

The outer plexiform layer first appears posteriorly on the 5th postnatal day as a slight separation within the nuclei of the neuroblastic layer and subsequently spreads peripherally. The nuclear separation occurs so that approximately the inner 2/3

Figure 11 5th postnatal day, Posterior retina

The outer plexiform layer (OPL) makes its first appearance as a splitting of the neuroblastic layer to give the inner nuclear layer (INL) and the outer nuclear layer (ONL). Mitosis has ceased and the first indications of the bacillary layer (BL) are visible.

Fixative: Bouin's

(X 575)

Figure 12 5th postnatal day, Peripheral retina

Development is slower peripherally. The neuroblastic layer (NBL) has not yet divided to form the outer and inner nuclear layers and mitoses are still prevalent at its outer border.

Fixative: Bouin's

(X 575)




FIGURE 11




FIGURE 12




FIGURE 11




FIGURE 12

of the thickness of the neuroblastic layer becomes the inner nuclear layer and the outer 1/3 becomes the outer nuclear layer. Concurrently, mitotic activity at the outer border of the neural retina ceases posteriorly and the formation of the bacillary layer begins. The nuclei of the inner nuclear layer are larger and not as compact as those of the outer nuclear layer, but in both layers, the nuclei are predominantly oval in shape. (Fig. 11). Peripherally on the 5th postnatal day, the neuroblastic layer is still intact and mitotic figures remain common at its outer border (Fig. 12).

7th postnatal day (Fig. 13, posterior retina)
(Fig. 14, peripheral retina)

By the 7th postnatal day, the inner and outer nuclear layers have become more equal in thickness posteriorly. Three zones of nuclei in the inner nuclear layer may be made out at this stage; an outer zone composed of small dense nuclei, a middle zone containing predominantly oval nuclei and an inner zone of larger, less compact, nuclei (Figs. 13 and 14). In the periphery of the retina, the outer plexiform layer is now apparent as a slight separation of the nuclei of the neuroblastic layer. Mitosis at the outer border of the neuroblastic layer has almost ceased and formation of the inner segments of the photoreceptors has begun (Fig. 14).

9th postnatal day (Fig. 15, posterior retina)
(Fig. 16, peripheral retina)

On the 9th neonatal day, all the layers of the retina are present both posteriorly (Fig. 15) and peripherally (Fig. 16)

Figure 13 7th postnatal day, Posterior retina

All layers of the retina are now present although not in the mature condition. The outer plexiform layer (OPL) is more obvious now. Three distinct zones of nuclei with differing morphology are visible within the inner plexiform layer.

Fixative: Bouin's

(X 575)

Figure 14 7th postnatal day, Peripheral retina

The outer plexiform layer (OPL) makes its first appearance peripherally. Mitosis has now stopped at the choroidal edge of the retina.

Fixative: Bouin's

(X 575)




FIGURE 13

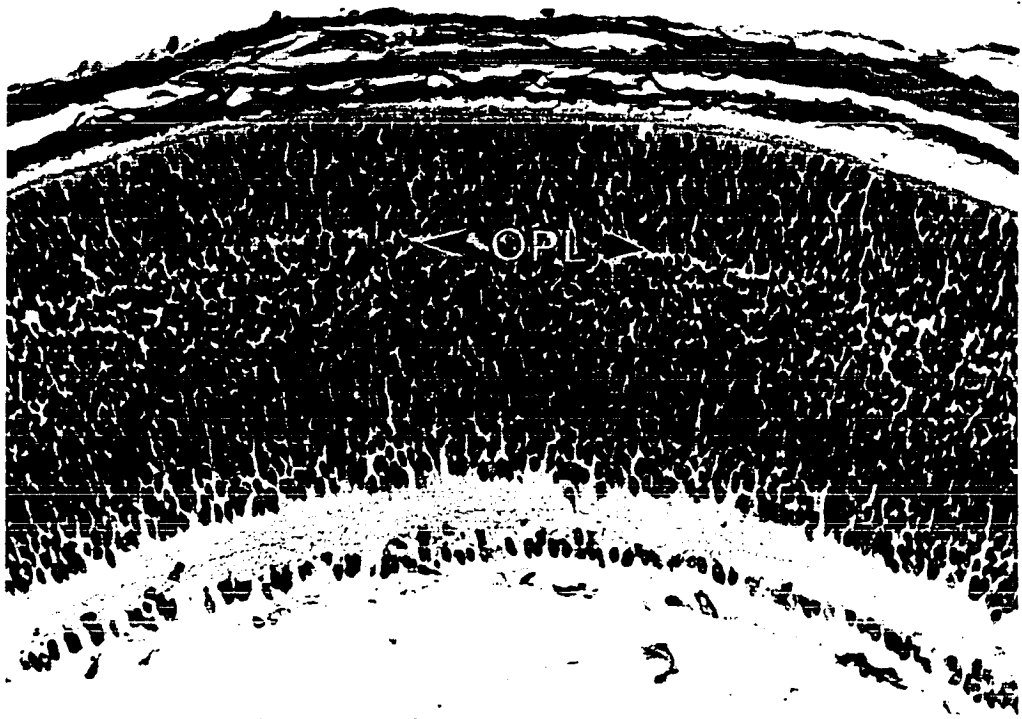


FIGURE 14



FIGURE 13




FIGURE 14

Figure 15 9th postnatal day, Posterior retina

The layers of the retina are now beginning to approach their adult condition in thickness and appearance. The bacillary layer (BL) is now more prominent and the inner and outer plexiform layers have increased in thickness.

Fixative: Bouin's (X 575)

Figure 16 9th postnatal day, Peripheral retina

All the retinal layers are now established peripherally, but not as well developed as they are posteriorly. The bacillary layer (BL) is distinguishable peripherally but occupies only a narrow zone.

Fixative: Bouin's (X 575)

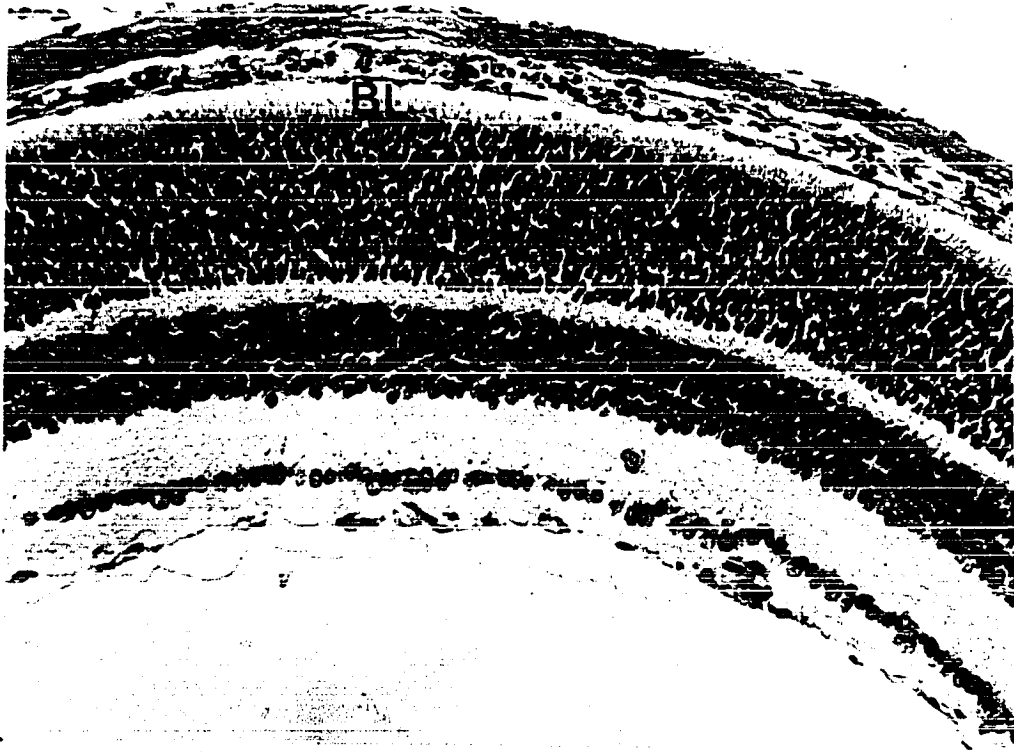

FIGURE 15

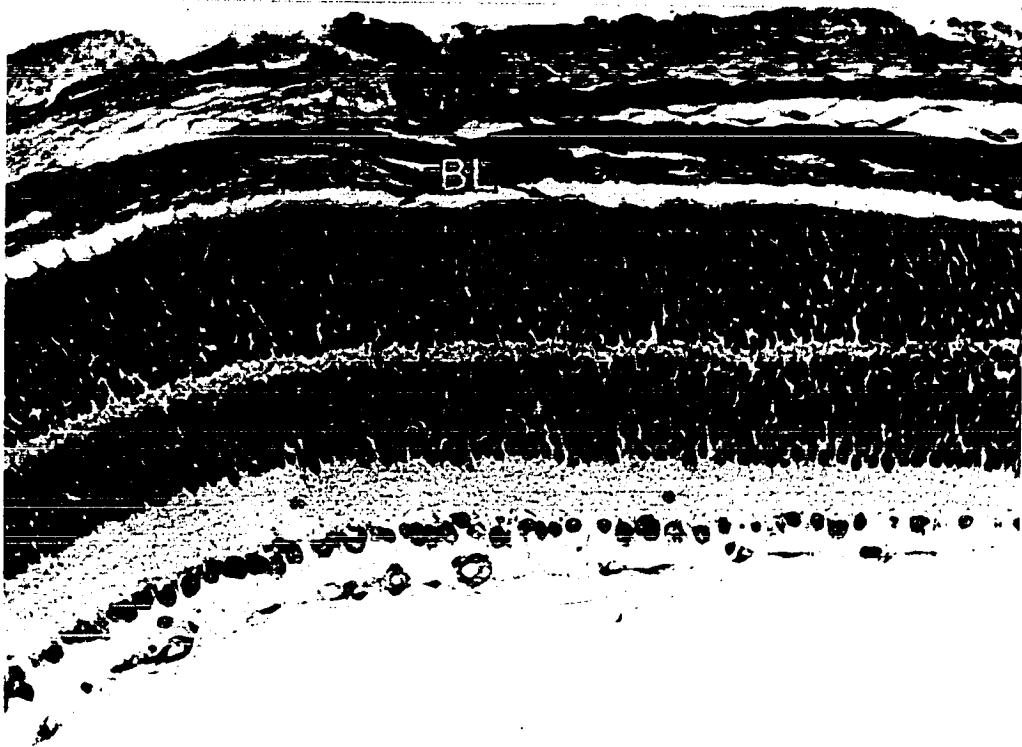


FIGURE 16

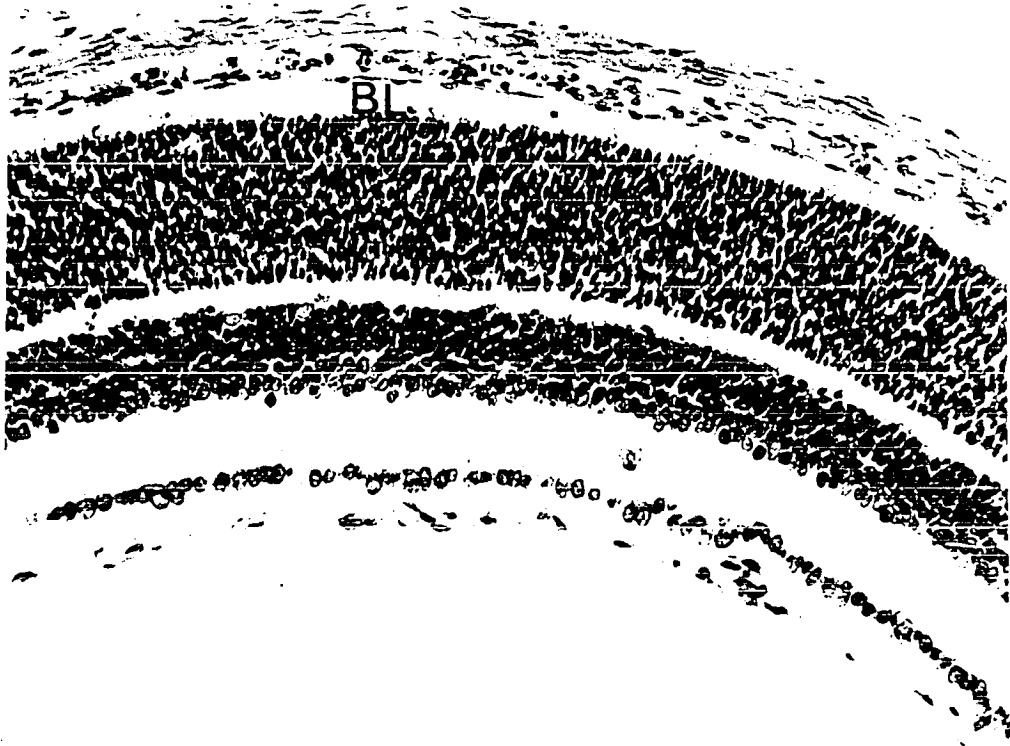


FIGURE 15

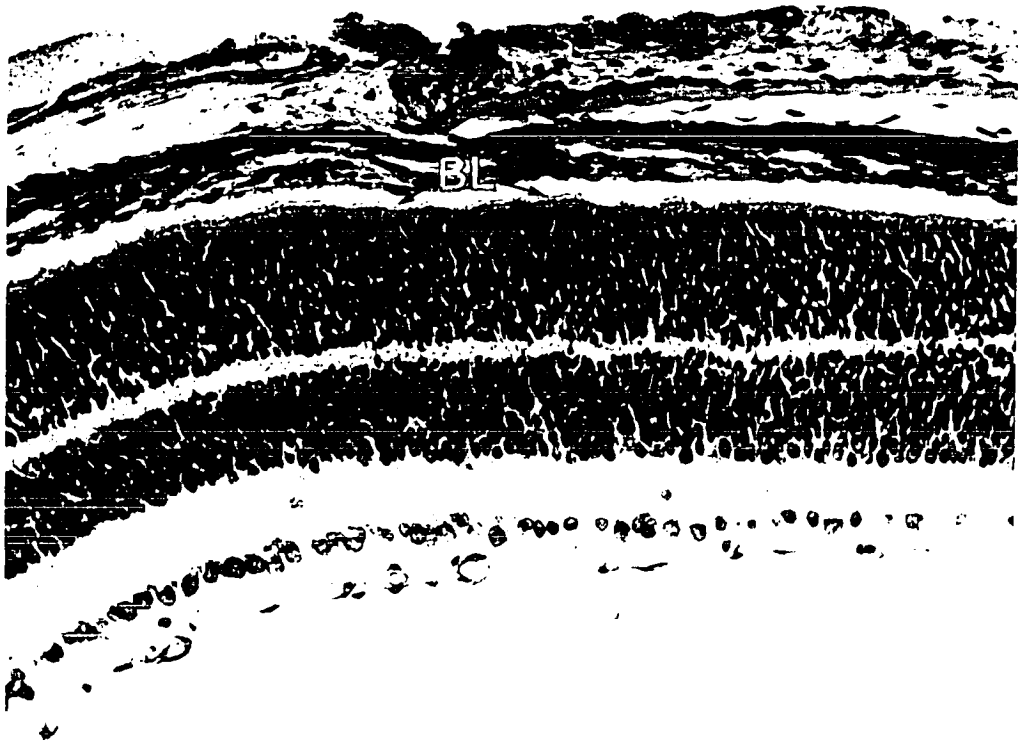


FIGURE 16

and are approaching their adult proportions. The bacillary layer is now well established and the inner and outer plexiform layers have thickened. The ganglion cell layer posteriorly is now a single continuous layer of large nuclei. Peripherally, the ganglion cell nuclei are becoming separated but still constitute a single layer. The inner nuclear layer is thinner but the three nuclear zones described previously are still distinguishable. The outer nuclear layer is thicker than the inner layer and its nuclei remain dark and compact. Mitosis is still present at this stage at the extreme periphery of the retina and will continue in this location until the 10th to the 12th postnatal day.

14th postnatal day (Fig. 17, posterior retina)

The inner plexiform layer continues to thicken and within it can be seen capillaries connecting the superficial capillary net in the nerve fibre layer and the deep capillary network now visible within the outer plexiform layer. Within the inner nuclear layer, the majority of nuclei are now round and pale, although dense, oval nuclei can still be recognized. The nuclei of the outer nuclear layer have become difficult to delineate because their chromatin tends to form several clumps within each nucleus. The bacillary layer is now well developed and outer segments have appeared.

50th postnatal day (Fig. 18, posterior retina)

On the 50th day, the ganglion cell layer remains unchanged but the inner and outer nuclear layers are both more compact, and thinner. The nuclei of the inner nuclear layer are predominantly

Figure 17 14th postnatal day, Posterior retina

The bacillary layer (BL) and the inner plexiform layer (IPL) have thickened. Retinal capillaries are visible crossing the inner plexiform layer to the deep capillary net in the outer plexiform layer (arrows).

Fixative: Bouin's

(X 575)

Figure 18 50th postnatal day, Posterior retina

The inner and outer segments of the photoreceptor cells are distinct at the outer retinal border. The inner plexiform layer (IPL) has reached its maximum thickness and will remain the thickest layer of the retina.

Fixative: Bouin's

(X 575)

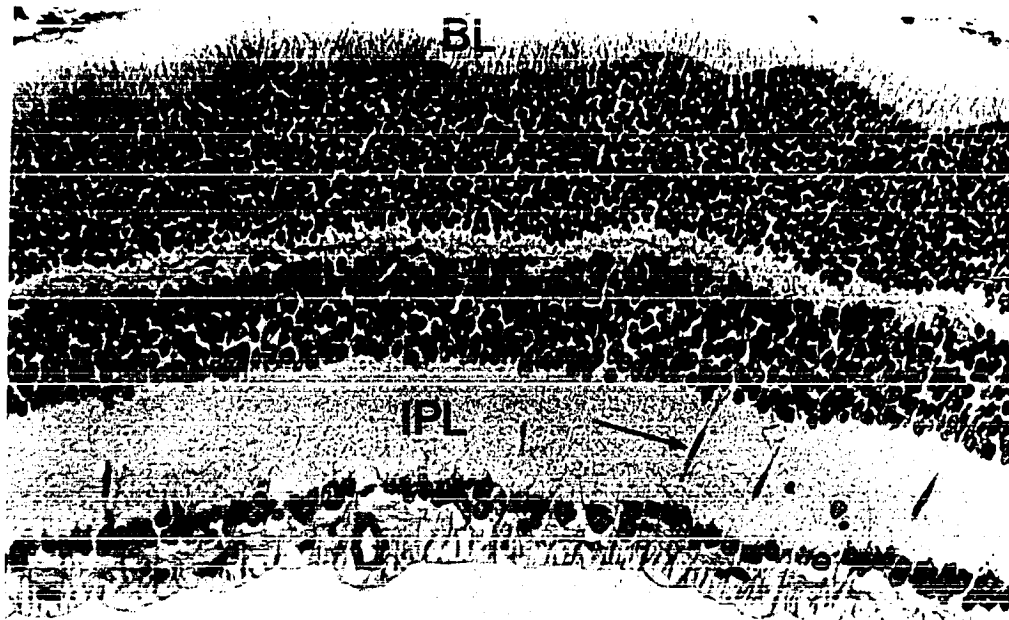


FIGURE 17




FIGURE 18

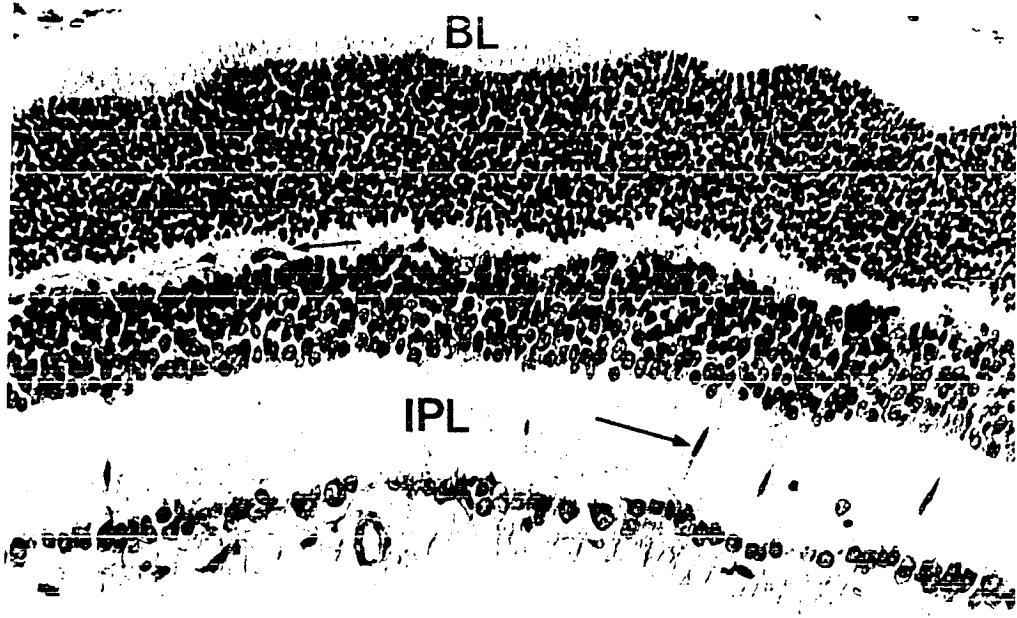


FIGURE 17

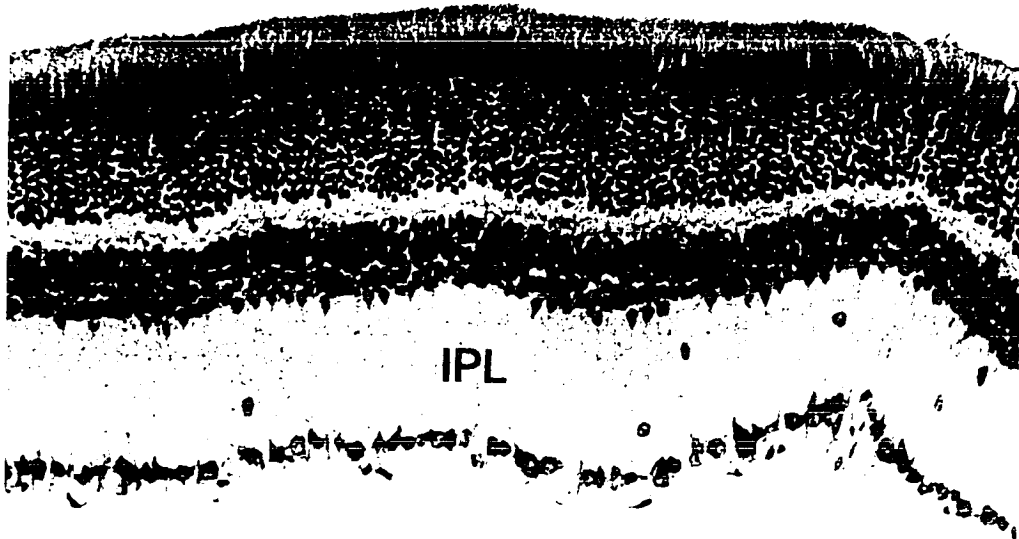


FIGURE 18

Figure 19 225th postnatal day, Posterior retina

The neural retina is thinner than at 50 days due mostly to a decrease in width of the nuclear layers. Almost all the nuclei forming the outer nuclear layer are similar in appearance. The same is due for the nuclei of the inner nuclear layer. The ganglion cell layer (GCL) is now formed by a single row of spherical nuclei.

Fixative: Bouin's (X 575)

Figure 20 225th postnatal day, Peripheral retina

Peripherally, all layers of the retina except the ganglion cell layer are thinner than posteriorly. The ganglion cell nuclei however are fewer in number and further apart than posteriorly.

Fixative: Bouin's (X 575)




FIGURE 19



FIGURE 20

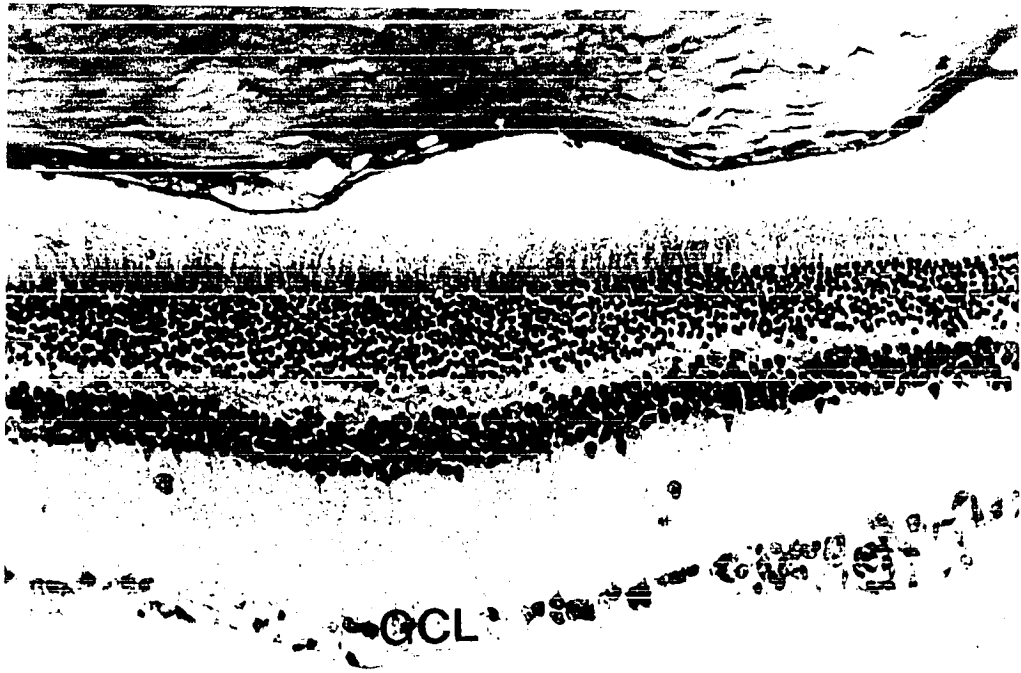

FIGURE 19



FIGURE 20

round and pale and only an occasional nucleus is darker in appearance. The inner plexiform layer has reached its maximal thickness. Both the inner and outer segments of the photoreceptors can be easily distinguished.

225th postnatal day (Fig. 19, posterior retina)
(Fig. 20, peripheral retina)

The retina at 225 days is thinner than at 50 days, due mostly to a decrease in thickness of the inner and outer nuclear layers. The ganglion cell layer is now a discontinuous single layer of nuclei posteriorly (Fig. 19), and peripherally the ganglion cell nuclei are widely spaced (Fig. 20). The bacillary layer is slightly thinner than at 50 days but otherwise is unchanged in appearance.

Analysis of changes in retinal volume, thickness of the neural retina and thickness of the retinal layers.

The thickness of each of the retinal layers as well as the thickness and volume of the entire neural retina at each stage of development are shown in Table 1 and Text-Figs. 1, 2 and 3. The principal features of retinal development revealed by this quantitative analysis are as follows. The volume of the retina continues to increase after the retina as a whole has begun to decrease in thickness (Text-Fig. 3). Retinal volume reaches a peak between the 7th and 12th postnatal days and then decreases slightly whereas retinal thickness reaches its highest point earlier, on the 5th postnatal day. After the 5th postnatal day, the thickness of the neural retina steadily declines

TABLE I THE RELATIONSHIP BETWEEN AGE, DEVELOPMENT OF THE RETINAL LAYERS AND RETINA

	9 days Prenatal	8 days Prenatal	7 days Prenatal	6 days Prenatal	5 days Prenatal	4 days Prenatal	3 days Prenatal	2 days Prenatal	1 day Prenatal	1 day Neonatal	2 day Neonatal	3 day Neonatal	4 day Neonatal	5 day Neonatal	6 day Neonatal	7 day Neonatal	8 day Neonatal	
	μ	μ	μ	μ	μ	μ	μ	μ	μ	μ	μ	μ	μ	μ	μ	μ	μ	
NERVE FIBRE LAYER	Posterior	7.62 ± 1.03	7.62 $\pm .77$	7.62 $\pm .77$	6.19 $\pm .72$	10.47 ± 1.90	18.98 ± 1.80	20.47 ± 1.59	19.99 ± 1.38	22.56 ± 3.18	22.85 $\pm .95$	22.85 ± 1.18	25.70 ± 1.45	27.61 ± 1.18	27.13 ± 1.24	25.70 ± 1.05	22.85 $\pm .95$	23.80 ± 0.00
	Peripheral	3.33 $\pm .72$	4.28 $\pm .85$	5.24 $\pm .48$	4.75 ± 0.00	4.83 $\pm .42$	8.09 $\pm .72$	13.80 ± 2.29	10.47 $\pm .66$	10.47 ± 2.22	15.23 $\pm .95$	14.76 $\pm .47$	12.85 ± 2.01	15.71 $\pm .72$	17.14 ± 1.26	18.56 ± 1.11	18.09 $\pm .63$	17.61 $\pm .70$
GANGLION CELL LAYER	Posterior				29.99 ± 2.75	50.55 ± 1.61	34.75 ± 2.25	35.22 ± 2.03	34.75 ± 3.55	19.99 $\pm .95$	19.99 $\pm .63$	22.85 ± 1.18	19.99 $\pm .95$	22.85 ± 2.85	18.09 $\pm .63$	17.14 ± 1.45	15.23 $\pm .63$	
	Peripheral				8.57 ± 2.45	26.66 ± 1.26	30.46 ± 2.03	37.61 ± 2.50	26.66 ± 1.05	14.76 ± 1.11	15.23 $\pm .95$	18.56 ± 1.31	19.04 ± 0.00	19.99 ± 1.55	14.28 ± 1.23	15.71 ± 1.01	10.54 $\pm .49$	
INNER PLEXIFORM LAYER	Posterior						10.00 $\pm .85$	9.52 ± 0.00	12.38 $\pm .77$	23.80 ± 1.00	24.75 $\pm .63$	29.51 ± 2.33	28.56 ± 1.23	39.98 ± 3.02	31.89 $\pm .72$	34.75 ± 2.25	40.94 $\pm .77$	
	Peripheral						7.62 ± 1.90	9.52 ± 0.00	11.42 $\pm .77$	18.56 $\pm .47$	17.14 ± 3.15	22.37 $\pm .72$	24.28 ± 1.50	28.08 ± 1.49	23.80 $\pm .71$	28.56 ± 1.23	28.56 $\pm .70$	
INNER NUCLEAR LAYER	Posterior													146.61 ± 5.93	112.34 ± 2.57	98.06 ± 2.15	99.48 ± 2.06	
	Peripheral															106.62 ± 3.49	88.06 ± 1.62	
OUTER PLEXIFORM LAYER	Posterior														4.76 ± 0.00	4.76 ± 0.00	7.62 $\pm .77$	7.82 $\pm .50$
	Peripheral																4.76 ± 0.00	4.76 ± 0.00
OUTER NUCLEAR LAYER	Posterior													67.12 ± 2.40	67.59 ± 2.22	76.64 ± 3.72	81.40 ± 1.93	
	Peripheral															56.17 ± 2.22	65.69 ± 2.33	
BACILLARY LAYER	Posterior													4.76 ± 0.00	4.76 ± 0.00	7.14 $\pm .79$	7.82 $\pm .50$	
	Peripheral																4.76 ± 0.00	
NEUROBLASTIC LAYER	Posterior	67.59 ± 1.55	79.97 ± 3.16	92.34 ± 3.76	95.68 ± 3.51	72.35 ± 2.91	96.15 ± 2.73	98.53 ± 2.01	103.29 ± 3.01	121.38 ± 4.44	168.50 ± 4.44	172.31 ± 6.22	203.73 ± 11.81	198.97 ± 1.98				
	Peripheral	45.22 ± 2.38	60.45 ± 1.74	68.54 ± 2.48	77.11 ± 4.18	76.64 ± 2.40	59.98 ± 3.90	93.77 ± 3.55	96.15 ± 1.55	104.24 ± 1.77	134.23 ± 2.10	134.71 ± 3.82	174.22 ± 5.41	181.83 ± 3.81	182.78 ± 4.15	160.88 ± 1.70		
WHOLE RETINA	Posterior	75.21 ± 1.98	87.59 ± 3.70	99.96 ± 3.68	101.87 ± 5.05	112.81 ± 5.45	165.68 ± 4.46	163.75 ± 4.90	168.02 ± 5.16	191.07 ± 8.16	235.14 ± 6.43	239.90 ± 6.85	281.79 ± 16.15	275.13 ± 2.91	313.21 ± 8.92	265.13 ± 3.90	264.20 ± 9.31	276.49 ± 3.96
	Peripheral	48.55 ± 2.10	64.73 ± 1.90	73.78 ± 1.62	81.87 ± 4.18	90.04 ± 1.38	94.73 ± 5.14	145.65 ± 6.07	153.75 ± 2.93	152.79 ± 7.13	182.78 ± 3.11	181.42 ± 4.33	228.00 ± 6.50	240.85 ± 3.56	247.99 ± 7.91	217.52 ± 2.36	229.91 ± 4.18	219.98 ± 2.43
RETINAL $\frac{1}{3}$ VOLUME mm.	0.02	0.07	0.18	0.23	0.34	0.93	1.33	1.93	2.08	4.67	6.13	7.48	9.30	9.15	9.04	12.13	10.62	

Standard errors for the mean of each retinal layer are given

BETWEEN AGE, DEVELOPMENT OF THE RETINAL LAYERS AND RETINAL VOLUME IN THE ALBINO RAT EYE

3 day Neonatal	4 day Neonatal	5 day Neonatal	6 day Neonatal	7 day Neonatal	8 day Neonatal	9 day Neonatal	10 day Neonatal	12 day Neonatal	14 day Neonatal	16 day Neonatal	18 day Neonatal	20 day Neonatal	40 day Neonatal	50 day Neonatal	100 day Neonatal	225 day Neonatal	
25.70 ±1.45	27.61 ±1.18	27.13 ±1.24	25.70 ±1.05	22.85 ±.95	23.80 ±0.00	21.42 ±.79	23.80 ±1.74	25.23 ±.72	22.85 ±.95	27.13 ±1.74	23.32 ±2.19	24.28 ±.85	19.99 ±.63	10.00 ±1.11	10.00 ±.47	9.52 ±.71	
12.85 ±2.01	15.71 ±.72	17.14 ±1.26	18.56 ±1.11	18.09 ±.63	17.61 ±.70	19.99 ±.95	21.42 ±1.77	17.61 ±.72	18.56 ±.47	15.71 ±1.01	12.38 ±1.05	13.33 ±.95	11.90 ±1.06	6.65 ±.77	5.24 ±.47	5.71 ±.63	
22.85 ±1.18	19.99 ±.95	22.85 ±2.85	18.09 ±.63	17.14 ±1.45	15.23 ±.63	12.85 ±.72	10.00 ±.47	12.85 ±.72	10.47 ±.22	10.47 ±.63	11.42 ±.77	10.00 ±.47	6.65 ±.77	7.62 ±.77	4.76 ±.00	4.76 ±.00	
18.56 ±1.31	19.04 ±0.00	19.99 ±1.55	14.28 ±1.23	15.71 ±1.01	10.54 ±.49	9.52 ±0.00	9.52 ±0.00	10.00 ±.47	9.04 ±.47	9.52 ±.00	9.52 ±.00	9.52 ±.00	8.09 ±.72	6.19 ±.72	4.76 ±.00	4.76 ±.00	
29.51 ±2.33	28.56 ±1.23	39.98 ±3.02	31.89 ±.72	34.75 ±2.25	40.94 ±.77	39.51 ±1.01	36.65 ±5.26	52.64 ±1.49	49.98 ±1.46	55.22 ±1.26	56.64 ±2.74	70.92 ±6.52	70.92 ±1.49	53.31 ±1.70	52.84 ±2.18	57.12 ±1.87	
22.37 ±.72	24.28 ±1.50	28.08 ±1.49	23.80 ±.71	28.56 ±1.23	28.56 ±.70	32.37 ±1.55	31.89 ±1.59	35.22 ±1.26	40.46 ±1.46	33.80 ±1.31	42.36 ±1.11	43.32 ±1.65	51.41 ±2.33	48.08 ±1.65	43.79 ±1.18	42.36 ±1.53	
		146.61 ±5.93	112.34 ±2.57	98.06 ±2.15	99.48 ±2.06	65.21 ±3.25	63.78 ±4.66	57.12 ±1.74	49.98 ±1.27	47.12 ±.85	43.32 ±1.31	48.08 ±1.93	40.94 ±1.26	29.99 ±1.01	25.23 ±1.01	24.28 ±.47	
			106.62 ±3.49	88.06 ±1.62	74.73 ±2.36	66.64 ±3.40	49.03 ±.72	45.70 ±1.05	30.94 ±1.27	31.42 ±1.76	30.46 ±1.45	25.70 ±1.26	23.80 ±1.23	18.56 ±1.85	19.04 ±1.00		
		4.76 ±0.00	4.76 ±0.00	7.62 ±.77	7.82 ±.50	10.00 ±.47	11.90 ±.78	13.80 ±.47	14.28 ±0.00	11.90 ±.78	14.28 ±0.00	13.80 ±.47	12.38 ±.77	13.80 ±.47	13.80 ±1.71	10.95 ±.72	
				4.76 ±0.00	4.76 ±0.00	5.24 ±.47	7.14 ±.79	9.52 ±0.00	11.42 ±.77	11.42 ±.77	10.47 ±.63	10.47 ±.63	10.47 ±.63	10.47 ±.63	9.52 ±0.00	10.00 ±.47	
			67.12 ±2.40	67.59 ±2.22	76.64 ±3.72	81.40 ±1.93	89.49 ±1.85	85.20 ±3.20	81.40 ±2.87	70.92 ±1.49	69.50 ±3.42	64.74 ±2.57	65.21 ±1.88	61.40 ±2.87	53.79 ±1.01	43.32 ±1.53	38.08 ±1.00
				56.17 ±2.22	65.69 ±2.33	68.07 ±1.24	73.30 ±3.18	67.59 ±1.85	69.97 ±1.74	52.36 ±2.83	50.93 ±1.88	48.08 ±2.40	47.60 ±2.00	43.79 ±1.98	29.04 ±1.31	31.89 ±1.24	
		4.76 ±0.00	4.76 ±0.00	7.14 ±.79	7.82 ±.50	10.95 ±.72	11.90 ±.78	24.28 ±.56	29.51 ±1.38	32.37 ±1.38	31.42 ±1.05	31.42 ±1.26	36.18 ±1.62	30.94 ±1.06	32.84 ±1.11	25.23 ±1.24	
				4.76 ±0.00	8.09 ±.72	8.09 ±1.01	15.71 ±.72	19.52 ±1.31	23.80 ±.71	23.32 ±1.50	22.85 ±.95	28.08 ±2.29	23.32 ±1.31	22.85 ±.95	19.04 ±.70		
03.73 ±1.81	196.97 ±1.98																
74.22 ±5.41	181.83 ±3.81	182.78 ±4.15	160.88 ±1.70														
81.79 ±6.15	275.13 ±2.91	313.21 ±8.92	265.13 ±3.90	264.20 ±9.31	276.49 ±3.96	249.43 ±4.44	243.23 ±3.54	267.52 ±3.93	250.37 ±2.57	253.71 ±8.00	244.19 ±3.69	265.13 ±4.43	251.81 ±5.95	198.49 ±8.97	185.65 ±4.92	169.94 ±3.23	
28.00 ±6.50	240.86 ±3.56	247.99 ±7.91	217.52 ±2.36	229.91 ±4.18	219.98 ±2.43	218.00 ±4.90	218.00 ±7.60	204.68 ±3.40	214.67 ±3.81	177.55 ±5.50	180.40 ±5.19	178.03 ±5.27	183.25 ±7.49	162.31 ±4.51	133.76 ±2.26	132.80 ±4.07	
7.48	9.30	9.15	9.04	12.13	10.62	11.67	10.05	12.27	9.95	8.77	9.32	9.61	9.52	9.23	8.78	8.75	

TEXT - FIGURE 1

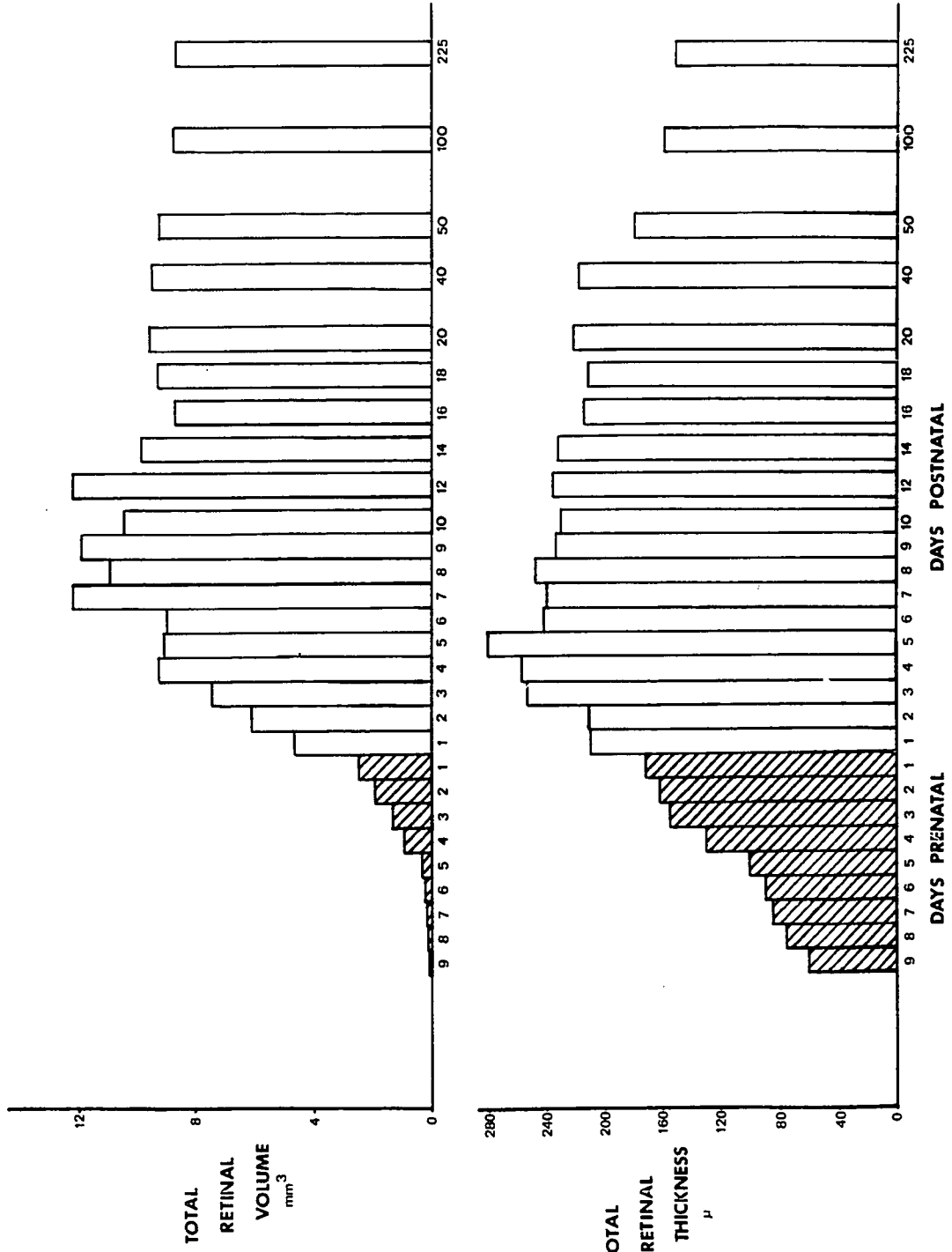
The changes, during development, in thickness of the retinal layers at the posterior of the retina are shown. The bars representing prenatal days are shaded.

TEXT - FIGURE 2

The changes, during development, in thickness of the retinal layers at the periphery of the retina are shown. The bars representing prenatal days are shaded.

TEXT - FIGURE 3

The changes, during development, in total thickness of the retina and total retinal volume are shown. The pigment epithelium has been excluded in both cases. The bars representing prenatal days are shaded.



to about 170μ , its maximum thickness on the 225th postnatal day (Text-Fig. 3). The thickness of each of the retinal layers present in the adult retina also declines from maxima reached at varying times for the different layers (Text-Figs. 1 and 2). Considering each of the retinal layers individually, it is evident that the nerve fibre, inner plexiform and outer plexiform layers all continue to increase in thickness after the adjacent nuclear layers have reached their maximum width and have begun to thin. The ganglion cell and outer nuclear layers both increase in thickness after their first appearance but the inner nuclear layer begins to decrease in thickness as soon as it is established (Text-Figs. 1 and 2). Comparing Text-Fig. 1 with Text-Fig. 2 it is obvious that the peripheral retina always lags behind the posterior retina in development and the retinal layers peripherally never attain the thickness that they do posteriorly. Finally the results of both the photomicrographic study of the developing rat retina (Figs. 1-20) and the quantitative analysis (Table 1, Text-Figs. 1, 2 and 3) indicate that the transient layer of Chievitz (Chievitz, 1887) is not present within the rat retina during development.

2. Development of the Retinal Pigment Epithelium, Choriocapillaris and Bruch's Membrane.

15th day of gestation (Stage 26-Christie 1964) (Fig. 21)

On the 15th day of gestation, or 6 days before birth, the typical pigment epithelial cell is quite immature (Fig. 21). It is polygonal with a large nucleus, surrounded by a narrow rim

Figure 21 Electron micrograph of pigment epithelium (PE), the future site of Bruch's membrane (B), and choriocapillaris (Cc) of a rat at 15 days of gestation. Note the continuous nature of the endothelium of the choriocapillaris and the small tight junction (arrow). The basement membrane of the pigment epithelium (Bm) is obvious. Fibroblast processes (FP) are present within Bruch's membrane. The pigment epithelial cell at this stage is roughly polygonal in shape. The direction of the choroid is indicated by the encircled arrow. Primary fixative: glutaraldehyde (X11,880)

Figure 22 Electron micrograph of the apical region of a pigment epithelial cell at 16 days of gestation. Pro-pigment granules (PP) and a Golgi zone (G) are visible. Lateral cell junctions (J) are forming. The optic vesicle is closed. The direction of the choroid is indicated by the encircled arrow. Primary fixative: glutaraldehyde (X11,880)

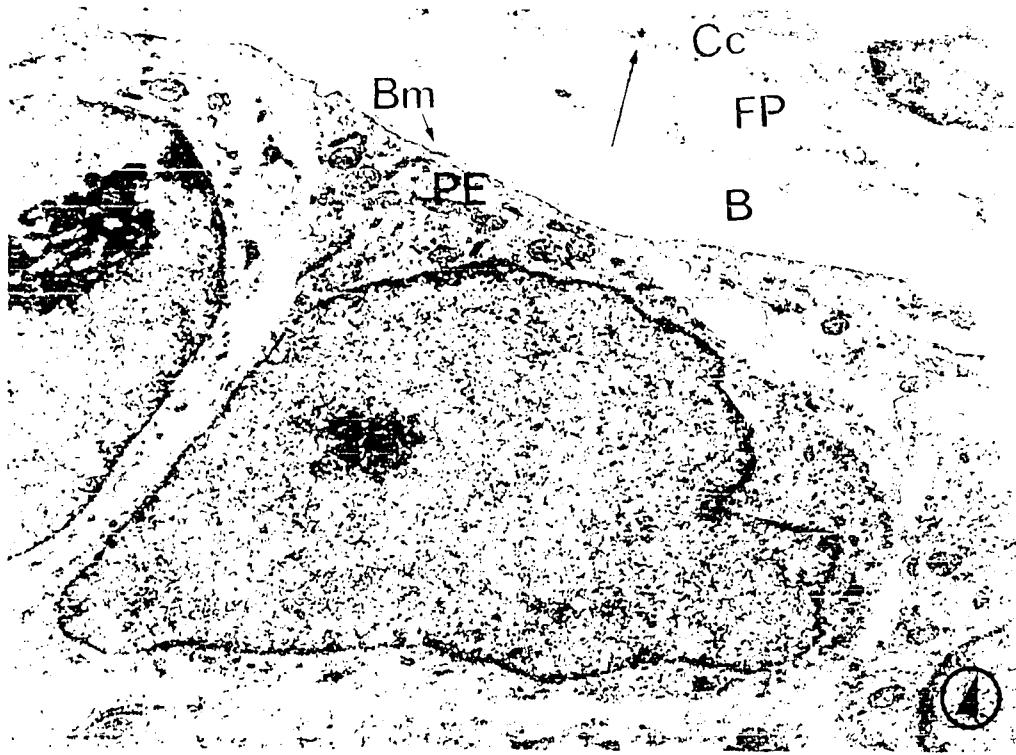
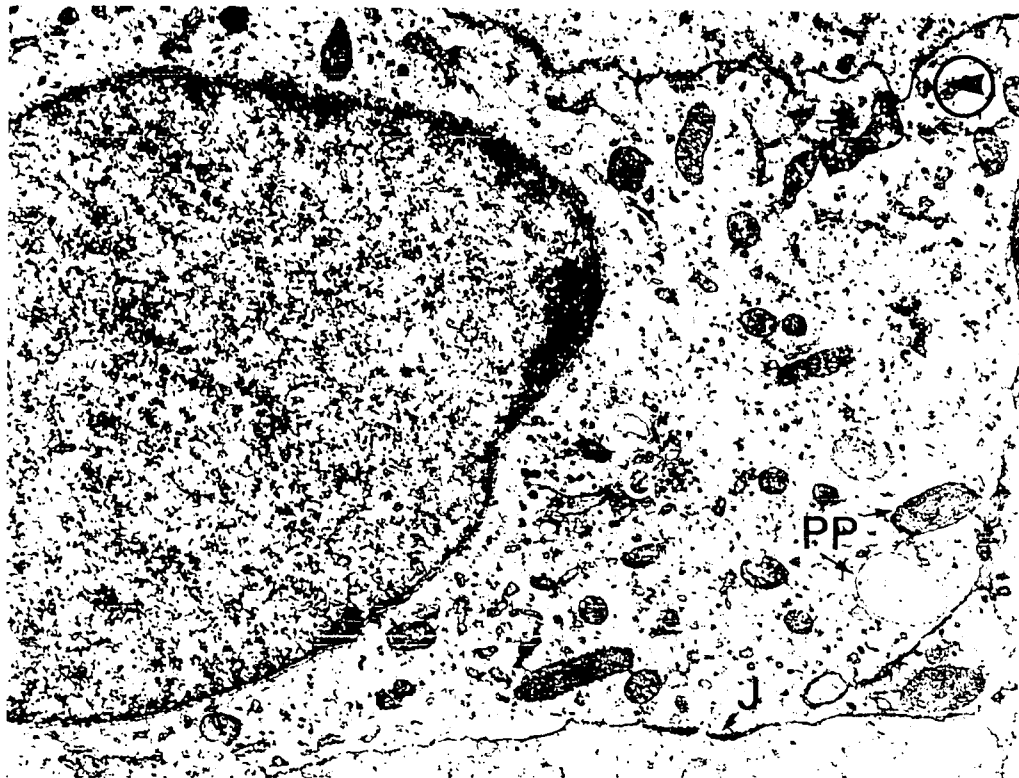


FIGURE 21



of cytoplasm containing many polysomes and a few scattered mitochondria. The small amount of nuclear chromatin is clumped at the edge of the uni-nucleolar nucleus. The apical (or inner) and basal (or outer) borders of the cell show only slight infoldings and the lateral cell margins are almost smooth. No cell junctions are present as yet at the lateral borders. A dense, complete, epithelial basement membrane layer, about 40 μ thick, is present running parallel to the base of the pigment epithelium. This is the first layer of Bruch's membrane to appear. Scattered between the pigment epithelium and the choriocapillaris are processes of fibroblasts and some fibrillar material. The choriocapillaris at this stage consists of thin walled capillaries. The endothelial cytoplasm is continuous and is rich in polysomes. As yet there is no basement membrane underlying the endothelial cells, which are joined by small tight junctions.

16th day of gestation (Stage 28-Christie 1964) (Figs. 22 and 23)

At 5 days before birth the typical pigment epithelial cell shows a marked change in shape and organelle content (Figs. 22 and 23). The cell is now more rectangular in shape with its long axis at right angles to Bruch's membrane. All the cell surfaces are relatively smooth although some lateral interdigitation is seen. Within the cell, polysomes remain numerous, rough-surfaced endoplasmic reticulum is forming and a supra-nuclear Golgi zone is now present. The nucleus is more oval in shape, lies in the long axis of the cell and contains chromatin of granular

Figure 23 Pigment epithelium of a rat 5 days before birth (16 days of gestation). Note the pro-pigment granules (PP) and the developing cilium (Ci). Future photoreceptor cells are seen at the lower right, (Ph). The direction of the choroid is indicated by the encircled arrow.

Primary fixative: glutaraldehyde (X21,600)

Figure 24 Electron micrograph of choriocapillaris (Cc) and pigment epithelium (PE) at 17 days of gestation. Note the Golgi zone (G) and the abundant granular endoplasmic reticulum in the endothelial cell. A process of a fibroblast (F) and scattered fine filaments are visible within Bruch's membrane. The basal surface of the pigment epithelium and the epithelial basement membrane (Bm) layer are visible to the right. The direction of the choroid is indicated by the encircled arrow.

Primary fixative: glutaraldehyde (X 32,400)




FIGURE 23

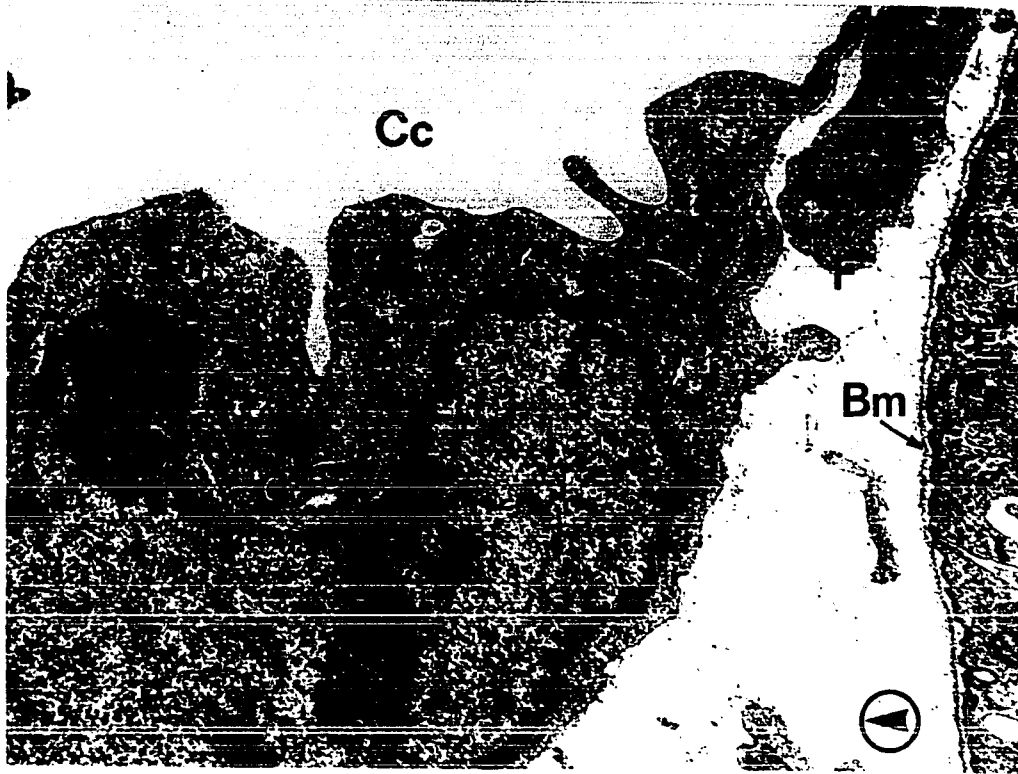


FIGURE 24

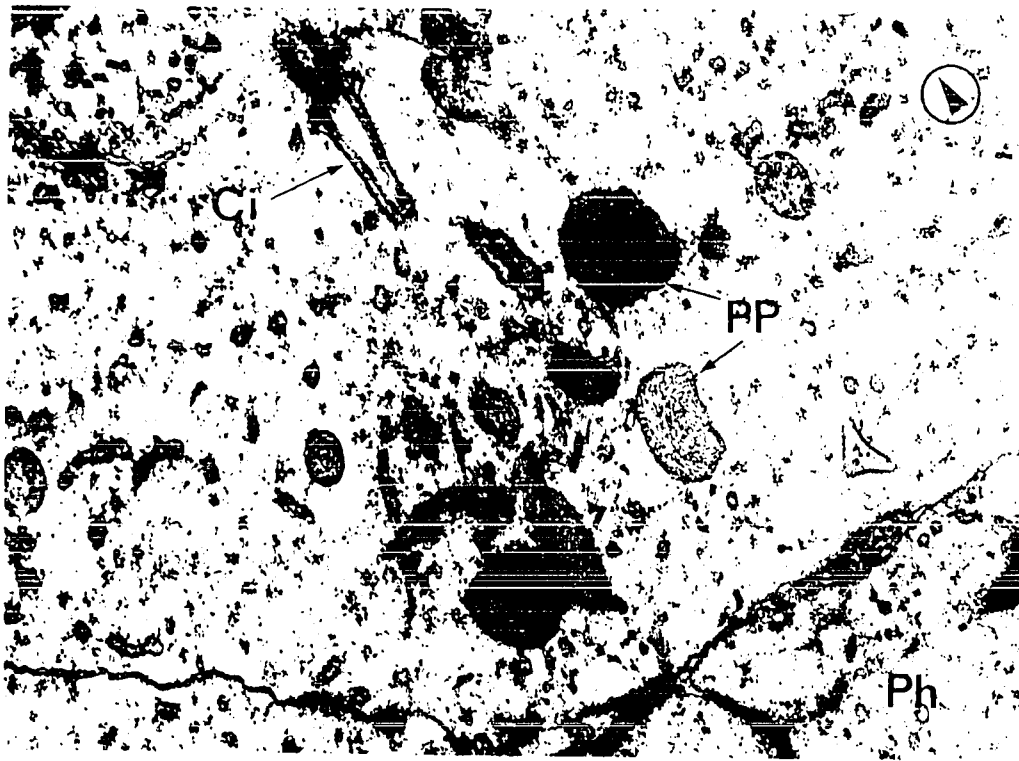


FIGURE 23

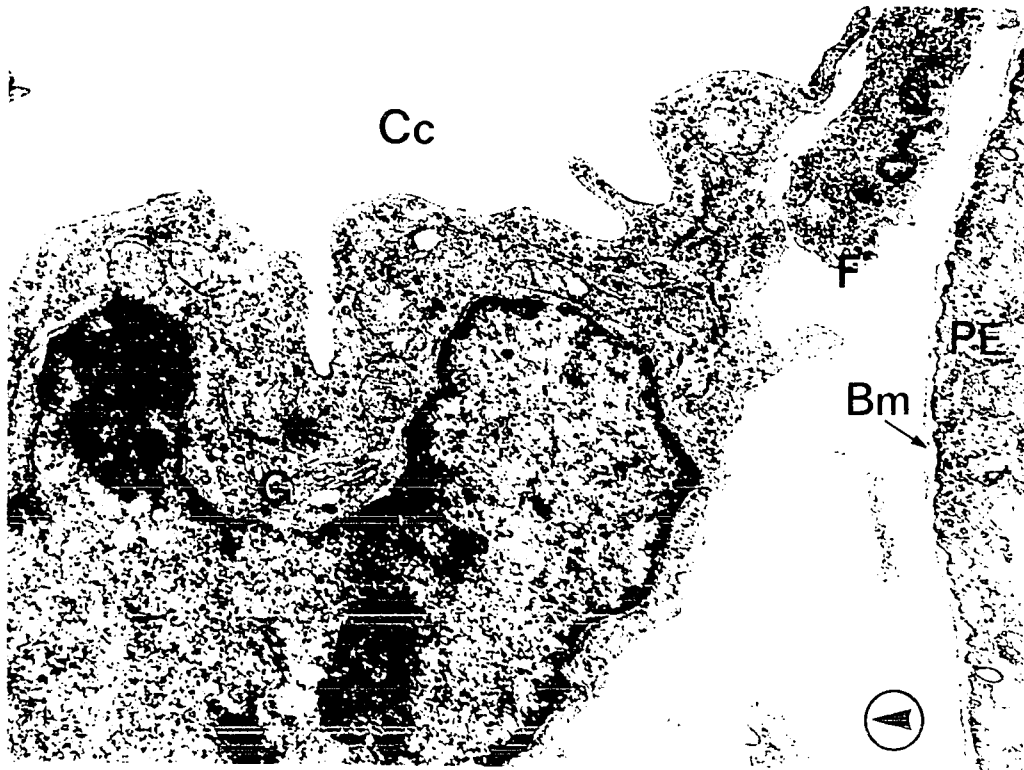


FIGURE 24

appearance concentrated at the nuclear border (Fig. 22).

Pro-pigment granules concentrated in the apical region of the cell are first visible at 5 days before birth. The internal lamellae within some of the pro-pigment granules are very loosely arranged, while in others the lamellae are tightly packed. A distinct peripheral membrane forms the outer border of each pro-pigment granule (Figs. 22 and 23). Lateral cell junctions also make their first appearance at 5 days before birth and are first seen as thickenings of contiguous cell membranes in the apical region of the cell (Fig. 22). Occasionally a cilium can be seen developing within the apical cytoplasm of the epithelial cell (Fig. 23).

17th day of gestation (Stage 30-Christie 1964) (Fig. 24)

By the 4th day before birth the endothelial cells of the choriocapillaris are well developed. The endothelial cytoplasm contains many mitochondria, polysomes and rough-surfaced endoplasmic reticulum. A Golgi zone is usually present near the irregularly shaped nucleus. The nuclei of the endothelial cells contain dense marginated chromatin and are usually located on the choroidal side of the capillary. The endothelial basement membrane layer is present in isolated areas at this time, but does not as yet form a complete layer. Fibrillar material is accumulating in the gap between the endothelium and the pigment epithelium, at the site of formation of Bruch's membrane.

18th day of gestation (Stage 32-Christie 1964) (Fig. 25)

On the 18th day of gestation (3 days before birth)

Figure 25 The pigment epithelial (PE) photoreceptor (PH) junction is shown from a rat at 18 days of gestation. Apical epithelial processes (AP) are forming. The series of cell junctions forming the external limiting membrane (ELM) are visible (arrows). A dividing photoreceptor cell is present in the lower left. Pro-pigment granules and endoplasmic reticulum remain numerous in the epithelial cell. A lateral cell junction between epithelial cells (J) is visible. The direction of the choroid is indicated by the encircled arrow.

Primary fixative: glutaraldehyde (X27,000)

Figure 26 Electron micrograph showing the pigment epithelial (PE) photoreceptor (PH) junction at the 20th day of gestation. The apical epithelial processes (AP) are now well advanced and are beginning to enclose the developing photoreceptor inner segments (IS). Pro-pigment granules (PP) are numerous within the epithelial cytoplasm. Some of the pro-pigment granules have lost their outer membrane and may be breaking up. A lateral cell junction (J) joining adjacent epithelial cells is visible close to the photoreceptor pigment epithelial junction. A cilium (Ci) in the early stages of development is seen within a photoreceptor cell. The direction of the choroid is indicated by the encircled arrow.

Primary fixative: glutaraldehyde (X20,736)



FIGURE 25

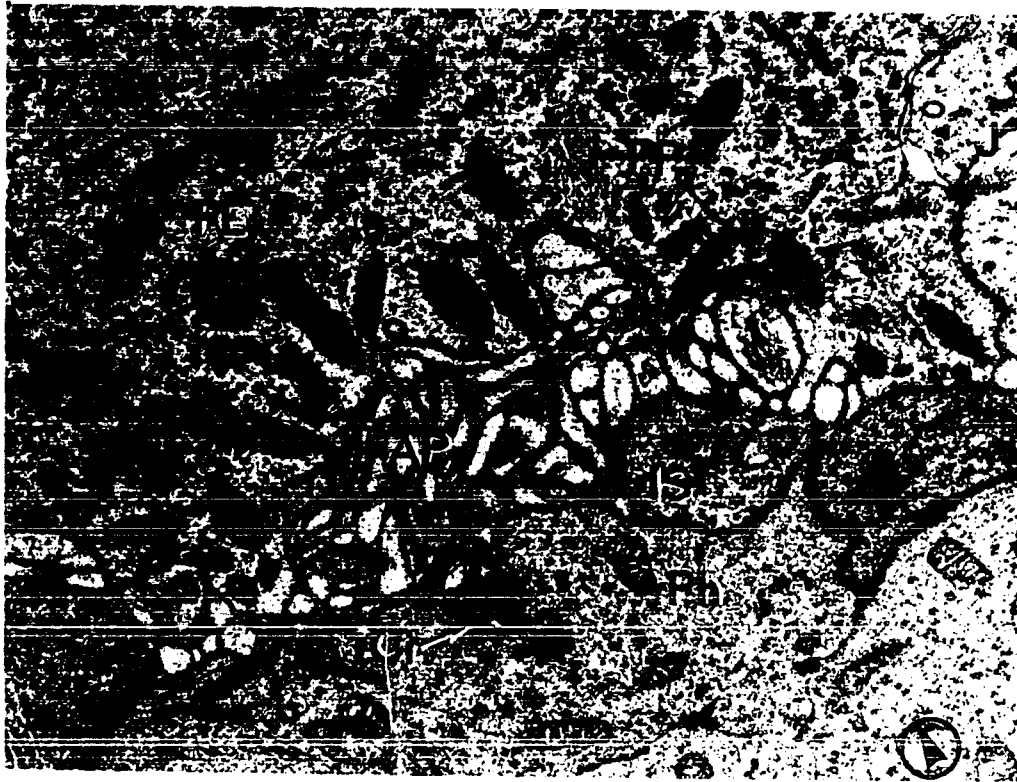


FIGURE 26




FIGURE 25

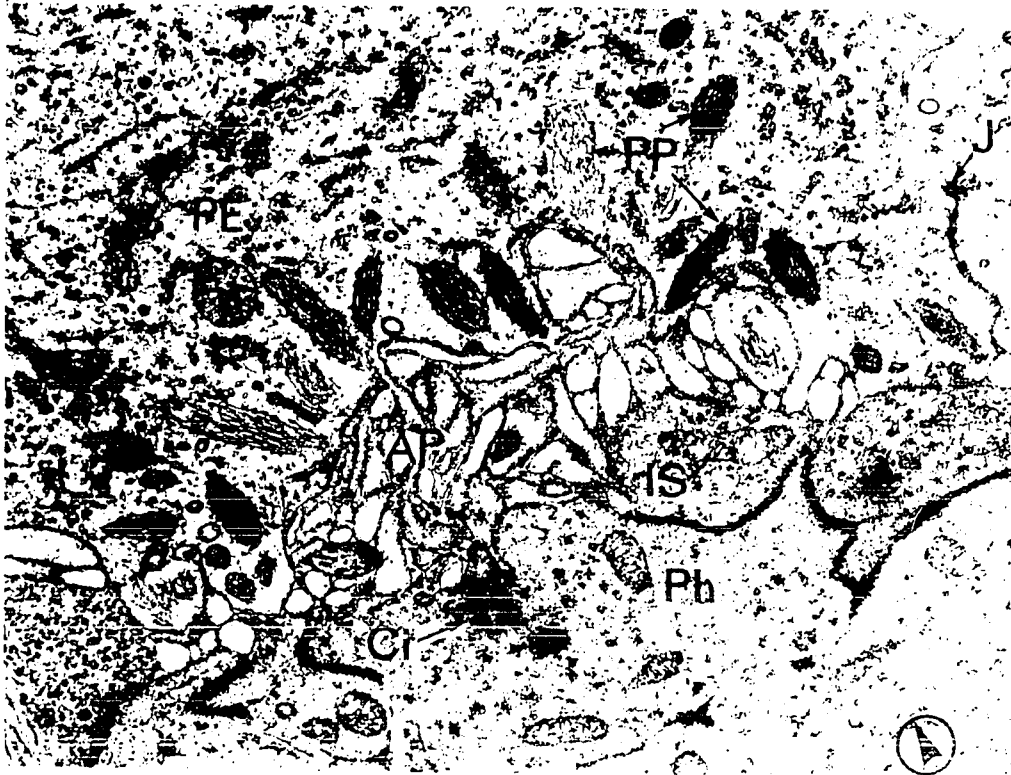

FIGURE 26

processes can be seen for the first time, forming at the apical epithelial surface. The epithelial processes as they are formed lie immediately adjacent to the developing inner segments of the photoreceptors, which have advanced slightly beyond the external limiting membrane. Pro-pigment granules of varying shapes and sizes are concentrated in the apical, epithelial cytoplasm and its processes, but mitochondria are scarce in this region. Polysomes remain numerous throughout the epithelium and a number of scattered, dense, osmiophilic bodies also can be seen. The lateral cell junctions now are more distinct and are located further choroidally than when they first appeared. The future photoreceptor nuclei are still undergoing mitosis at this time.

20th day of gestation (Fig. 26)

On the 20th day of gestation the apical processes of the pigment epithelial cells are well advanced and remain in intimate contact with the globular inner segments as the latter enlarge. Pro-pigment granules are still numerous in the apical epithelial cytoplasm. In some of the pro-pigment granules the internal lamellae show a distinct parallel arrangement, but in others the lamellae are loosely arranged and are no longer surrounded by an enclosing membrane. The pro-pigment granules without a distinct outer membranous boundary may be in the process of dissolution. None of the pro-pigment granules are becoming pigmented. The lateral epithelial cell junctions are now more prominent and are located still further choroidally as they mature.

21st day of gestation (Figs. 27 and 28)

On the 21st and last fetal day the pigment epithelial

Figure 27 Electron micrograph showing the pigment epithelium (PE), Bruch's membrane (B) and choriocapillaris (Cc) from a 21-day-old fetal rat. Fenestrae are present in the endothelial lining of the choriocapillaris (arrows). More collagen fibrils are present in Bruch's membrane and an endothelial basement membrane layer is forming. Pro-pigment granules (PP) in various stages of formation and break-up are numerous within the epithelial cytoplasm. Both rough-surfaced endoplasmic reticulum and smooth membranes in parallel array can be seen within the epithelial cytoplasm. The direction of the choroid is indicated by the encircled arrow.

Fixative: osmium tetroxide (X21,600)

Figure 28 The basal portion of the pigment epithelium from a 21-day-old fetal rat is shown. Basal infoldings (BI) of the pigment epithelium in early stages of formation are clearly visible. Tight junctions (TJ) between adjacent endothelial cells are present, but the basement membrane (Bm) of the endothelium is still incomplete. An endothelial cell process, projecting into Bruch's membrane is seen (arrow). A meshwork of collagen fibers has formed within Bruch's membrane but the central lamina densa is still absent. The direction of the choroid is indicated by the encircled arrow.

Fixative: osmium tetroxide (X21,600)




FIGURE 27



FIGURE 28

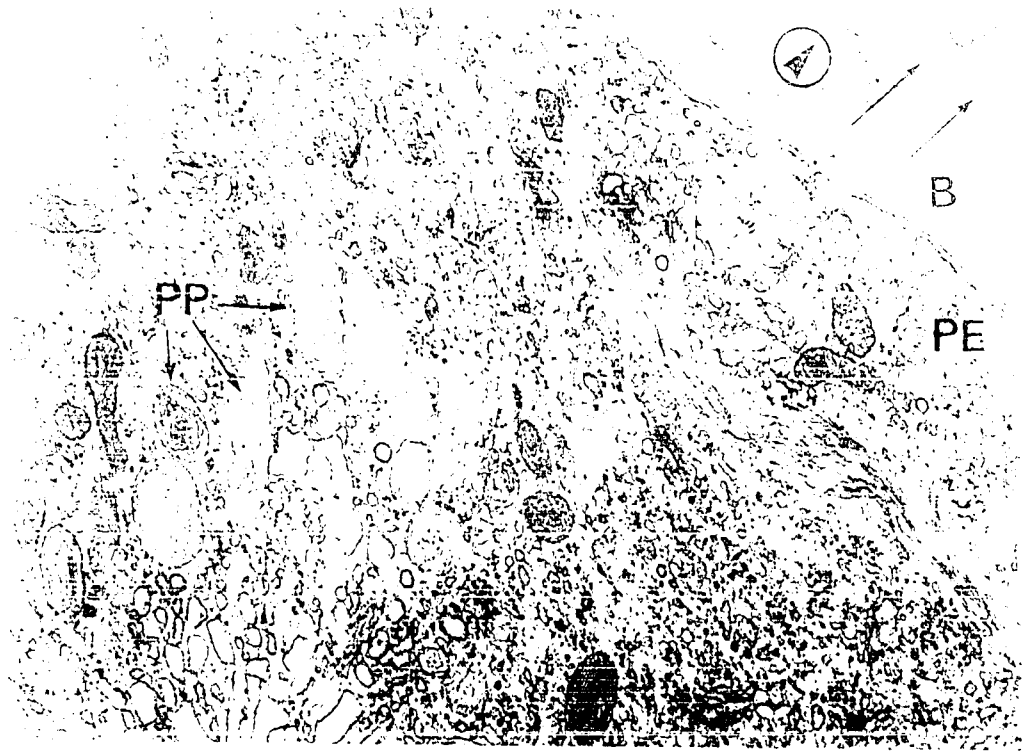
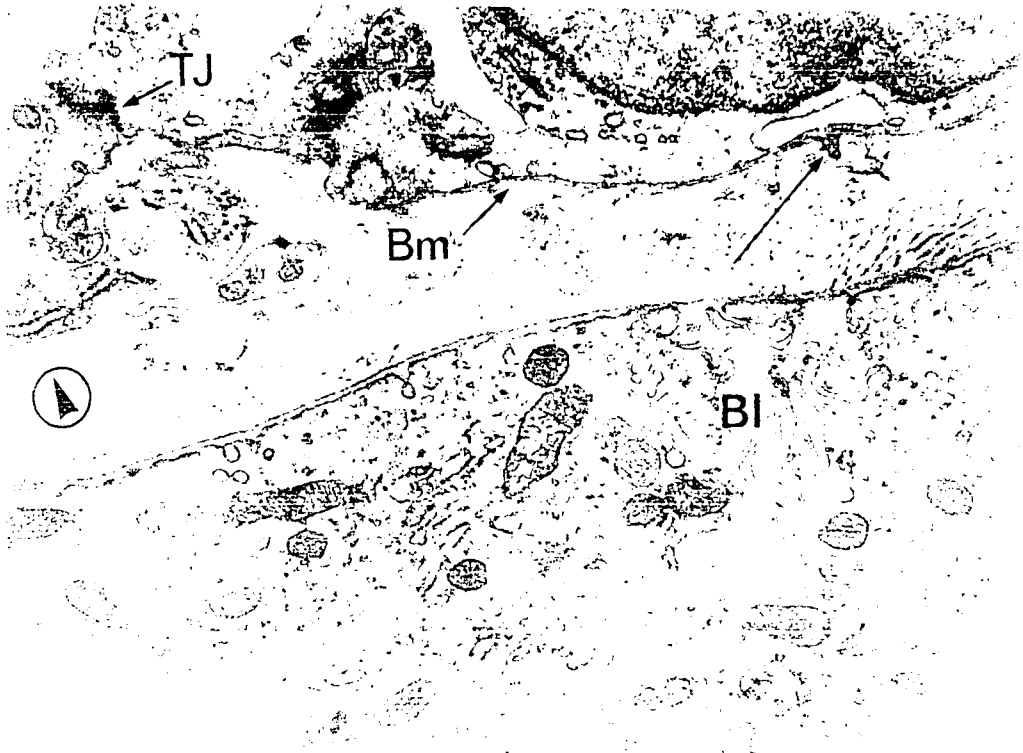


FIGURE 27



cytoplasm contains large numbers of organelles and inclusion bodies. The pro-pigment granules are numerous in the apical cytoplasm and their morphology varies widely (Fig. 27). In many of the granules the tightly packed internal lamellae are no longer surrounded by an enclosing membrane. Numerous vesicles are also seen apically and some are arranged in linear fashion perpendicular to the inner epithelial surface (Fig. 27). However, Matsusaka (1967) has suggested that the linear arrangement of vesicles in this manner in the pigment epithelium is an artifact of unsuitably applied osmium tetroxide fixation. Ribosomes are extremely plentiful--both attached to membranes and forming polysomes. Masses of smooth-surfaced membranes, in parallel formation, also are obvious in the central region of the epithelial cell (Fig. 27). The apical surface displays many processes at this stage and the basal surface of the cell is beginning to show some infolding and vesicle accumulation. The endothelial basement membrane of the choriocapillaris is now almost complete, but it is not as prominent as the basement membrane of the pigment epithelium (Fig. 28). Within Bruch's membrane, collagen fibrils are now much more numerous and form a three dimensional mesh. Processes of fibroblasts are still present between the choriocapillary endothelium and the pigment epithelium. Occasional endothelial cell processes project through the endothelial basement membrane layer into Bruch's membrane (Fig. 28). The choriocapillary endothelium adjacent to the pigment epithelium now shows occasional fenestrae (Figs. 27 and 28)

5th postnatal day (Figs. 29 and 30)

After birth both the basal and apical surfaces of the pigment epithelium continue to become more tortuous (Figs. 29, 31, 32, 33 and 34). On the 5th neonatal day, increasingly longer and thinner apical epithelial processes occupy the entire inner epithelial surface (Fig. 29). Throughout their development the apical processes remain immediately adjacent to the enlarging inner segments. Unlike the apical processes, which form simultaneously over the entire inner epithelial border, the infolding of the basal surface are first formed in isolated regions (Fig. 29). These areas then gradually enlarge to cover almost the entire basal surface. The remaining pro-pigment granules, still located apically, are now fusiform in shape and mostly lie parallel to the apical processes (Figs. 29 and 30). Their internal structure is now more regular and consists of numerous longitudinal, parallel membranes which display a distinct periodicity. None of the internal lamellae show any evidence of melanin deposition (Fig. 30).

As the basal infoldings form, the mitochondria and smooth and rough-surfaced endoplasmic reticulum, which were dispersed throughout the epithelial cytoplasm become confined to a central region along with the epithelial nuclei (Fig. 29). Polysomes and occasional osmiophilic bodies remain randomly arranged within the epithelium.

The final component of Bruch's membrane to appear is the centrally located dense layer. It is first seen on the 5th neonatal day and appears as isolated segments of densely staining material separating the collagen fibers into inner and outer bands (Fig. 29).

1000

Figure 29 Electron micrograph showing Bruch's membrane (B) and the pigment epithelium (PE) at 5 days after birth. The central discontinuous lamina densa of Bruch's membrane can now be seen (arrows). The basal surface of the pigment epithelium has become infolded (Bl) in discrete areas. The apical epithelial processes (AP) are now well developed. Within the epithelial cytoplasm the remaining pro-pigment granules (PP) are fusiform in shape and mitochondria, rough-surfaced endoplasmic reticulum and the occasional osmiophilic body can be seen. The direction of the choroid is indicated by the encircled arrow.

Primary fixative: glutaraldehyde (X14,256)

Figure 30 At higher magnification, the longitudinal arrangement of the internal lamellae of the epithelial pro-pigment granules is clearly visible. Note also the periodicity of the contained lamellae and the absence of pigment deposition. Polysomes are plentiful in the surrounding epithelial cytoplasm. The direction of the choroid is indicated by the encircled arrow.

Primary fixative: glutaraldehyde (X47,520)




FIGURE 29


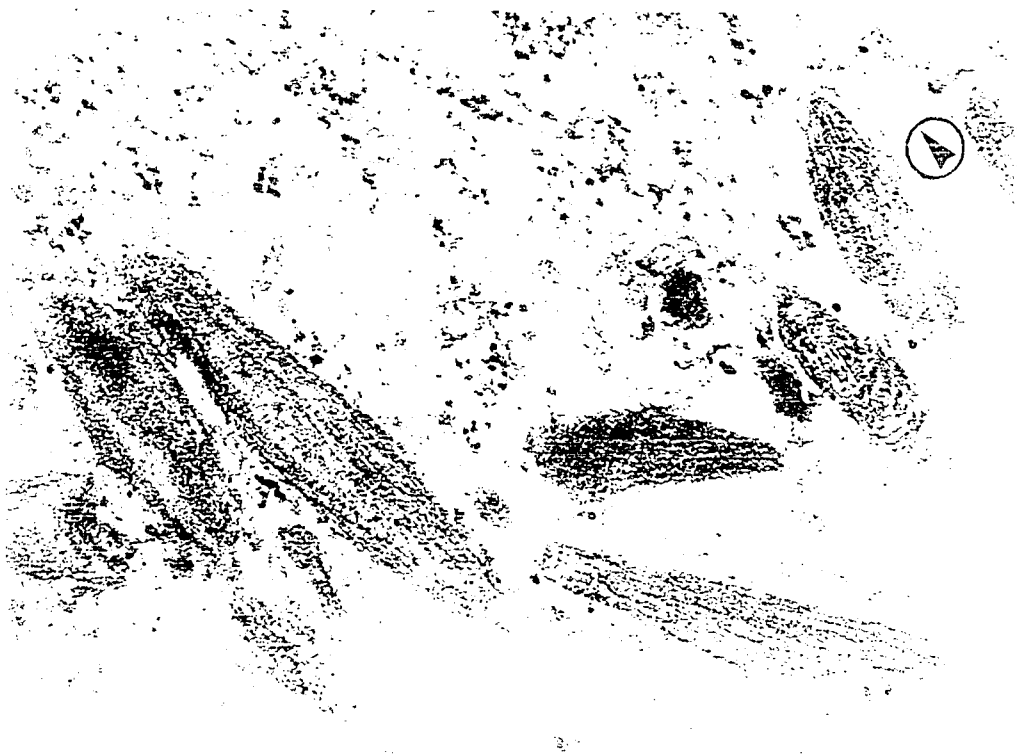


FIGURE 30



FIGURE 22



8th postnatal day (Fig. 31)

As previously noted, when the apical processes of the pigment epithelium first appear on the 18th fetal day (Fig. 25) they are contiguous with the distal surfaces of the developing photoreceptor inner segments. As the inner segments lengthen, the apical epithelial processes insinuate themselves between them until, by the 8th neonatal day, they surround the enlarging inner segments.

9th postnatal day (Fig. 32)

On the 9th neonatal day the choriocapillaris, Bruch's membrane and the pigment epithelium are in an almost mature condition. The tortuous basal infoldings now cover almost the entire basal surface. The fusiform pro-pigment granules are fewer in number and are strictly confined to the apical region of the epithelium. Although no pigmentation of the granules has taken place, they often appear denser than before, perhaps due to compression of the internal lamellar structure of the granules. The lateral margins of the epithelial cells interdigitate slightly and the prominent cell junctions have receded further from the apical zone. Polysomes are still scattered throughout the cell cytoplasm while the smooth and rough-surfaced endoplasmic reticulum, osmiophilic bodies, mitochondria and Golgi zones are confined to central regions.

Bruch's membrane is complete on the 9th neonatal day and is composed of five distinct layers: the basement membrane of the pigment epithelium; the basement membrane of the endothelium; and a discontinuous central lamina densa separating an inner and an outer collagenous band. The choriocapillary endothelium bordering

Figure 31 Electron micrograph showing the pigment epithelial (PE) photoreceptor (Ph) junction at 8 days after birth. The apical processes (AP) of the pigment epithelium enclose the growing photoreceptor inner segments (IS). The external limiting membrane (ELM) is now well developed (arrows). The direction of the choroid is indicated by the encircled arrow.

Primary fixative: glutaraldehyde (X20,736)

Figure 32 Electron micrograph showing the pigment epithelium (PE), Bruch's membrane (B) and choriocapillaris (Cc) on the 9th postnatal day. The choriocapillary endothelium is now very thin and highly fenestrated. All five layers of Bruch's membrane as seen in the adult are present and almost the entire basal surface of the pigment epithelium is now infolded. The lateral junctions (J) between epithelial cells are well established. Pro-pigment granules (PP) can still be identified in the apical epithelial cytoplasm. The direction of the choroid is indicated by the encircled arrow.

Primary fixative: glutaraldehyde (X9, 072)




FIGURE 31




FIGURE 32


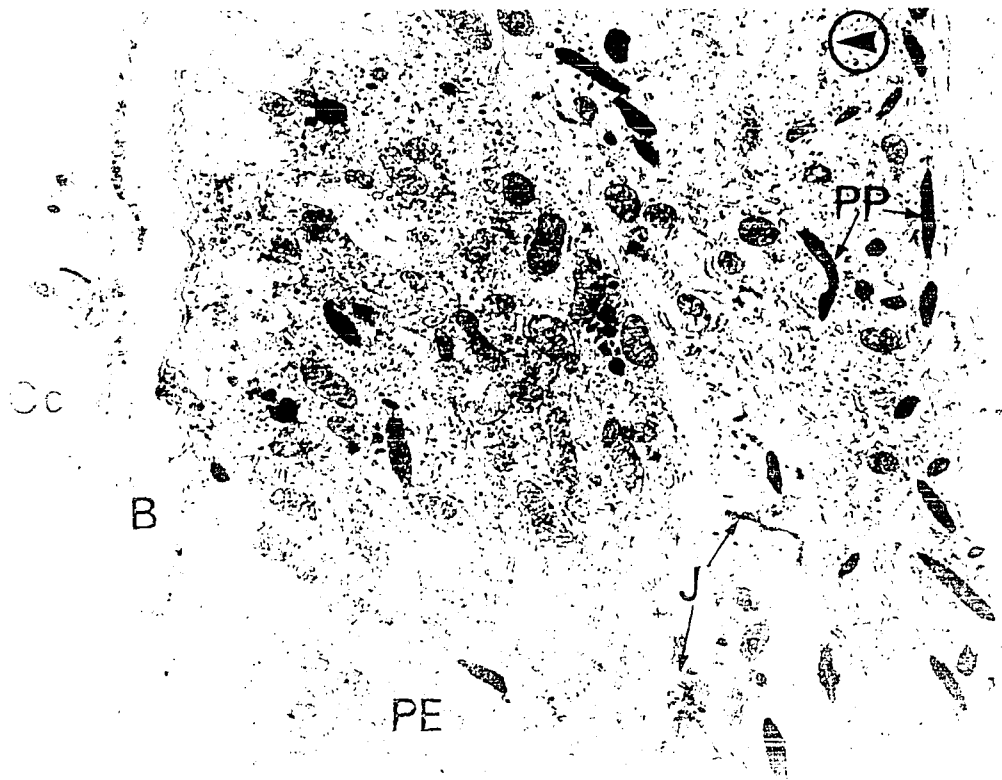


FIGURE 51



Bruch's membrane at this stage is noticeably fenestrated and extremely thin.

14th postnatal day (Figs. 33 and 34)

The most significant feature to appear on the 14th postnatal day, is the lamellated inclusion body of the pigment epithelium (Fig. 33). At this time the photoreceptor outer segments are well formed and closely enclosed by numerous thin, apical, epithelial processes (Fig. 34). Pro-pigment granules are still visible within the apical processes and cytoplasm of the pigment epithelium (Fig. 34).

3. A Comparative Study of the Development of the Hyaloid and Retinal Capillaries.

Hyaloid Capillaries

16th day of gestation (Stage 28-Christie 1964) (Figs. 35 and 36)

The hyaloid capillaries on the 16th day of gestation are well established. The endothelial wall of the capillary is continuous and in most cases quite thick (Fig. 35). The cytoplasm of the endothelial cells is rich in mitochondria and in ribosomes, both grouped as polysomes and attached to membranes. Tight junctions connect the endothelial cells and several endothelial cells may be joined to enclose the capillary lumen (Figs. 35 and 36). The nuclei of the endothelial cells are often very irregular in shape and some endothelial cells still undergo mitosis at this time (Fig. 35). Dense fibrillar material is present on the external surface of the endothelial cells, (Figs. 35 and 36) but is not

Figure 33 The basal portion of a pigment epithelial cell at 14 postnatal days is shown. The basal infolding (B1) now cover the entire basal surface. A lamellar inclusion body (LB) is seen for the first time, within the epithelial cytoplasm. The direction of the choroid is indicated by the encircled arrow.

Primary fixative: glutaraldehyde (X21,600)

Figure 34 Electron micrograph showing the apical portion of the pigment epithelial cell at 14 postnatal days. Pro-pigment granules (PP) are still numerous in the apical epithelial cytoplasm and the apical epithelial processes (AP) now enclose the lamellated profiles of photoreceptor outer segments (OS). The direction of the choroid is indicated by the encircled arrow.

Primary fixative: glutaraldehyde (X21,600)



FIGURE 33




FIGURE 34




FIGURE 35

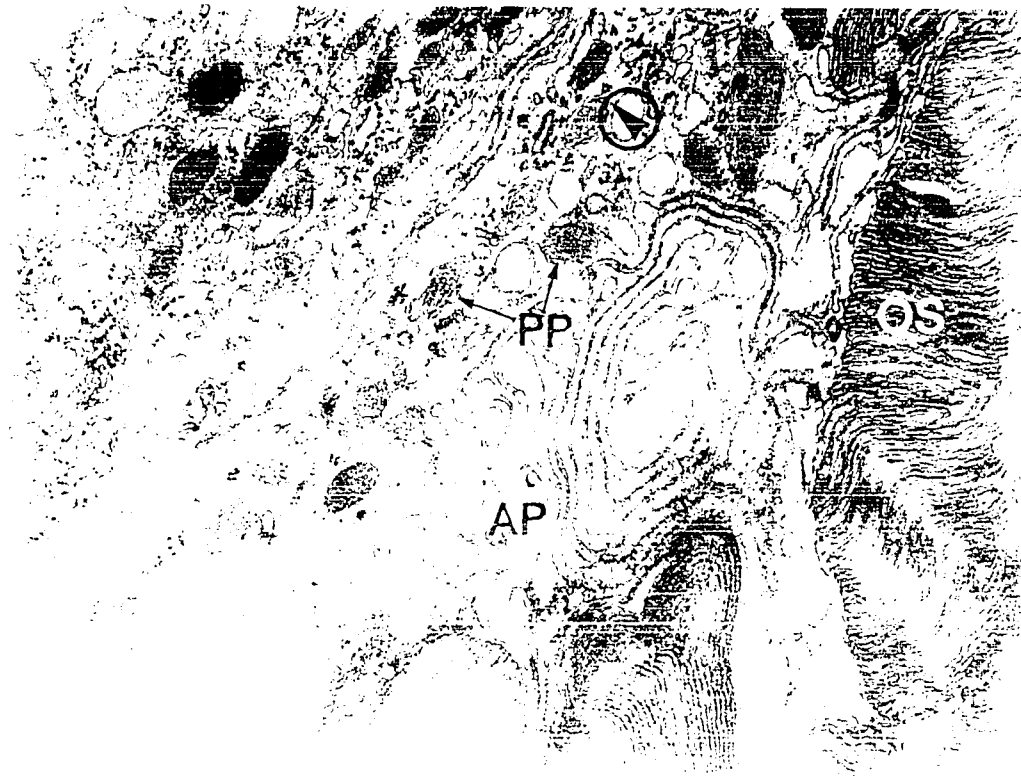

Figure 35 Electron micrograph showing a hyaloid capillary within the vitreous chamber of the eye of a rat on the 16 day of gestation. Tight junctions (TJ) join the cells of the continuous endothelium forming the capillary wall. The endothelial cytoplasm contains numerous polysomes and granular endoplasmic reticulum. A mid-body (MB) is present indicating the end of a mitotic division of an endothelial cell. Fine granular and fibrillar material is visible adjacent to the outer endothelial plasma membrane.

Primary fixative: glutaraldehyde (X7,560)

Figure 36 Electron micrograph showing a hyaloid capillary on the surface of the lens capsule (LC) on the 16th day of gestation. Polysomes and rough endoplasmic reticulum are plentiful within the endothelial cytoplasm. The capillary appears to be joined to the capsule by fibrillar material (F). Disorganized fibrillar material is also present around the capillary. Endothelial processes (EP) protrude both into the lumen of the capillary and into the vitreous.

Primary fixative: glutaraldehyde (X9,180)




FIGURE 35

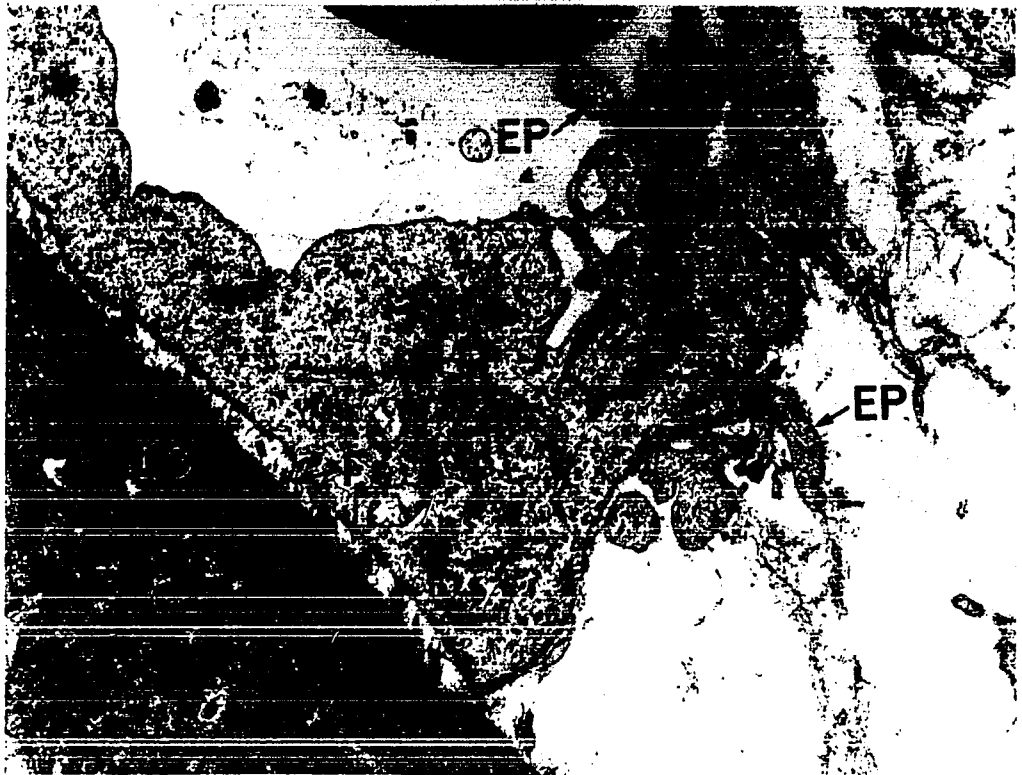



FIGURE 36



FIGURE 55



yet definite enough to constitute a basement membrane. The capillaries of the tunica vasculosa lentis are closely adherent to the lens capsule and appear to be bound to it by fibrillar material similar to that of the capsule (Fig. 36).

19th day of gestation (Fig. 37).

At this stage the hyaloid capillaries have become more tubular in shape and their walls thinner. Most of the endothelial cells forming the inner layer of the capillary wall overlay with each other although in some cases the endothelial cells abut directly, end to end. The endothelial cytoplasm is still rich in ribosomes and mitochondria. The pericytes, located external to the endothelial cells are similar in appearance to the endothelial cells, although their cytoplasm appears darker. The fibrillar material surrounding the capillary is now more condensed and in some places forms a distinct basement membrane layer.

21st day of gestation (Figs. 38 and 39).

By the last day of gestation, the hyaloids lying on the lens exhibit an extremely thin wall facing the lens capsule (Fig. 38). The endothelium remains continuous without fenestrations and is surrounded by a narrow basement membrane layer (Fig. 38). The endothelium of the hyaloid capillaries lying on the inner surface of the retina is also thin and invested by a fine basement membrane layer (Fig. 39). Pericytes processes do not intrude between the capillary endothelium and the lens (Fig. 38), or the retina (Fig. 39). In some areas, the hyaloid capillaries lying on the retina and the retinal capillaries are found in close

Figure 37 Hyaloid capillaries, near the surface of the inner retina (R) 2 days before birth (19th day of gestation), are shown. Pericytes (P) are present helping to form the wall of both capillaries. The basement membrane (Bm) material surrounding the capillary wall is now more definite but still discontinuous. Polysomes remain plentiful within the endothelial cytoplasm. The inner wall of both capillaries is formed by several endothelial cells joined by tight junctions (TJ).
Primary fixative: glutaraldehyde (X7,265)

Figure 38 The endothelium of a hyaloid capillary, located on the surface of the lens capsule (LC) on the 21st day of gestation, is shown. The endothelium lying on the lens is extremely thin but is continuous and without fenestrations. A narrow but complete basement membrane (Bm) ensheaths the endothelium. Fibrillar material occupies the narrow gap between the outer lamina of the lens capsule and the capillary wall. No pericytes intrude between the lens and the capillary.
Fixative: osmium tetroxide (X21,600)

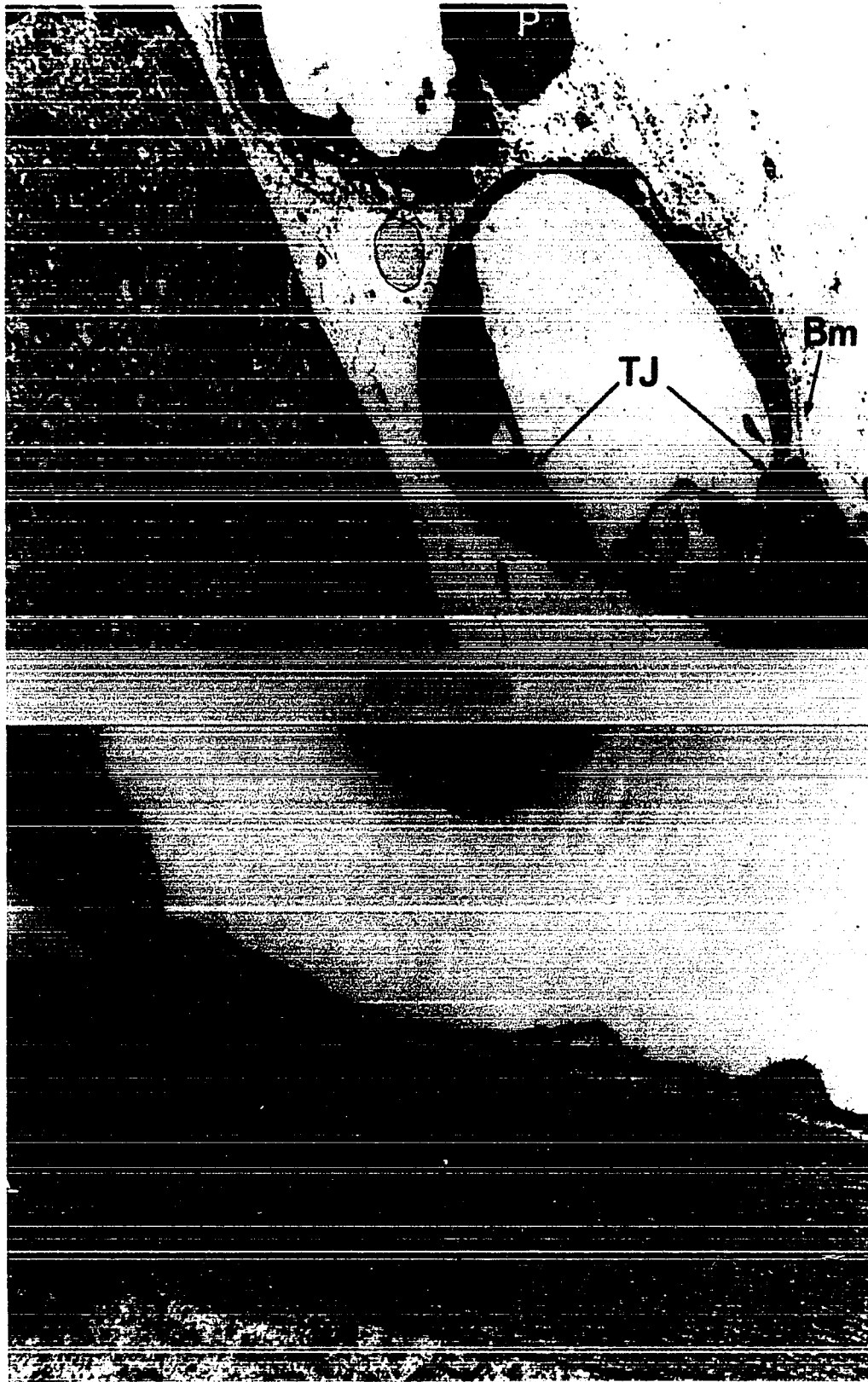


FIGURE 38

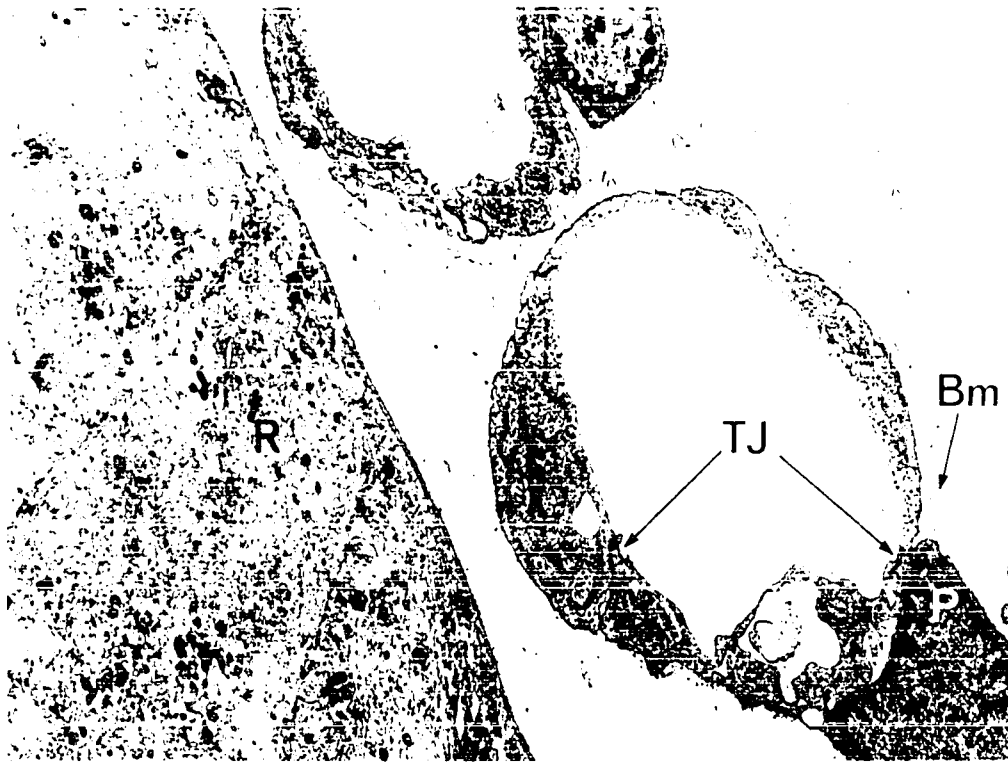


FIGURE 37



FIGURE 38

Figure 39 Electron micrograph showing a hyaloid capillary (HC) on the surface of the retina and a retinal capillary (RC) within the retina of a rat at the 21st day of gestation. The vessels are located adjacent to the optic disc. The internal limiting membrane (ILM) of the retina, formed by the inner processes of the Müller cells and a subjacent basement membrane layer, is discontinuous at the left. A thin, continuous basement membrane surrounds the endothelium of the hyaloid capillary. Both the retinal and the hyaloid capillary endothelium is rich in polysomes and is continuous without fenestrations. The wall of the retinal capillary is still tenuous but the endothelial cells are joined by small tight junctions (TJ). No glial investment is present around the retinal capillary.

Primary fixative: glutaraldehyde (X23,760)

Figure 40 A hyaloid capillary, within the vitreous of a 3 day neonatal rat, is shown. The endothelial cells (E) and pericytes (P) are easily distinguishable. A fine basement membrane layer is present surrounding the capillary wall.

Primary fixative: glutaraldehyde (X7,265)

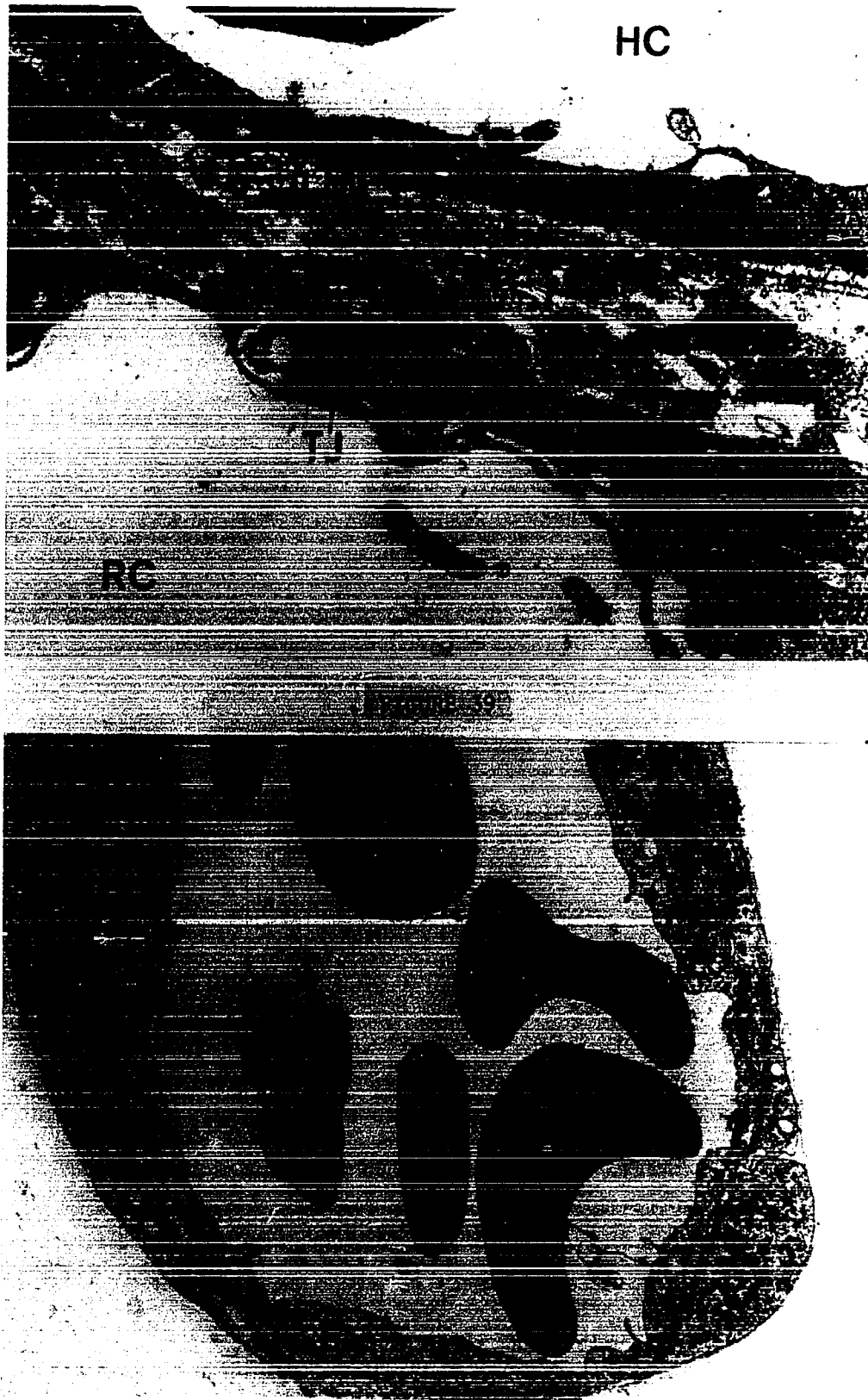

FIGURE 40

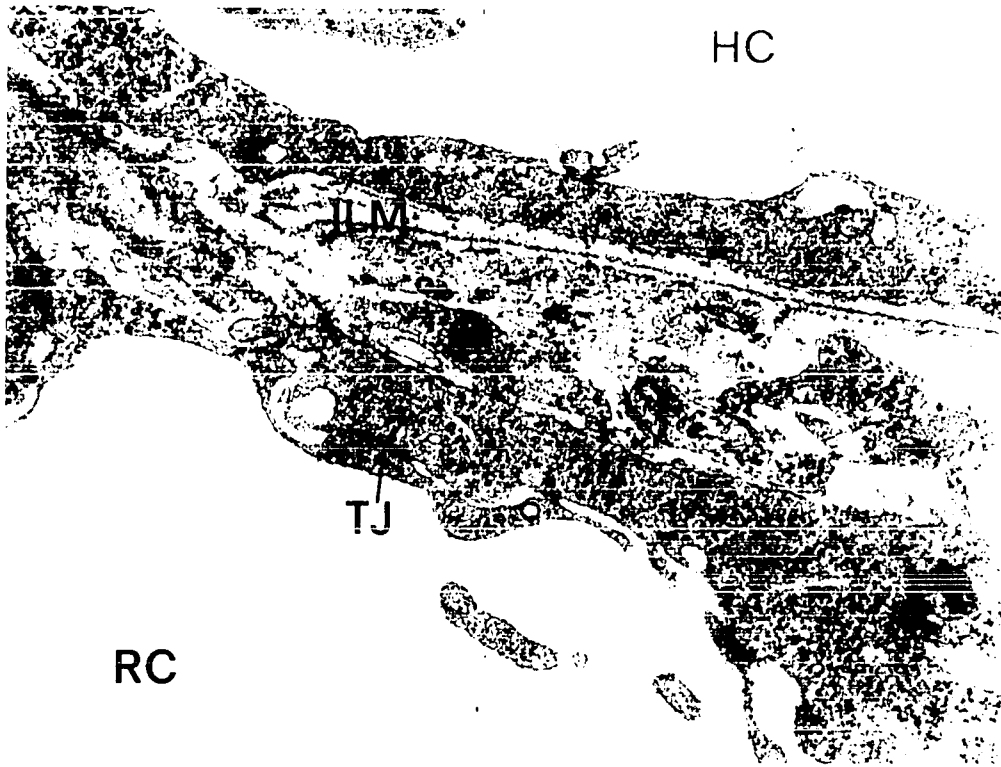


FIGURE 39

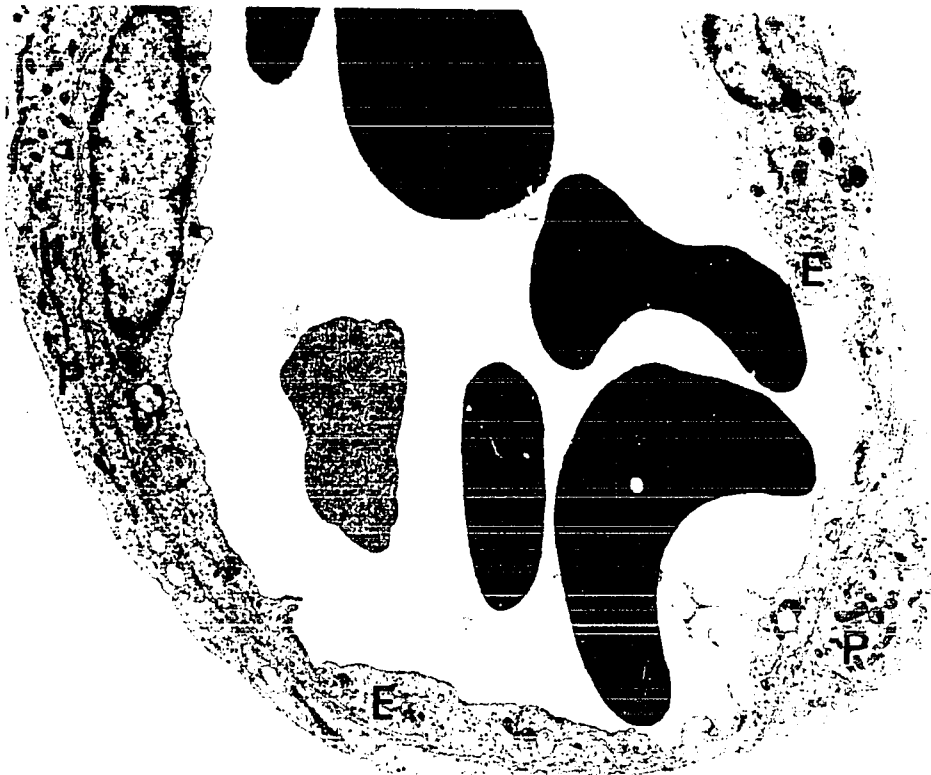

FIGURE 40

approximation. At these sites, the internal limiting membrane of the retina may become discontinuous, so that the two capillary systems are only separated by immature cell processes (Fig. 39).

3rd postnatal day (Figs. 40, 41 and 42).

By the 3rd neonatal day, the pericytes of the hyaloid capillaries show morphological differences from the endothelial cells (Figs. 40, 41 and 42). Mitochondria and Golgi zones are more plentiful in the pericyte cytoplasm than in that of the endothelial cells (Figs. 40 and 42). The cytoplasm of the pericytes is, on the whole, darker than that of the endothelial cells (Fig. 40) and on the luminal edge of the pericyte cytoplasm, a band of dense fibrillar material has formed (Figs. 40, 41 and 42). A fine band of basement membrane material surrounds the whole capillary and also intrudes between pericytes and endothelial cells (Figs. 41 and 42). The nuclei of both the pericytes and the endothelial cells are oval in shape and lie in the long axis of the cell (Figs. 40, 41 and 42). Several endothelial cells, still joined by tight junctions, form the inner wall of each capillary (Figs. 40 and 41). The long processes of the pericytes almost encircle each capillary but in some places the endothelial cells are uncovered (Figs. 40 and 41). Both pericytes and endothelial cells are thinner than previously (Fig. 40).

4th postnatal day (Figs. 43 and 44).

The thinning of the walls of the hyaloid capillaries continues and is even more pronounced on the 4th neonatal day. The endothelium remains continuous but, except for areas surrounding

Figure 41 Electron micrograph showing a portion of the wall of a hyaloid capillary within the vitreous on the 3rd neonatal day. A band of fibrillar material (FB) is obvious occupying the inner cytoplasm of the pericytes (P). Numerous tight junctions are visible joining adjacent endothelial cells (E). Dense granular material is present around pericytes and between pericytes and endothelial cells.

Primary fixative: glutaraldehyde (X10,800)

Figure 42 A portion of the wall of a hyaloid capillary, from the vitreous of a 3 day old rat, is shown. The pericyte (P) cytoplasm is rich in organelles and contains a dense band of fibrillar material at its inner border. A Golgi zone (G) is visible. The endothelium (E) is very thin in places but shows no fenestrations. At this stage, the pericyte covering of the capillary is almost complete.

Primary fixative: glutaraldehyde (X11,880)



FIGURE 41



FIGURE 42

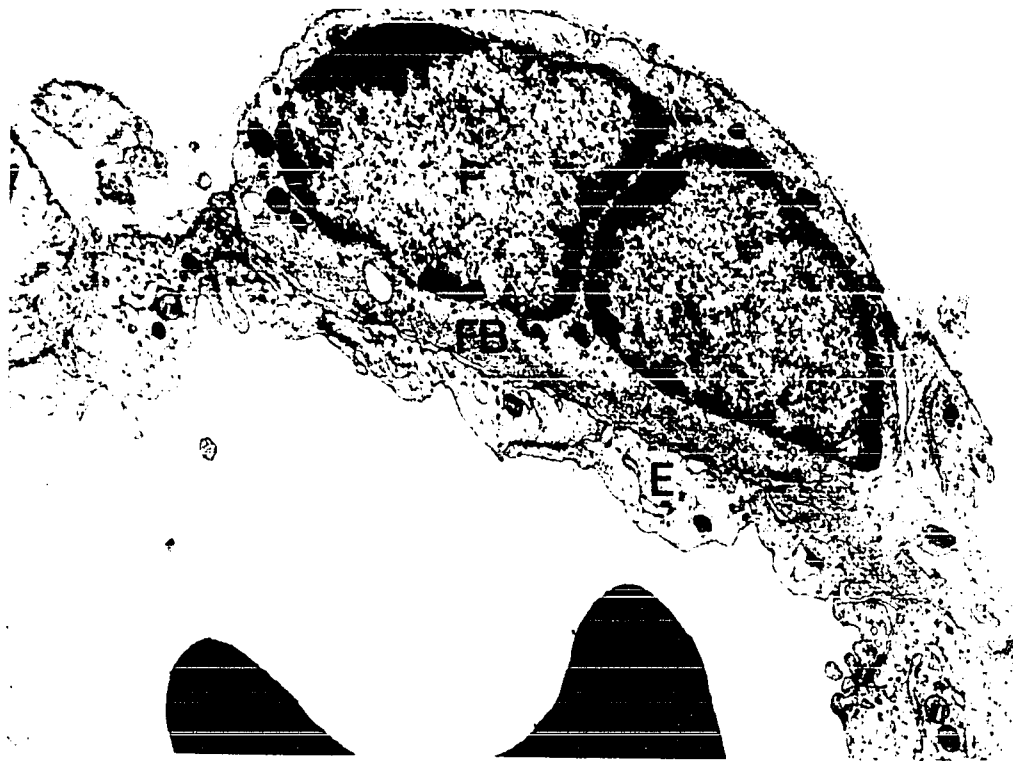


FIGURE 41

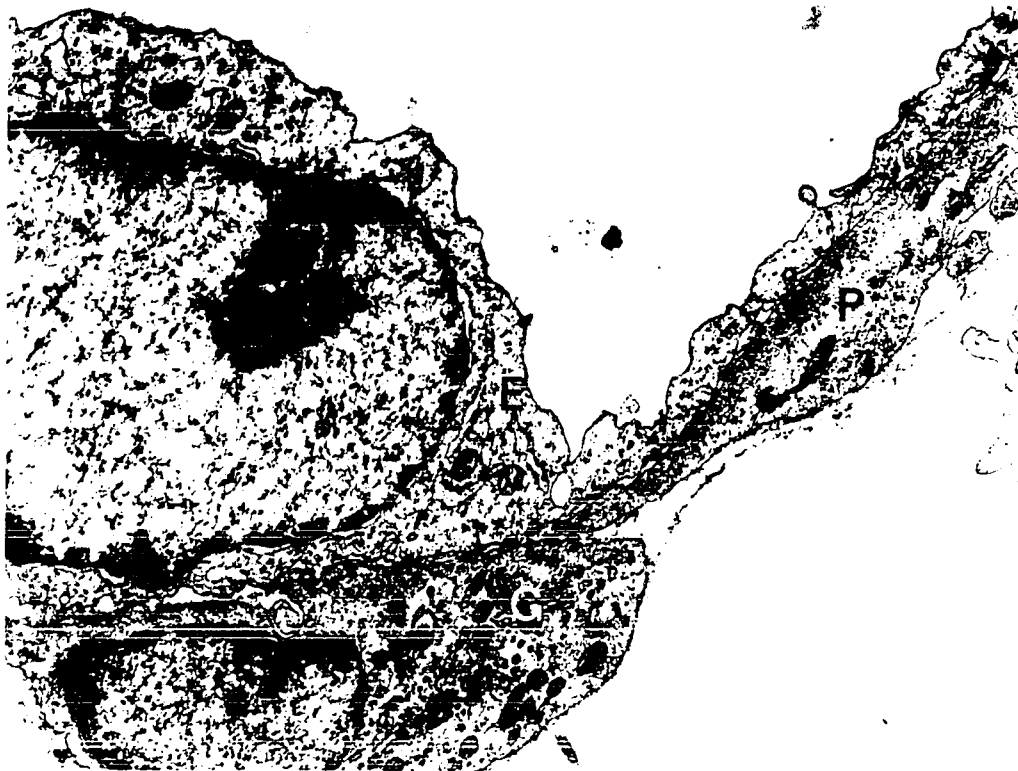


FIGURE 42

Figure 43 Electron micrograph showing a portion of the wall of a hyaloid capillary within the vitreous of a 4 day old rat. The capillary wall at this site is composed of a thin endothelium surrounded by a thick portion of a pericyte. The inner fibrillar band (FB) within the pericyte cytoplasm is still present but not as obvious as on the 34d neonatal day. Basement membrane material (Bm) is still visible.

Primary fixative: glutaraldehyde (X13,068)

Figure 44 A portion of the wall of a hyaloid capillary, within the vitreous of a 4 day old neonatal rat, is shown. At this site, the capillary wall is formed principally by the cell bodies and processes of endothelial cells (E). Thin processes of pericytes (P) surround the endothelium and a band of granular material lies just outside the pericyte investment.

Primary fixative: glutaraldehyde (X17,280)



FIGURE 43



FIGURE 44



FIGURE 43




FIGURE 44

nuclei, is quite thin. The pericytes are also thinner and their processes almost enclose the endothelium (Figs. 43 and 44).

A fine condensation of granular and fibrillar material is present around the periphery of each capillary and between pericytes and endothelial cells (Figs. 43 and 44). The dense band of fibrillar material within the cytoplasm of the pericytes is still present but not as conspicuous as before.

16th postnatal day (Fig. 45).

The wall of the hyaloid capillaries at 16 neonatal days has become still thinner but tight junctions between endothelial cells still maintain the integrity of the capillary wall. The dense band of fibrillar material within the pericytes is no longer obvious but the cytoplasm of the pericytes is slightly darker than that of the endothelium. A thin band of granular and fibrillar material is still present surrounding the capillary and within the interstices of its wall.

Retinal Capillaries

21st day of gestation (Fig. 39).

The retinal capillaries begin to appear in large numbers about the time of birth and when first formed are closely invested by developing neuroglial processes. The endothelial cells are rich in polysomes and several endothelial cells usually overlap to form a thick capillary wall. A fine condensation of granular and fibrillar material is already present on the external surface of the endothelial cells.

Figure 45 A portion of the wall of a hyaloid capillary from the vitreous of a 16 day old rat, is shown. The wall as a whole is much thinner than before but is still composed of processes of both endothelial cells (E) and pericytes (P). Long endothelial processes (Pr) protrude into the capillary lumen. The pericyte cytoplasm appears slightly darker than that of the endothelial cell but the inner cytoplasmic band of fibrillar material, seen earlier within the pericyte cytoplasm, is no longer visible. Granular extracellular material is still present.

Primary fixative: glutaraldehyde (X30,240)

Figure 46 Electron micrograph showing a retinal capillary just under the inner surface of the retina from a 1 day neonatal rat. The endothelial cells (E) are rich in polysomes and are joined by tight junctions (TJ). No definite basement membrane or glial investment is visible. Cells which may be the precursors of pericytes (P) are present outside the endothelium.

Primary fixative: glutaraldehyde (X9,180)



FIGURE 45

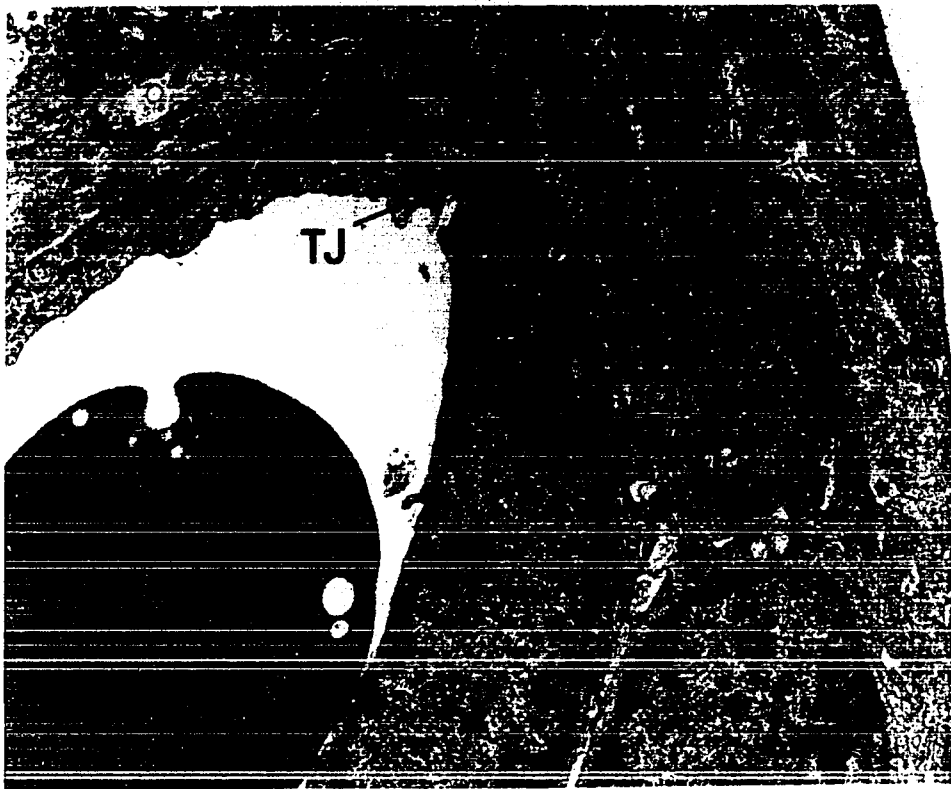

FIGURE 46




FIGURE 45

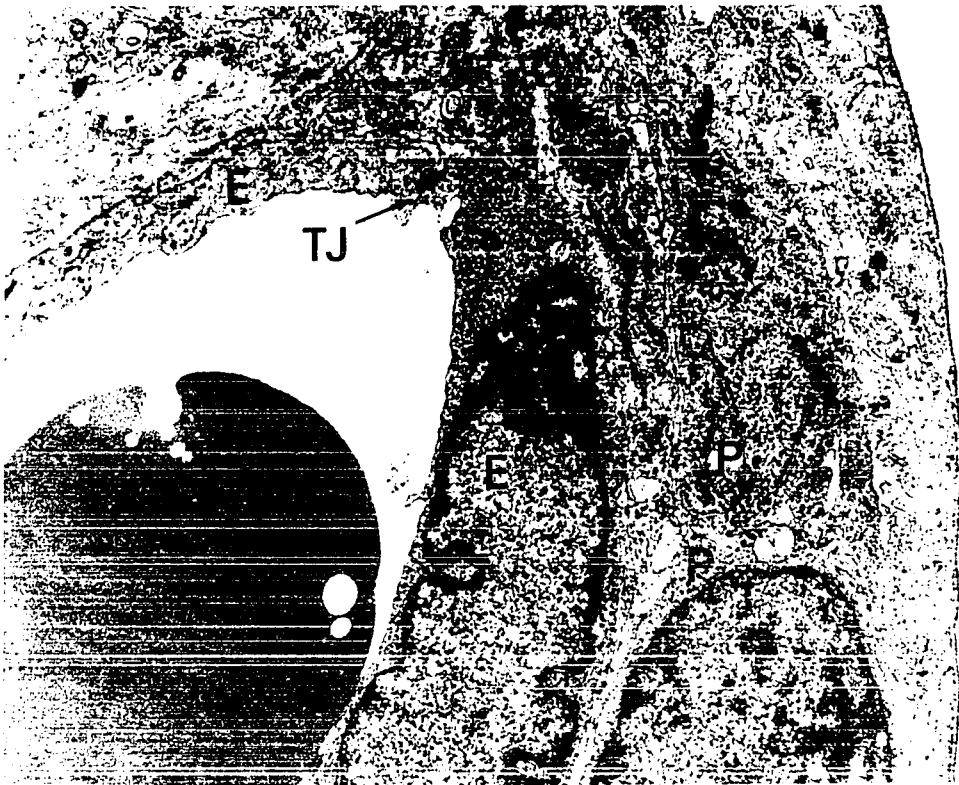


FIGURE 46

1st postnatal day (Fig. 46)

The endothelial cells forming the wall of the capillary are joined by tight junctions and remain rich in cytoplasmic organelles. Pericytes similar in appearance to the endothelial cells, have appeared just outside of the endothelium.

10th postnatal day (Figs. 47 and 48).

By this stage, the retinal capillaries have become more tubular in shape (Fig. 47). The cytoplasm of the endothelial cells and the pericytes contains mitochondria, polysomes and rough-surfaced endoplasmic reticulum (Figs. 47 and 48). Several endothelial cells, joined by tight junctions, encompass the capillary lumen (Fig. 47). The capillary basement membrane is not present as a distinct entity yet but a fine condensation of fibrillar material surrounds the capillary (Fig. 47). The pericytes have formed processes which cover more of the surface of the endothelial cells than previously (Fig. 47). The endothelial cells of the retinal capillaries still undergo mitosis at this time and the tight junctions binding endothelial cells remain intact during the cell division process (Fig. 48).

14th postnatal day (Figs. 49 and 50)

On the 14th neonatal day, most retinal capillaries are almost in an adult condition (Figs. 49 and 50). The capillary endothelium is now isolated from the nervous tissue of the retina by basement membrane material, pericytes and glial cells (Figs. 49 and 50). The basement membrane in some areas is still incomplete (Fig. 49) but it is more prominent now than at earlier stages of

Figure 47 Electron micrograph showing a retinal capillary within the nerve fibre layer of the retina of a 10 day old rat. The main portion of the capillary wall is formed by a dense endothelium (E) but pericytes (P) are beginning to spread their processes around the capillary. Tight junctions (TJ) affix adjacent endothelial cells. Basement membrane material is accumulating in the space surrounding the capillary.

Primary fixative: glutaraldehyde (X7,560)

Figure 48 Electron micrograph showing a retinal capillary in a 10 day old rat. An endothelial cell is undergoing mitosis (Mi) but the capillary wall remains complete and the tight junctions (TJ) joining endothelial cells are intact. Processes of pericytes (P) surround the endothelium. The capillary basement membrane and its glial investment have not formed as yet.

Primary fixative: glutaraldehyde (X13,068)




FIGURE 47




FIGURE 48



FIGURE 47

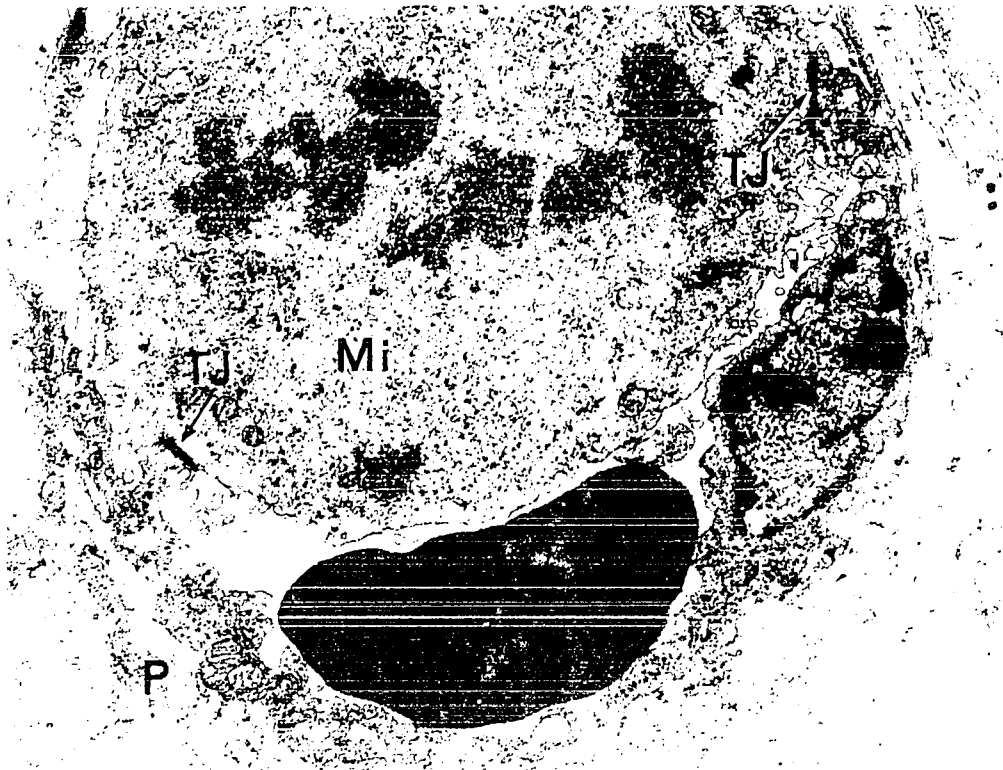


Figure 49 A retinal capillary, from the nerve fibre layer of the retina of a 14 day old rat, is shown. The cytoplasm of both endothelial cells (E) and pericytes (P) has a high ribosomal content. The pericyte investment of the capillary is now almost complete and the capillary basement membrane (Bm) can be clearly distinguished for the first time. Vesicles (V) are visible within the endothelial cytoplasm. The glial investment (Gl) of the capillary is forming.

Primary fixative: glutaraldehyde (X20,736)

Figure 50 A retinal capillary, near the ganglion cell (GC) layer of a 14 day old rat, is shown. The capillary basement membrane (Bm) is well developed and encloses both pericytes (P) and endothelial cells (E). A glial covering (Gl) is present and the capillary has the overall appearance of an adult vessel.

Primary fixative: glutaraldehyde (X10,800)




FIGURE 49




FIGURE 50

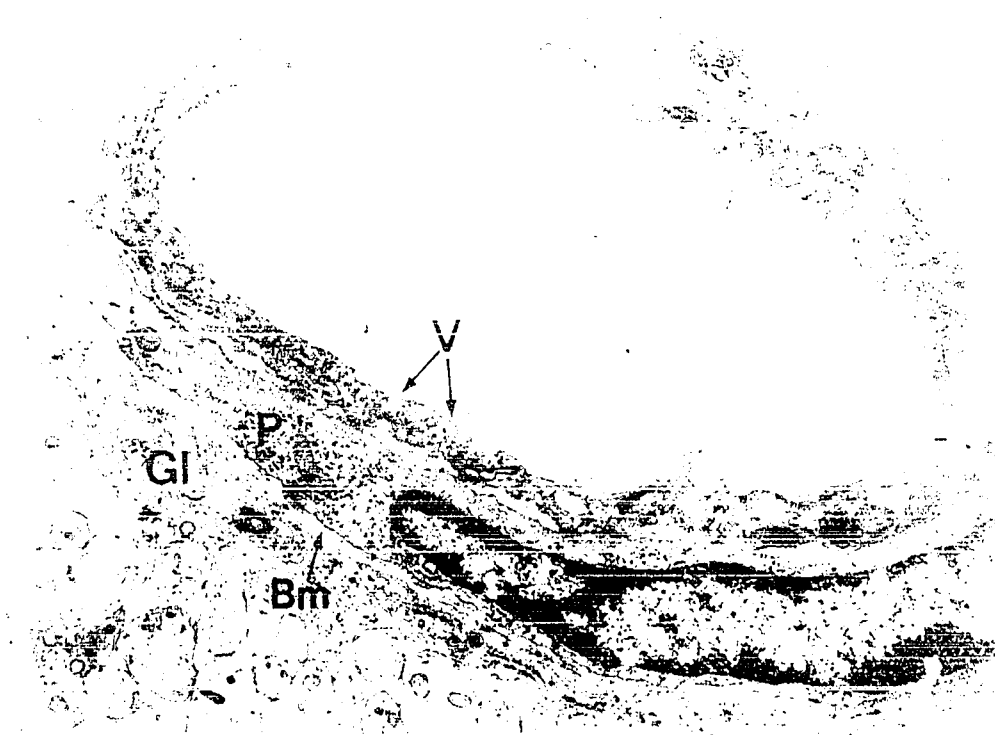
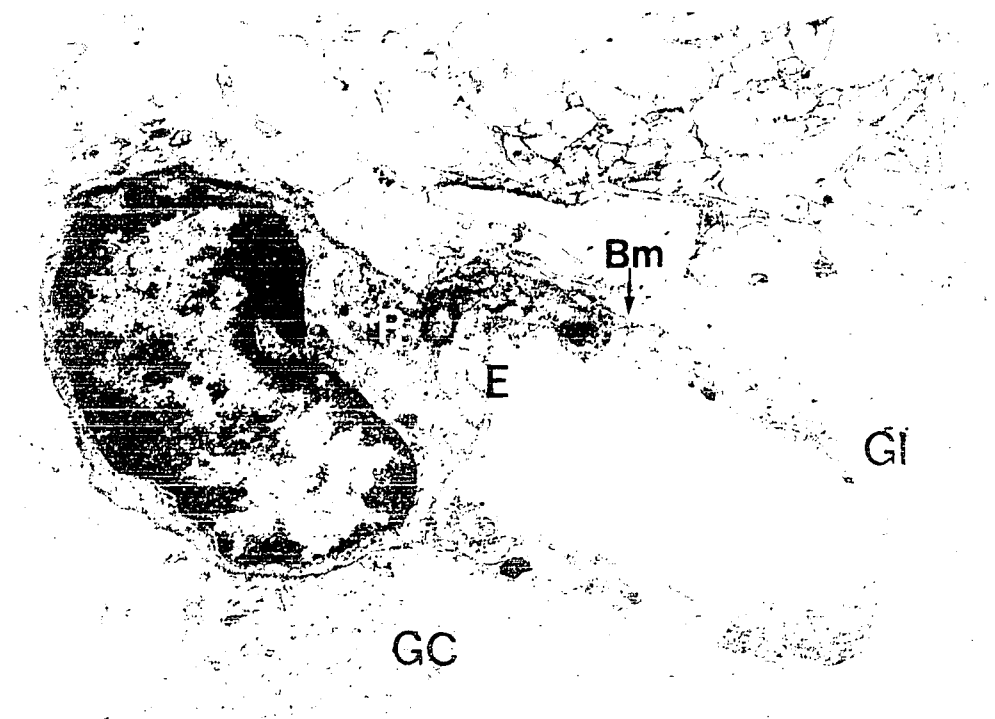


FIGURE 49



development (Fig. 50). Vesicles may be seen within the endothelial cytoplasm (Figs. 49 and 50).

V DISCUSSION

1. Development of the Retina in the Albino Rat.

The results of the present and previous studies indicate that although morphogenesis of the retina in the albino rat follows the typical mammalian pattern as exemplified by the human (Mann, 1964), differences exist between retinal development in this species and in man. The retina of the rat is unusually immature at birth when compared with the human and corresponds in degree of development to the retina of a 4 month old human fetus (Mann, 1964). This relative immaturity of the retina appears to be a common feature of non-primate mammals and in addition to the rat (Detwiler, 1932), has been demonstrated in the mouse (Tansley, 1933), rabbit (Noell, 1958), cat (Donovan, 1966) and dog (Parry, 1953). The rat retina also differs from the human in that it is preferentially adapted for nocturnal vision, containing almost exclusively rod receptors (Walls, 1942) and no fovea centralis (Walls, 1942).

The present results also indicate that the transient layer of Chievitz (Chievitz, 1887) does not appear in the rat retina during development. The prior study of rat retinal development by Detwiler (1932) similarly does not mention the appearance of this layer. During formation of the human retina, in contrast,

Barber (1955) and Mann (1964) have demonstrated that the single neuroblastic layer of nuclei splits early in development to form inner and outer neuroblastic layers. The zone lying between the inner and outer neuroblastic layers is the transient layer of Chievitz. In the human, cells within the outer part of the inner neuroblastic layer differentiate into Müller and amacrine cells. These cells then unite with the innermost cells of the outer neuroblastic layer, the precursors of bipolar and horizontal cells, to form the definitive inner nuclear layer and obliterate the layer of Chievitz. (Mann, 1964).

In the rat retina, in contrast, the first cells which differentiate by forming spherical nuclei and which move inwards from the neuroblastic layer probably form only ganglion cells. A few cells in the inner portion of the neuroblastic layer whose nuclei have also become spherical do not move inwards with the ganglion cells, but remain as a part of the neuroblastic layer. It seems likely, by analogy with the situation in the human, that these cells which remain as a part of the inner region of the neuroblastic layer in the rat are precursors of amacrine and Müller cells.

The layer of Chievitz has also been found to be absent in the retina of the cat (Donovan, 1966). Donovan states that the four cells types comprising the inner nuclear layer of the cat retina separate from the neuroblastic layer at the same time and hence no transient layer of Chievitz is seen. Mann (1928) observed a layer of Chievitz during retinal development in the eyes

of several vertebrate species, however, in some forms, its formation and existence was extremely short.

In the rat, the retina as a whole reaches its maximum thickness on the 5th postnatal day while retinal volume does not reach its peak until about the 12th day after birth (Table 1, Text-Fig. 3). Mitosis continues at the extreme periphery of the retina until the 10th to the 12th postnatal day. Both retinal thickness and retinal volume decrease somewhat after they have reached their maximum values. Between the 5th and the 12th postnatal days the outer nuclear, inner and outer plexiform and bacillary layers are increasing in thickness and the decrease in thickness of the total neural retina which occurs during this period is due to thinning of the remaining layers. The continued increase in retinal volume which occurs after retinal thickness has reached a maximum can be explained by the addition of cells to the retina provided by continued mitosis at the retinal periphery. The decrease in both retinal thickness and retinal volume which occurs after the 14th postnatal day may be due to several factors. These include a thinning of the retina as the eyeball enlarges (Keeney, 1951; Parry, 1953), further convergence of the cellular elements forming the retinal layers and possibly degeneration and subsequent loss of some cells.

The present results indicate that in the initial phase of retinal formation in the rat, activity is centered on the formation of a single neuroblastic layer which is continually

thickened by mitosis at its outer edge. Once established, the retinal cells differentiate and form the definitive retinal layers in sequence, beginning at the inner retinal border and moving progressively outwards. Once the nuclear layers are established they gradually thin, while simultaneously the adjacent fibrous layers formed by axonal and dendritic processes originating in the nuclear layers continue to thicken. As has been noted in other mammals (Mann, 1928, 1964; Donovan, 1966) the peripheral retina lags behind the posterior retina in development and the layers of the retina never attain peripherally the degree of thickness that they do posteriorly.

Since the ganglion cells are the first to be fully differentiated, the nerve fibre layer is the first of the fibrous layers to reach its maximum width on about the 4th postnatal day, posteriorly and the 10th postnatal day, peripherally. The inner plexiform layer, in contrast, does not reach its maximum width until about the 40th postnatal day both posteriorly and peripherally and it remains the thickest layer in the adult retina. The outer nuclear layer unlike the inner nuclear layer, increases in thickness after it is first established. The increase continues until about the 10th postnatal day both posteriorly and peripherally. Since mitosis continues at the extreme periphery of the retina until about the 12th postnatal day it seems likely that the main destination of the cells produced in this last pool of mitosis is the outer nuclear layer. Hollyffeld (1968), using radioautographic methods, has shown this to be the case in Rana pipiens tadpoles.

Cells from the final peripheral locus of mitosis do not appear to be entering the inner nuclear layer in large numbers since this layer decreases in width after its first appearance posteriorly, on the 5th postnatal day. Further, it does not seem likely that cells are added to the inner nuclear layer at its inner or outer borders since it is bounded by plexiform layers which are almost free of migrating cells.

Once they have reached their maximum widths, all layers of the retina decrease somewhat in thickness. This decrease in the width of the individual layers can be correlated with simultaneous decreases in the total width of the neural retina and in retinal volume. The decrease in thickness of the retinal layers during the later phases of development has also been described in other vertebrate species such as the human and the dog (Keeney, 1951; Parry, 1953; Mann, 1964).

2. Development of the Pigment Epithelium, Choriocapillaris and Bruch's Membrane.

The formation of the pro-pigment granules in the pigment epithelium of the albino rat follows essentially the same sequence of development as that described by Moyer (1961) in the mouse retinal pigment epithelium, and by Breathnach and Wyllie (1966) in the retinal epithelium of the human. According to Moyer (1961), several stages are involved in the development of a pigment granule. First, a spherical or ellipsoidal body appears which contains fine, randomly arranged lamellae enclosed by a membrane. Later, the internal lamellae become regularly oriented in parallel

array as the granule becomes fusiform in shape. Melanin is then deposited upon the inner membranes until the internal structure is totally obscured by pigment in the mature granule.

In both the albino rat and the albino mouse (Moyer, 1961) development stops at Moyer's stage 2, pro-pigment granule and Breathnach and Wyllie's (1966) premelanosome stage. At this stage the granule is enclosed by a membrane and contains an internal system of parallel membranes, which are not pigmented. In this study, pro-pigment granules were first detected on the 16th fetal day and were most numerous in the epithelium at the time of birth and shortly thereafter. Pro-pigment granules usually are not present in the adult albino pigment epithelium (Dowling and Gibbons, 1962). However, they still remain obvious on the 14th neonatal day. The process of resorption of the pro-pigment granules in the retinal epithelium of the albino rat starts with loss of the outer limiting membrane of the granule. Subsequently, there is dissociation and resorption of the internal lamellae. The block to melanization in the albino mammal is genetically controlled, and the work of Mishima and Loud (1963) on the human albino melanocyte indicates that the defect in albinism may be the lack of free l -tyrosine available to the melanosome.

Leeson (1968) has described in the developing retinal pigment epithelium of the albino rat "a fibrillar containing vesicle" which appears identical with the pro-pigment granules described here and by others (Moyer, 1959, 1960, 1961; Dowling and Gibbons, 1962; Breathnach and Wyllie, 1966). Leeson (1968) has speculated

that the "fibrillar containing vesicles" act as a source of lipoprotein membrane material for the formation of rod outer segment. This suggestion seems unlikely in view of the preponderance of evidence indicating that the membranes forming the mammalian photoreceptor outer segment originate from a ciliary outgrowth of the receptor inner segment (De Robertis, 1956a; Tokuyasu and Yamada, 1959; Missotten, 1965), and are continuously renewed at their base throughout life by transfer of proteins from the inner to the outer segment of the photoreceptor cell (Droz, 1963; Young, 1965, 1966, 1967).

The series of lateral cell junctions between the pigment epithelial cells described in this study, were first detected on the 16th fetal day and were fully developed by the 8th or 9th neonatal day. This terminal bar system is a prominent feature of the adult retinal epithelium (Yamada, Tokoyasu and Iwaki, 1958a; Fine, 1961; Leure-du Pree, 1968) and represents the membrane originally described in a light microscopic study by Verhoeff (1903). Cohen (1965) has suggested that this terminal bar system constitutes an effective barrier to extracellular transport. The fact that the lateral cell junctions are not present prior to 5 days before birth suggests that the extracellular transport of materials may be greater at this time and further that the more immature pigment epithelial cells undergo more extensive movements than their later counterparts.

The apical processes of the pigment epithelium of the albino rat were first noted on the 18th fetal day and are quite

prominent by the 5th neonatal day when they enclose the inner segments prior to outer segment formation. It is of particular interest that in this study the apical epithelial processes were present prior to the formation of the outer segments of the receptor cells. Dowling and Gibbons (1962) have indicated that in the Harvard strain of the albino rat, the apical processes do not appear until the 9th or 10th neonatal day when outer segments form. The intimate association of the inner processes with the photoreceptor cells suggests that they may play a role in the nutrition and orientation of first, the inner segments and later the outer segments.

Formation of the basal infoldings of the pigment epithelium in the albino rat begins at birth but is not complete over the entire basal surface until the outer segments of the photoreceptor cells first appear. The marked infolding of the basal epithelial plasma membrane results in a greatly increased surface area available for transport at a time when the nutrient requirements of the outer retina are rapidly increasing.

The lamellated inclusion body observed for the first time in the pigment epithelium of the 14 day old neonatal rat is a common feature of adult mammalian pigment epithelium (Dowling and Gibbons, 1962; Bairati and Orzalesi, 1963) but this is the earliest stage in which it has been described. It has been suggested that the lamellated bodies found within the retinal pigment epithelium are residual portions of photoreceptor outer segments which have been previously taken up at the apical epithelial

border (Dowling and Gibbons, 1962; Bairati and Orzalesi, 1963). The fact that in this study the lamellated bodies did not appear in the pigment epithelium until after outer segment formation adds further support to this hypothesis. In addition, it is significant that lamellated bodies are no longer present in the retinal pigment epithelium in animals that have previously been subjected to experimental retinal detachment (Kroll and Machemer, 1968), but reappear in the pigment epithelium after retinal re-attachment (Kroll and Machemer, 1969).

The cilia identified, in this investigation, in the early stages of pigment epithelial development probably serve no useful function. Cilia were not found after the 16th day of gestation in the rat, and are not a normal constituent of adult mammalian pigment epithelium. Where found, the cilia always projected inwards towards the embryological external surface of the pigment epithelium. It may be that the cilia are expressions of the primitive more totipotent capabilities of surface ectodermal cells. Cilia have been observed during developmental stages in a number of other mammalian tissues including endocrine organs, pancreas, kidney, skin and various tumours (Allen, 1965).

In the adult mammal, Bruch's membrane or the lamina vitrea is composed of 5 layers; the basement membrane of the pigment epithelium, the basement membrane of the choriocapillary endothelium and inner and outer collagenous layers separated by a discontinuous lamina densa. (Sumita, 1961; Nakaizumi, 1964; Leeson and Leeson, 1967;

Hollenberg and Burt, 1969). The first layer of Bruch's membrane to appear on the 15th day of gestation is the basement membrane of the pigment epithelium. This layer, according to Cohen (1961), is a part of the basement membrane layer that completely surrounds the developing optic vesicle. The next layer to appear during the last 2-3 fetal days is the collagenous layer, probably a product of the neighbouring fibroblasts. Once the collagen appears it gradually fills the space between the choriocapillary endothelium and the pigment epithelium. Later, when the lamina densa appears, the single collagenous layer is split into an inner and outer portion. The basement membrane of the choriocapillaris is not fully formed until after birth. The last layer of Bruch's membrane to appear is the central lamina densa, which is largely composed of elastic fibers (Sumita, 1961; Leeson and Leeson, 1967). It is now well known that the choriocapillaris supplies a major portion of the metabolites utilized by the outer retina (Bernstein, 1960, 1961; Bernstein and Hollenberg, 1965a, b). To accomplish this purpose, the choriocapillaris endothelium on the retinal side becomes very thin by the 17th day of gestation. By the 9th neonatal day, when the basal infoldings of the pigment epithelium are well formed and the photoreceptor outer segments are beginning to appear, fenestrae are numerous throughout the attenuated endothelium adjacent to Bruch's membrane. Bernstein (1961) and Leeson and Leeson (1967) previously indicated that, as a further aid to rapid transport of materials towards the pigment epithelium, the majority of the endothelial nuclei and thicker organelle-containing

areas of endothelial cytoplasm of the choriocapillaris becomes oriented towards the choroid. Further, Berson (1965) observed that the choriocapillaris of the rat first appears at the posterior pole of the eye and then spreads peripherally. This is also the mode of development of the mammalian photoreceptor outer segments, which form slightly later (Mann, 1964; Donovan, 1966). It is evident then that a mature choriocapillaris bed is available to nourish the photoreceptor outer segments as they form. It is also possible that the presence of a well developed choroidal vasculature may play a role in inducing photoreceptor outer segment formation.

3. Development of the Hyaloid and Retinal Capillaries.

The present results indicate that, in the rat, the two capillary systems derived from mesodermal tissue at the optic stalk are basically similar in appearance. Both the developing retinal and hyaloid capillaries possess a continuous endothelium without fenestrations and an incomplete outer covering of pericytes. Although the basement membrane of the retinal capillaries is much more definite and better organized than that of the hyaloid capillaries the more mature vessels of both capillary types possess a distinct basement membrane covering. The presence of fine fibrillar material within the inner border of the cytoplasm of the mature hyaloid pericytes and the absence of such material in retinal pericytes represents a true difference which is not simply a matter of degree. Both the hyaloid and the retinal capillaries

can be classified as type A-1- α according to the classification of Bennett, Luft and Hampton (1959).

It is evident that, in the rat, the hyaloid capillaries are extremely fragile structures particularly as they approach regression when both endothelial cells and pericytes become stretched and thin. It seems likely that these vessels rely to a great extent upon the vitreous for mechanical support. In addition, the fibrillar material within the pericyte cytoplasm may serve to further strengthen the hyaloid capillary wall, although the fibrils may also have a contractile function.

The fine structure of hyaloid capillaries forming the tunica vasculosa lentis has been studied in the human embryo (Mikawa, 1965). Also Lasansky (1967) has studied the morphology and function of hyaloid capillaries resting on the inner surface of the retina in the toad. In the toad, the hyaloid vessels are a permanent vascular component of the eye (Michaelson, 1954). In both the human and the toad, as in the rat, the hyaloid endothelium is continuous, without fenestrations and is surrounded by pericytes and a poorly organized layer of basement membrane material (Mikawa, 1965; Lasansky, 1967). It is of particular interest that in the present study it has been shown that, in the rat, the portion of the hyaloid capillary wall facing the retina or the lens is almost always extremely thin and devoid of nuclei and processes of pericytes. This is also true of those capillaries forming the tunica vasculosa lentis in the human (Mikawa, 1965). It seems likely that this structural specialization favours the

movement of nutrient materials from the hyaloid capillaries towards the retina and lens rather than through thicker portions of the capillary wall, centrally, into the vitreous. This situation is analogous to that of the choriocapillaris in which the thickest portion of the capillary wall is situated on the choroidal side and movement of nutrients towards the pigment epithelium and neural retina is favoured (Bernstein, 1961; Bernstein and Hollenberg, 1965a; Leeson and Leeson, 1967). Lasansky (1967) has attempted to follow the movement of tracer substances across the hyaloid capillary wall to the retina in the toad. His results indicate that the hyaloid capillaries functionally resemble central nervous system capillaries in that they do not allow the passage of trypan blue and ferrocyanide. Lasansky (1967) feels that the only pathway across the hyaloid capillary wall is directly through the endothelial cells effectively prevented intercellular passage of the tracer materials.

Another potential impediment to the passage of materials across the walls of both the retinal and hyaloid capillaries is the capillary basement membrane. Shakib and de Oliveira (1966) have suggested that, in the retinal capillaries of the kitten, both endothelial cells and pericytes contribute to the formation of the basement membrane. In the early stages of formation of the retinal capillaries in the rat, both endothelial cells and pericytes are rich in polysomes and rough surfaced endoplasmic reticulum. These cells seem quite capable of producing at least the protein component of the capillary basement membrane. Further thickening

of the basement membrane of the retinal capillaries as they continue to develop may be due, at least in part, to accumulation of materials trapped in transit across the capillary wall.

The fine structure of mature, adult retinal capillaries has been described in a number of mammalian species (Maeda, 1959; Hogan and Feeney, 1963; Ishikawa, 1963; Bernstein and Hollenberg, 1965b; Bloodworth, Gutgesell and Engerman, 1965; Ikui and Tominaga, 1965; Engerman, Molitor and Bloodworth, 1966) including the rat (Kissen and Bloodworth, 1961). Comparison of the structure of the mature retinal capillary with the developing capillaries illustrated in this study and in prior investigations in the kitten and the rat (Shakib and de Oliveira, 1966; Shakib, de Oliveira and Henkind, 1968) reveals several distinctions. In general the endothelial cells of the developing retinal capillaries are thicker and contain a more generous allotment of polysomes and rough surfaced endoplasmic reticulum than do the mature capillaries. The pericytes, once established, become thinner, but otherwise do not change significantly with aging. The capillary basement membrane is much thicker and denser in the adult retinal capillary than in its immature counterpart. Finally, retinal capillaries, early in development in the rat, do not possess the outer glial investment characteristic of the adult central nervous system capillary.

VI SUMMARY

1. The sequential appearance and subsequent changes in the relative thickness of the layers of the neural retina have been described for the first time in the albino rat eye.
2. The morphology of the retinal layers has been described from the 11th day of gestation until 225 days after birth.
3. A timetable indicating the first appearance and relative changes in thickness of each of the retinal layers has been prepared.
4. The inverted layer of the optic cup becomes greatly thickened by mitosis at its outer border after the optic vesicle is obliterated.
5. The retinal layers form in sequence, from the inner retinal border outwards and always beginning posteriorly and spreading peripherally.
6. The transient layer of Chievitz does not appear in the albino rat eye.
7. All retinal layers are present by 8 days after birth, although not in their adult proportions.
8. Retinal thickness reaches a maximum on the 5th postnatal day, while retinal volume only reaches a peak on the 7th to 12th postnatal day.

9. The nerve fibre, inner plexiform, outer plexiform and bacillary layers all continue to increase in thickness after the ganglion cell and inner and outer nuclear layers have reached their maximum thickness and have begun to thin.
10. The fine structure of the developing pigment epithelium, Bruch's membrane and choriocapillaris has been described from the 15th day of gestation until 2 weeks after birth.
11. The apical cytoplasm of the pigment epithelial cells forms long projections that enclose first the developing photoreceptor inner segments, and later the receptor outer segments.
12. The basal region of the pigment epithelium becomes highly infolded over the whole basal surface.
13. The pigment granules in the albino rat develop normally in the inner epithelial cytoplasm until the stage of melanin deposition, after which they break down.
14. The lamellated inclusion body of the adult pigment epithelium first appears during the second week of postnatal life.
15. The five layers of Bruch's membrane are formed as follows: the basement membrane of the pigment epithelium on the 6th prenatal day; the collagenous layers on the 3rd and 4th prenatal days; the basement membrane of the choriocapillaris endothelium on the last prenatal day; and finally the central lamina densa on the 5th postnatal day.
16. The wall of the choriocapillaris changes from a continuous endothelium on the 6th prenatal day, to a thin fenestrated

endothelial wall facing the pigment epithelium by the 5th postnatal day.

17. The ultrastructure of the developing retinal and hyaloid capillaries has been described for the first time in the albino rat.
18. Both the hyaloid and retinal capillaries possess a continuous endothelium, multilayered basement membrane and an incomplete pericyte covering.
19. The hyaloid capillary pericytes possess an inner cytoplasmic band of fibrillar material which the retinal capillary pericytes lack.
20. The basement membrane of the hyaloid capillaries never attains the thickness of the retinal capillaries' basement membrane.
21. An outer glial covering, limited to the retinal capillaries, is the last layer of the retinal capillaries to be fully developed.

APPENDIX 1

The classification of vertebrate blood capillaries as outlined by Bennett et al (1959) is as follows:

- Capillary type A. - capillaries with a complete continuous basement membrane.
- Capillary type B. - capillaries without a complete continuous basement membrane.
- Capillary type 1. - capillaries without fenestrations or pores.
- Capillary type 2. - capillaries with intracellular fenestrations or pores.
- Capillary type 3. - capillaries with intercellular fenestrations or pores.
- Capillary type α . - capillaries without a complete pericapillary cellular investment (i.e. pericytes).
- Capillary type β . - capillaries with a complete pericyte investment.

BIBLIOGRAPHY

- Agrawal, P.K., Agarwal, L.P. and Tandon, H.D. (1964). The cellular structure of the hyaloid system of the rat. *Orient. Arch. Ophthalm.* 2: 279-282.
- Allen, R.A. (1965). Isolated cilia in inner retinal neurons and in retinal pigment epithelium. *J. Ultrastruct. Res.* 12: 730-747.
- Arnold, F. (1832). *Anatomische und physiologische untersuchungen Ueber das auge des menschen.* Heidelberg and Leipsiz : K. Groos.
- Ashton, N. (1951). Anatomical study of schlemm's canal and aqueous veins by means of neoprene casts. Pt. 1. Aqueous veins. *Brit. J. Ophthalm.* 35: 291-303.
- Ashton, N. and de Oliveira, F. (1966). Nomenclature of pericytes - Intramural and extramural. *Brit. J. Ophthalm.* 50: 119-123.
- Babuchin, A. (1863). Beitrage zur entwicklungsgeschichte des auges, besonders der retina. *Würzb. Naturwiss. Zeits.* 4: 71-90.
- Bach, L. and Seefelder, R. (1914). *Atlas zur entwicklungsgeschichte des menschlichen auges.* Leipzig and Berlin : W. Engelmann.
- Bairati, A. and Orzalesi, N. (1963). The ultrastructure of the pigment epithelium and of the photoreceptor - pigment epithelium junction in the human retina. *J. Ultrastruct. Res.* 9: 484-496.

- Barber, A.N. (1955). Embryology of the human eye. St. Louis :
Mosby.
- Bennett, H.S., Luft, J.H. and Hampton, J.C. (1959). Morphological
classification of vertebrate blood capillaries. Amer. J.
Physiol. 196: 381-390.
- Bernstein, M.H. (1960). Functional structure of the retinal
epithelium. Anat. Rec. 136 : 164.
- Bernstein, M.H. (1961). Functional architecture of retinal
epithelium. In Smelser, G.K. ed. The Structure of the eye.
New York : Academic. 139-150.
- Bernstein, M.H. (1966). Secretory Function in the retinal
epithelium. In Uyeda, R. ed. Electron microscopy, 1966.
Tokyo : Mauzen. vol. 2: 491-492.
- Bernstein, M.H. and Hollenberg, M.J. (1965a). Movement of electron
opaque tracers through the capillaries of the retina. In
Rohen, J.W. ed. The Structure of the eye II. Stuttgart :
Schattauer - Verlag. 129-138.
- Bernstein, M.H. and Hollenberg, M.J. (1965b). Fine structure
of the choriocapillaris and retinal capillaries. Invest.
Ophthalm. 4: 1016-1025.
- Berson, D. (1965). The development of the choroid and sclera
in the eye of the Fetal rat with particular reference to their
developmental interrelationship. Exptl. Eye Res. 4: 102-103.
- Bloodworth, J.M.B. Jr., Gutgesell, H.P. and Engerman, R.L. (1965).
Retinal vasculature of the pig - light and electron microscopic
studies. Exptl Eye res. 4: 174-178.

- Bourne, M.C., Campbell, D.A. and Tansley, K. (1938). Hereditary degeneration of the rat retina. *Brit. J. Ophthalm.* 22: 613-623.
- Breathnach, A.S. and Wyllie, L. (1966). Ultrastructure of retinal pigment epithelium of the human fetus. *J. Ultrastruct. Res.* 16: 584-597.
- Bruch, C. (1844). Untersuchungen zur Kenntniss des kornigen pigmentes der wirbelthiere en physiologie und pathology hinsicht. Zurich.
- Bruns, L. (1882). Vergleichend anatomische studien über das blutgefäßsystem der netzhaut. *Ztschr. F. Vergleich. Augenheilk.* 1: 77-101.
- Cairns, J.E. (1959). Normal development of the hyaloid and retinal vessels in the rat. *Brit. J. Ophthalm.* 43: 385-393.
- Cameron, J. (1905a). The development of the retina in amphibia. An embryological and cytological study. Part 1. *J. Anat. Physiol.* 39: 135-153.
- Cameron, J. (1905b). The development of the retina in amphibia. An embryological and cytological study. Part 2. *J. Anat. Physiol.* 39: 332-348.
- Cameron, J. (1905c). The development of the retina in amphibia. An embryological and cytological study. Part 3. *J. Anat. Physiol.* 39: 471-488.
- Cameron, J. (1911). Further researches on the rods and cones of vertebrate retinae. *J. Anat. Physiol.* 46: 45-53.

- Chievitz, J.H. (1887). Die area und fovea centralis retinae beim menschlichen foetus. Internat. Monatss. F. Anat. v. Physiol. 4: 201-226.
- Christie, G.A. (1964). Developmental stages in somite and post-somite rat embryos, based on external appearance and including some features of the macroscopic development of the oral cavity. J. Morph. 114: 263-286.
- Cogan, D.G. (1963). Development and senescence of the human retinal vasculature. Trans. Ophthal. Soc. U.K. 83: 465-489.
- Cogan, D.G. and Kuwabara, T. (1967). The mural cell in perspective. Arch. Ophthal. (Chicago). 78: 133-139.
- Cohen, A.I. (1960). The ultrastructure of the rods of the mouse retina. Amer. J. Anat. 107: 23-48.
- Cohen, A.I. (1961). Electron microscopic observations of the developing mouse eye I Basement membranes during early development and lens formation. Develop. Biol. 3: 297-316.
- Cohen, A.I. (1963). The fine structure of the visual receptors of the pigeon. Exptl Eye Res. 2: 88-97.
- Cohen, A.I. (1965). A possible cytological basis for the "R". membrane in the vertebrate eye. Nature 205: 1222-1223.
- Corti, A. (1850). Beitrag zur anatomie der retina. Arch. F. Anat. Physiol. v. Wiss. Med. 273-275.
- Coulombre, A.J. (1955). Correlations of structural and biochemical changes in the developing retina of the chick. Amer. J. Anat. 96: 153-189.

- Dartnall, H.J. and Tansley, K. (1963). Physiology of vision :
retinal structure and visual pigments. *Ann. Rev. Physiol.*
25: 433-458.
- De Robertis, E. (1956a). Morphogenesis of the retinal rods. An
electron microscopic study. *J. Biophys. Biochem. Cytol.*
2 (Suppl.): 209-218.
- De Robertis, E. (1956b). Electron microscope observations on the
sub-microscopic organization of retinal rods. *J. Biophys.*
Biochem. Cytol. 2: 319-330.
- De Robertis, E. (1960). Some observations on the ultrastructure
and morphogenesis of photoreceptors. *J. Gen. Physiol.*
43 (Suppl. 2): 1-13.
- De Robertis, E. and Franchi, C.M. (1956). Electron microscopic
observations on synaptic vesicles in synapses of the retinal
rods and cones. *J. Biophys. Biochem. Cytol.* 2: 307-318.
- Detwiler, S.R. (1932). Experimental observations upon the de-
veloping rat retina. *J. Comp. Neurol.* 55: 473-492.
- Donovan, A. (1966). The postnatal development of the cat retina.
Exptl Eye Res. 5: 249-254.
- Dowling, J.E. (1960). Chemistry of visual adaptation in the rat.
Nature 188: 114-118.
- Dowling, J.E. and Boycott, B.B. (1965). Neural connections of the
retina : fine structure of the inner plexiform layer. *Cold*
spring Harb. Symp. 30: 393-402.
- Dowling, J.E. and Boycott, B.B. (1966). Organization of the
primate retina : electron microscopy. *Proc. Roy. Soc. B.*
166: 80-111.

- Dowling, J.E. and Gibbons, I.R. (1962). Fine structure of the pigment epithelium in the albino rat. *J. Cell. Biol.* 14: 459-474.
- Droz, B. (1963). Dynamic condition of proteins in the visual cells of rats and mice as shown by radioautography with labelled amino acids. *Anat. Rec.* 145: 157-167.
- Duke-Elder, Sir W.S. (1961). System of ophthalmology. Vol II The anatomy of the visual system. London : Kimpton.
- Duke-Elder, Sir W.S. (1963). System of ophthalmology. Vol III, Part I. Embryology. London : Kimpton.
- Ehrlich, P. (1885). Zur biologischen verwertung des methylenblau. *Centralbl. f.d. Med. Wiss.* 23: 113-117.
- Engerman, R.L. and Meyer, R.K. (1965). Development of retinal vasculature in rats. *Amer. J. Ophthal.* 60: 628-641.
- Engerman, R.L., Molitor, D.L. and Bloodworth, J.M.B. Jr. (1966). Vascular system of the dog retina : light and electron microscope studies. *Exptl Eye res.* 5: 296-301.
- Fine, B.S. (1961). Limiting membranes of the sensory retina and pigment epithelium - an electron microscopic study. *Arch. Ophthal. (Chicago)* 66: 847-860.
- Fine, B.S. (1963). Ganglion cells in the human retina. *Arch. Ophthal. (Chicago)* 69: 83-96.
- Fuchs, H. (1905). Zur entwicklungsgeschichte des wirbeltierauges i. über die entwicklung der augengefäße des kaninchens. *Anat. Hefte.* 28: 1-251.

- Garron, L.K. (1963). The ultrastructure of the retinal pigment epithelium with observations on the choriocapillaris and Bruch's membrane. *Trans. Amer. Ophthal. Soc.* 61: 545-588.
- Golgi, C. (1873). Sulla sostanza grigia del cervello. *Gazz. Med. Ital. Lombarda.* 6: 244-246.
- Gottsche, C.M. (1836). Ueber der bau der retina des menschen und der saugethiere. *Pract. v. Krit. Mitth. a.d. Geb. d. Med.* 2: 40.
- Gray, P. (1954). *The microtometist's formulary and guide.* London : Constable.
- Hannover, A. (1840). Die chromsäure ein vorzügliches mittel bei mikroskopischen untersuchungen. *Arch. F. Anat. Physiol. v. Wiss. Med.* 320: 549.
- Hellström, B. and Zetterström, B. (1956). The effect of light on the manifestation of the electro retinogram and on histochemically demonstrable SH-groups in the retina. *Exptl Cell Res.* 10: 248-251.
- Henkind, P. and de Oliveira, F. (1967). Development of retinal vessels in the rat. *Invest. Ophthal.* 6: 520-530.
- Henle, F. (1832). *De membrana pupillari aliisque oculi membranis pelluscentibus.* Bonn : Weberum.
- Hesse, Fr. (1880). Über die vertheilung der blutgefäße in der netzhaut. *Arch. F. Anat. v. Entwick.* 219-223.
- Hogan, M.S. and Feeney, L. (1963). The ultrastructure of the retinal blood vessels II the small vessels. *J. Ultrastruct. Res.* 9: 29-46.

- Hollenberg, M.J. and Bernstein, M.H. (1966). Fine structure of the photoreceptor cells of the ground squirrel (Citellus tridecimlineatus tridecemlineatus). Amer. J. Anat. 118: 359-374.
- Hollenberg, M.J. and Burt, L.W. (1969). The fine structure of Bruch's membrane in the human eye. Canad. J. Ophthal. 4: 296-306.
- Hollyfield, J.G. (1968). Differential addition of cells to the retina in Rana pipiens tadpoles. Develop. Biol. 18: 163-179.
- Horsten, G.P. and Winkelman, J.E. (1960). Development of the ERG in relation to histological differentiation of the retina in man and animals. Arch. Ophthal. (Chicago). 63: 232-242.
- Huschke, E. (1832). Ueber die erste entwicklung des auges und die damit zusammenhängende cyklopie. Arch. F. Anat. v. Physiol. 1 : 1
- Huschke, E. (1935). Untersuchungen über einige streitpunkte in der anatomie des menschlichen auges. Zeits. f.d. Ophthal. (Ammon) 4: 272.
- Ikui, H. and Tominaga, Y. (1965). Electron microscopic studies of the blood vascular system in the optic nerve and retina of the human eye. Trans. Asia-Pacif. Acad. Ophthal. 2: 347-360.
- Inomata, H. (1965). Electron microscopic observations on Müller's fibres in the human retina. Acta. Soc. Ophthal. Jap. 69: 2133-2143.
- Ishikawa, T. (1963). Fine structure of retinal vessels in man and the macaque monkey. Invest. Ophthal. 2: 1-15.

- Iwaki, S. (1958). The fine structure of the retinal pigment epithelium studied with the electron microscope. J. Kurume Med. Ass. 21: 1-21.
- Jacob, A. (1819). An account of a membrane in the eye, now first described. Phil. Trans. Roy. Soc. 109: 300-307.
- Jones, T.W. (1833). Notice relative to the pigmentum nigrum of the eye. Edin. Med. J. 40: 77-83.
- Keeney, A.H. (1951). Chronology of ophthalmic development. Springfield :Thomas.
- Kidd, M. (1962). Electron microscopy of the inner plexiform layer of the retina in the cat and the pigeon. J. Anat. 96: 179-188.
- Kiss, F. (1942). Der blutkreislauf des auges. Ophthalmologica. 106: 225-250.
- Kissen, A.T. and Bloodworth, J.M.B. Jr. (1961). Ultrastructure of retinal capillaries of the rat. Exptl Eye Res. 1: 1-14.
- Kölliker, R.A. (1854). Mikroskopische anatomie, oder geweblehere des menschen. Leipzig : Engelmann.
- Kölliker, R.A. (1861). Entwicklungsgeschichte des menschen und der höheren thiere. Leipzig : Engelmann.
- Kroll, A.J. and Machemer, R. (1968). Experimental retinal detachment in the owl monkey. III Electron microscopy of retina and pigment epithelium. Amer. J. Ophthal. 66: 410-427.
- Kroll, A.J. and Machemer, R. (1969). Experimental retinal detachment in the owl monkey. V Electron microscopy of the reattached retina. Amer. J. Ophthal. 67: 117-130.

- Kuhne, W. (1879). Chemische Vorgänge in der Netzhaut. In Hermann, L. ed. Handbook de physiology. Leipzig : Vogel. vol. 3, pt. 1. 235.
- Kuwabara, T. and Cogan, D.G. (1960). Retinal vascular patterns I Normal architecture. Arch. Ophthal. (Chicago) 64: 904-911.
- Kuwabara, T. and Cogan, D.G. (1963). Retinal vascular patterns VI Mural cells of the retinal capillaries. Arch. Ophthal. (Chicago) 69: 492-502.
- Ladman, A.J. (1958). The fine structure of the rod-bipolar cell synapse in the retina of the albino rat. J. Biophys. Biochem. Cytol. 4 (pt. 2): 459-466.
- Ladman, A.J. (1961). Electron microscopic observations on the fine structure of Müller cells in the retina of the cat. Anat. Rec. 139: 247.
- Lasansky, A. (1967). The pathway between hyaloid blood and retinal neurons in the toad - structural observations and permeability to tracer substances. J. Cell Biol. 34: 617-626.
- Lasansky, A. and de Fisch, F.W. (1965). Studies on the function of the pigment epithelium in relation to ionic movement between retina and choroid. In Rohen, J.W. ed. The structure of the eye II. Stuttgart : Schattauer-Verlag. 139-144.
- Lasansky, A. and De Robertis, E. (1960). Electron microscopy of retinal photoreceptors. The use of chromatin following formaldehyde fixation as a complementary technique to osmium tetroxide fixation. J. Biophys. Biochem. Cytol. 7: 493-498.

- Laurens, H. and Detwiler, S.R. (1921). Studies on the retina.
The structure of the retina of Alligator mississippiensis
and its photomechanical changes. J. Exp. Zool. 32: 207-234.
- Leeson, T.S. (1968). The outer layer of the optic cup and
associated tissues. Canad. J. Ophthal. 3: 77-96.
- Leeson, T.S. and Leeson, C.R. (1966). The blood-retina barrier :
a study of the choriocapillaris and lamina elastica of the
rat. In. Uyeda, R. ed. Electron microscopy, 1966. Tokyo :
Maruzen. vol. 2: 513-514.
- Leeson, T.S. and Leeson, C.R. (1967). Choriocapillaris and lamina
elastica (vitrea) of the rat eye. Brit. J. Ophthal. 51: 599-616.
- Leure-~~du~~ Pree, A. (1968). Ultrastructure of the pigment epithelium
in the domestic sheep. Amer. J. Ophthal. 65: 383-398.
- Maeda, J. (1959). Electron microscopy of the retinal vessels.
Report 1, human retina. Jap. J. Ophthal. 3: 37-46.
- Magitot, A. (1910). Étude sur le developpement de la rétine
humaine. Ann. d'occul. (Brussels) 143: 241-282.
- Mann, I. (1928). The process of differentiation of the retinal
layers in vertebrates. Brit. J. Ophthal. 12: 449-478.
- Mann, I. (1964). The development of the human eye. 3rd ed.
London : Br. Med. Assoc.
- Matsusaka, T. (1967). The fine structure of the basal zone of
pigment epithelial cells of the chick retina as revealed by
different fixation procedures. Exptl. Eye Res. 6: 38-41.
- Meller, K. and Glees, P. (1965). The differentiation of neuroglia :
Müller cells in the retina of chick. Z. Zellforsch. 66: 321-332.

- Meyer, D.B. and Cooper, T.G. (1966). The visual cells of the chicken as revealed by phase contrast microscopy. Amer. J. Anat. 118: 723-734.
- Michaelson, I.C. (1948a). Vascular morphogenesis in the retina of the cat. J. Anat. 82: 167-174.
- Michaelson, I.C. (1948b). The mode of development of the retinal vessels and some observations of its significance in certain retinal diseases. Trans. Ophthal. Soc. U.K. 68: 137-180.
- Michaelson, I.C. (1954). Retinal circulation in man and animals. Springfield : Thomas.
- Mikawa, T. (1965). Electron microscopic observations on the lens and tunica vasculosa lentis of the human embryo. Acta. Soc. Ophthal. Jap. 69: 1463-1481.
- Mishima, Y. and Loud, A.V. (1963). The ultrastructure of un-melanized pigment cells in induced melanogenesis. Ann. N.Y. Acad. Sci. 100: 607-617.
- Missotten, L. (1960). Étude des synapses de la rétina humaine au microscope électronique. Proc. Europ. Reg. Conf. on Electron Microscopy. 2: 818-821.
- Missotten, L. (1965). The ultrastructure of the retina. Brussels : Arscia.
- Miyamoto, M. and Fitzpatrick, T.B. (1957). On the nature of the pigment in retinal pigment epithelium. Science 126: 449-450.
- Moody, M.F. and Robertson, J.D. (1960). The fine structure of some retinal photoreceptors. J. Biophys. Biochem. Cytol. 7: 87-92.

- Morris, V.B. and Shorey, C.D. (1967). An electron microscope study of the types of receptor in the chick retina. *J. Comp. Neurol.* 129: 313-340.
- Moyer, F.H. (1959). The fine structure of the developing melanin granule. *Anat. Rec.* 134: 612.
- Moyer, F.H. (1960). Electron microscopic observations on the origin, development and genetic variation of melanin granules. *Anat. Rec.* 136: 248.
- Moyer, F.H. (1961). Electron microscopic observations on the origin, development and genetic control of melanin granules in the mouse eye. In. Smelser, G.K. ed. *The structure of the eye*. New York : Academic.
- Müller, H. (1853). Ueber einige verhältnisse der netzhaut bei menschen and thieren. *Verhandl. d. Physik. Med. Gesell. Würzburg* 4: 96-100.
- Müller, H. (1856). Observations sur la structure de la rétine des certains animaux. *Cpt. Rend. Acad. Sci. (Paris)*. 43: 743-745.
- Mutlu, F. and Leopold, I.H. (1964a). The structure of human retinal vascular system. *Arch. Ophthal. (Chicago)* 71: 93-101.
- Mutlu, F. and Leopold, I.H. (1964b). The structure of fetal hyaloid system and tunica vasculosa lentis. *Arch. Ophthal. Chicago*) 71: 101-110.
- Nakaizumi, Y. (1964). The ultrastructure of Bruch's membrane. I Human, monkey, rabbit, guinea pig and rat eyes. *Arch. Ophthal. (Chicago)* 72: 380-387.

- Nakao, F. (1968). Electron microscopic studies of the retinal pigment epithelium. Part 1. "Coated vesicles" in the retinal pigment epithelial cells and Bruch's membrane of human eyes. *J. Jap. Ophthal. Soc.* 72: 221-231.
- Nilsson, S.E.G. (1964). An electron microscopic classification of the retinal receptors of the leopard frog (*Rana pipiens*). *J. Ultrastruct. Res.* 10: 390-416.
- Noell, W.K. (1958). Differentiation, metabolic organization and viability of the visual cell. *Arch. Ophthal. (Chicago)* 60: 702-733.
- Nunneley, T. (1858). On the structure of the retina. *Quart. J. Micr. Sci.* 6: 217-241.
- Okuda, K. (1965). The fine structure of the retina. *Folia. Ophthal. Jap.* 16: 177-181.
- Olney, J.W. (1968). An electron microscopic study of synapse formation, receptor outer segment development and other aspects of developing mouse retina. *Invest. Ophthal.* 7: 250-268.
- O'Rahilly, R. (1966). The early development of the eye in staged human embryos. *Contrib. Embryol. Carn. Inst.* 259: 1-42.
- O'Rahilly, R. and Meyer, D.B. (1959). The early development of the eye of the chick. *Acta. Anat.* 36: 20-58.
- Paik, K.K. and Chung, K.W. (1966). The development of the eye in the white rat. *Kor. J. Zool.* 9: 39-45.
- Parry, H.B. (1953). Degenerations of the dog retina I Structure and development of the retina of the normal dog. *Brit. J. Ophthal.* 37: 385-404.

- Pease, D.C. (1956). Infolded basal plasma membranes found in epithelium noted for their water transport. *J. Biophys. Biochem. Cytol.* 2 (Suppl.): 203-208.
- Pedler, C. and Tansley, K. (1963). The fine structure of the cone of a diurnal gecko (*Phelsuma inunguis*). *Exptl Eye Res.* 2: 39-47.
- Polyak, S. (1941). The retina. Chicago : Univ. of Chicago.
- Polyak, S. (1957). The vertebrate visual system. Chicago : Univ. of Chicago.
- Radnó¹, M. and Lovas, B. (1967). The ultrastructure of the synapses in the inner plexiform layers of the retina. *Acta. Opthal.* 45: 566-568.
- Radnó¹, M. and Lovas, B. (1968). Data on the ultrastructure of Müller's cells of the retina. *Arch. Soc. Amer. Oftal. Opton.* 6: 393-404.
- Ramon y Cajal, S. (1892). La rétina des vertébrés. *Cellule* 9: 119-259.
- Raviola, G. and Raviola, E. (1967). Light and electron microscopic observations on the inner plexiform layer of the rabbit retina. *Amer. J. Anat.* 120: 403-426.
- Remak, R. (1851). Untersuchungen über die entwickelung des wirbelthiers. Berlin : Reimer.
- Remak, R. (1854). Ueber den bau der retina und der ganglien. *Deutsche Klin.* 6: 177.
- Rhodin, J.A.G. (1962). The diaphragm of capillary endothelial fenestrations. *J. Ultrastruct. Res.* 6: 171-185.

- Ritter, C. (1864). Zur histologischen entwicklungsgeschichte des auges. Arch. f. Ophthal. (Graefe). 10: 61-79.
- Rochon-Duvigneaud, A. (1895). Précis iconographique d'anatomie normale de l'oeil (globe oculaire et nerf optique). Paris : Steinheil.
- Sauer, F.C. (1937). Factors in the morphogenesis of vertebrate embryo epithelia. J. Morph. 61: 563-579.
- Schultze, M. (1866). Zur anatomie und physiologie der retina. Arch. f. Mikr. Anat. 2 175-286.
- Schultze, M. (1972). Neue beiträge zur anatomie und physiologie der retina des menschen. Arch. f. Mikr. Anat. 7: 244-259.
- Seefelder, R. (1909). Untersuchungen über die entwicklung der netzhautgefäße des menschen. Arch. f. Ophthal. (Graefe). 70: 448-484.
- Seefelder, R. (1910). Beiträge zur histogenese und histologie der netzhaut, des pigment epithels und des sehneurven. Arch. f. Ophthal. (Graefe). 73: 419-537.
- Shakib, M. and de Oliveira, F. (1966). Studies on developing retinal vessels X Formation of the basement membrane and differentiation of intramural pericytes. Brit. J. Ophthal. 50: 124-133.
- Shakib, M., de Oliveira, F. and Henkind, P. (1968). Development of retinal vessels II Earliest stages of vessel formation. Invest. Ophthal. 7: 689-700.

- Sjöstrand, F.S. (1953a). The ultrastructure of the outer segments of rods and cones as revealed by the electron microscope. *J. Cell. Comp. Physiol.* 42: 15-44.
- Sjöstrand, F.S. (1953b). The ultrastructure of the inner segments of the retinal rods of the guinea pig as revealed by electron microscopy. *J. Cell. Comp. Physiol.* 42: 45-70.
- Sjöstrand, F.S. (1958). Ultrastructure of retinal rod synapses of the guinea pig eye as revealed by 3-D reconstructions from serial sections. *J. Ultrastruc. Res.* 2: 122-170.
- Sjöstrand, F.S. (1960). Electron microscopy of the retina. *Anat. Rec.* 136: 278.
- Sjöstrand, F.S. (1961). Electron microscopy of the retina. In: Smelser, G.K. ed. *The structure of the eye*. New York: Academic. 1-28.
- Sumita, R. (1961). The fine structure of Bruch's membrane of the human choroid as revealed by electron microscopy. *J. Electron Micro.* 10: 111-118.
- Sumita, R. (1963). Electron microscopic study of the choroid. Report II The fine structure of the choriocapillaris layer and the vascular layer. *Acta. Soc. Ophthal. Jap.* 67: 122-142.
- Tansley, K. (1933). The formation of rosettes in the rat retina. *Brit. J. Ophthal.* 17: 321-336.
- Tansley, K. (1951). Hereditary degeneration of the mouse retina. *Brit. J. Ophthal.* 35: 573-582.
- Tokuyasu, K. and Yamada, E. (1959). The fine structure of the retina studied with the electron microscope. IV Morphogenesis of the outer segments of retinal rods. *J. Biophys. Biochem. Cytol.* 6: 225-230.

- Valentin, G. (1837). Repertorium für anatomie und physiologie.
Bern : St. Gallen.
- Verhoeff, F.H. (1903). A hitherto undescribed membrane of the
eye and its significance. Roy. Lond. Ophthal. Hosp. Rep.
15: 309-319.
- Wallis, G.L. (1942). The vertebrate eye and its adaptive radiation.
Bloomfield Hills : Cranbrook.
- Weidman, T.A. and Kuwabara, T. (1968). Postnatal development
of the rat retina. An electron microscopic study. Arch.
Ophthal. (Chicago) 79: 470-484.
- Weyse, A.W. and Bruggess, W.S. (1906). Histogenesis of the retina.
Amer. Nat. 40: 611-637.
- Wolter, J.R. (1957). Perivascular glia of the blood vessels of
the human retina. Amer. J. Ophthal. 44: 766-773.
- Yamada, E. (1957). The fine structure of the retina studied with
the electron microscope. I The fine structure of the frog
retina. Kurume. Med. J. 4: 127-147.
- Yamada, E. (1960). Observations on the fine structure of the
photoreceptive elements in the vertebrate eye. J. Electron
Micros. 9: 1-14.
- Yamada, E., Tokoyasu, K. and Iwaki, S. (1958a). The fine structure
of the retina studied with the electron microscope. II
Pigment epithelium and capillaries of the choriocapillaris
layer. J. Electron Micr. 6: 42-46.

- Yamada, E., Tokoyasu, K. and Iwaki, S. (1958b). The fine structure of the retina studied with the electron microscope. III Human retina. J. Kurume Med. Assn. 21: 1979-2027.
- Young, R.W. (1965). Renewal of photoreceptor outer segments. Anat. Rec. 151: 484.
- Young, R.W. (1966). Further studies on the renewal of photoreceptor outer segments. Anat. Rec. 154: 446.
- Young, R.W. (1967). The renewal of photoreceptor cell outer segments. J. Cell. Biol. 33: 61-72.
- Young, R.W. (1968). Passage of newly formed protein through the connecting cilium of retinal rods in the frog. J. Ultrastruct. Res. 23: 462-473.