

Western University

Scholarship@Western

Department of Medicine Publications

Medicine Department

12-11-2023

Cognitive decline in thrombotic thrombocytopenic purpura survivors: The role of white matter health as assessed by MRI.

F Hannan

J Hamilton

C J Patriquin

K Pavenski

M T Jurkiewicz

See next page for additional authors

Follow this and additional works at: <https://ir.lib.uwo.ca/medpub>



Part of the [Medicine and Health Sciences Commons](#)

Citation of this paper:

Hannan, F; Hamilton, J; Patriquin, C J; Pavenski, K; Jurkiewicz, M T; Tristao, L; Owen, A M; Kosalka, P K; Deoni, S C L; Th  berge, J; Mandzia, J; Huang, S H S; and Thiessen, J D, "Cognitive decline in thrombotic thrombocytopenic purpura survivors: The role of white matter health as assessed by MRI." (2023).

Department of Medicine Publications. 332.

<https://ir.lib.uwo.ca/medpub/332>




Authors

F Hannan, J Hamilton, C J Patriquin, K Pavenski, M T Jurkiewicz, L Tristao, A M Owen, P K Kosalka, S C L Deoni, J Théberge, J Mandzia, S H S Huang, and J D Thiessen

ORIGINAL PAPER

Platelets, Thrombosis and Haemostasis

Cognitive decline in thrombotic thrombocytopenic purpura survivors: The role of white matter health as assessed by MRI

F. Hannan¹   | J. Hamilton¹ | C. J. Patriquin² | K. Pavenski³ | M. T. Jurkiewicz^{4,†} | L. Tristao⁴ | A. M. Owen^{5,6} | P. K. Kosalka⁷ | S. C. L. Deoni^{8,9,10} | J. Théberge^{1,4,10} | J. Mandzia⁵ | S. H. S. Huang^{1,7,10}  | J. D. Thiessen^{1,4,10}

¹Department of Medical Biophysics, Western University, London, Canada

²Department of Hematology, University Health Network, Toronto, Canada

³Department of Laboratory Medicine, St. Michael's Hospital, Toronto, Canada

⁴Department of Medical Imaging, Western University, London, Canada

⁵Department of Clinical Neurological Sciences, Western University, London, Canada

⁶Department of Physiology and Pharmacology and Department of Psychology, Western University, London, Canada

⁷Department of Medicine, Division of Nephrology, Western University, London, Canada

⁸Advanced Baby Imaging Lab, Rhode Island Hospital, Providence, Rhode Island, USA

⁹Department of Diagnostic Radiology, Warren Alpert Medical School at Brown University, Providence, Rhode Island, USA

¹⁰Lawson Health Research Institute, London, Canada

Correspondence

Shih-Han Susan Huang, 800 Commissioners Road East, Room A2-344, London, N6A 5W9 ON, Canada.

Email: shuang45@uwo.ca

Funding information

Answering TTP; Department of Medicine, Western University; Physicians' Services Incorporated Foundation

Summary

Immune-mediated thrombotic thrombocytopenic purpura (iTTP) is a rare condition caused by severe ADAMTS13 deficiency, leading to platelet aggregation and thrombosis. Despite treatment, patients are prone to cognitive impairment and depression. We investigated brain changes in iTTP patients during remission using advanced magnetic resonance imaging (MRI) techniques, correlating these changes with mood and neurocognitive tests. Twenty iTTP patients in remission (30 days post-haematological remission) were compared with six healthy controls. MRI scans, including standard and specialized sequences, were conducted to assess white matter health. Increased T1 relaxation times were found in the cingulate cortex ($p < 0.05$), and elevated T2 relaxation times were observed in the cingulate cortex, frontal, parietal and temporal lobes ($p < 0.05$). Pathological changes in these areas are correlated with impaired cognitive and depressive scores in concentration, short-term memory and verbal memory. This study highlights persistent white matter damage in iTTP patients, potentially contributing to depression and cognitive impairment. Key regions affected include the frontal lobe and cingulate cortex. These findings have significant implications for the acute and long-term management of iTTP, suggesting a need for re-evaluation of treatment approaches during both active phases and remission. Further research is warranted to enhance our understanding of these complexities.

KEYWORDS

cognitive impairment, depression, magnetic resonance imaging, myelin water imaging, thrombotic thrombocytopenic purpura

INTRODUCTION

Immune-mediated thrombotic thrombocytopenic purpura (iTTP) is a rare life-threatening disease caused by enzyme inhibition or clearance of ADAMTS13 (a disintegrin-like

and metalloprotease with thrombospondin type 1 repeats 13), which leads to platelet aggregation in the microvasculature.¹ The role of ADAMTS13, also known as von Willebrand factor cleaving protease, is to break down ultra-large von Willebrand factor multimers. During an acute iTTP episode,

[†]Deceased.

This is an open access article under the terms of the [Creative Commons Attribution-NonCommercial-NoDerivs](https://creativecommons.org/licenses/by-nc-nd/4.0/) License, which permits use and distribution in any medium, provided the original work is properly cited, the use is non-commercial and no modifications or adaptations are made.

© 2023 The Authors. *British Journal of Haematology* published by British Society for Haematology and John Wiley & Sons Ltd.

the activity of ADAMTS13 is severely decreased (<10%), causing rapid platelet aggregation, thrombosis and end-organ ischaemia.

Patients with immune-mediated thrombotic thrombocytopenic purpura (iTTP) are commonly treated with plasma exchange and immunosuppressants to restore platelet counts and ADAMTS13 activity.¹ Caplacizumab is used to speed up platelet count recovery and prevent complications.^{2,3} However, even after successful treatment, iTTP patients in remission can still face issues like cerebrovascular disease, cognitive problems and depression, and the reasons behind these problems are not clear.^{4,5} We recently conducted a pilot study looking at the blood–brain barrier in iTTP patients over 6 months.⁶ We found ongoing issues with blood–brain barrier (BBB) permeability in remission patients, which could be related to neuroinflammation.

Cognitive decline is also linked to changes in myelin, which is essential for brain function.⁷ We used advanced MRI techniques like myelin water imaging (MWI) to measure myelin content and integrity. Additionally, T1 and T2 relaxation time maps provided insights into tissue issues like demyelination,⁸ neuroinflammation⁹ and white matter oedema,¹⁰ which typically result in increased signal on these maps. Our use of multicomponent-driven equilibrium steady-state observations of T1 and T2 (mcDESPOT) MRI allowed us to create comprehensive brain maps for T1, T2 and MWF, giving a better understanding of the brain's condition in iTTP patients.¹¹

In this study, we aimed to better understand the microstructural changes in the white matter caused by iTTP in the brain. To further expand the pilot study on BBB permeability in patients with iTTP, we correlated MRI brain white matter changes with neurocognitive outcomes. Using mcDESPOT, we assessed the presence and extent of tissue pathology in a cohort of iTTP patients in remission. We can determine the localization of injuries and their effects on neurocognitive outcomes. We hypothesized that there would be a decrease in short-term memory and increased depression in patients with iTTP, and that these findings would coincide anatomically with damage seen on MRI.

METHODS

Study design

This was a multicentre study. Patients were enrolled at the London Health Sciences Centre (LHSC), University Health Network, Toronto and St. Michael's Hospital, Toronto. The imaging studies were conducted at St. Joseph's Health Care London (SJHC). All patients provided written informed consent before taking part in the study, and removal from participation was allowed at any point of the study. The study received ethics approval from Clinical Trials Ontario (Project ID: 1318).

Eligibility criteria

Patients were deemed eligible if they were ≥18 years of age with a diagnosis of iTTP and currently in remission. The diagnosis of iTTP required all of the following five criteria¹²: (1) platelet count <150 × 10⁹/L; (2) microangiopathic haemolytic anaemia (presence of anaemia and red blood cell fragmentation on blood film); (3) lactate dehydrogenase (LDH) >1.25 × the upper limit of normal (~190 units/L); (4) ADAMTS13 activity <10%; and (5) history of positive anti-ADAMTS13 antibody. ADAMTS13 activity and inhibitor levels were measured during their acute episodes. ADAMTS13 activity was measured by an enzyme-linked immunosorbent assay test with a normal range between 41% and 130%. Clinical remission is defined by sustained clinical response for at least 30 days without plasma exchange and/or immunosuppressants.¹³ Patients were excluded if they had an alternative diagnosis of thrombotic microangiopathy or secondary iTTP due to drugs or connective tissue disease. Healthy controls were enrolled on a voluntary basis (by poster or family members of the patients) and underwent screening to ensure their overall well-being prior to testing. All these patients are healthy, with a median age of 44 years old (range: 31–58) and no known medical history that would affect their cognitive tests or anatomical abnormalities on imaging tests. They are excluded if they have any history of hypertension, cardiovascular disease, diabetes, stroke or thrombotic microangiopathy.

Magnetic resonance imaging

MRI scans were conducted within 1 month of remission. Scans were acquired on a 3T MRI (Siemens Biograph mMR) with a 32-channel head-only receive coil at SJHC. The MRI protocol consisted of sequences based on a standard-of-care stroke protocol as well as quantitative sequences sensitive to white matter integrity.

The study used five standard imaging sequences to examine brain changes and detect abnormalities. T1-weighted images assessed general anatomy and atrophy; T2-weighted images identified acute issues like white matter hyperintensities; and diffusion-weighted images detected lesions such as strokes. Susceptibility-weighted images were used to find abnormal areas like chronic blood products, and magnetic resonance angiography evaluated extra-cranial vasculature. These images were interpreted by study radiologists (MJ and LT) without knowing whether the participant was a patient or a healthy volunteer to prevent bias. Analysis was performed using RadiAnt Viewer.¹⁴

Myelin water imaging (MWI) was used to analyse myelin integrity in vivo using the multicomponent-driven equilibrium single pulse observation of T1 and T2 (mcDESPOT) technique.¹¹ The technique is based on the observation that the T1 and T2 relaxation times of water protons in myelin

are different from those in other tissues, specifically intra/extra-cellular water and CSF. It uses a three-component model of tissue that accounts for the effects of multiple types of water protons to generate whole-brain T1-relaxation, T2-relaxation and myelin water fraction maps (MWF). MWF maps contain voxels ranging from 0 to 1, indicating the fraction of the signal belonging to myelin water.

Detailed methods for MRI sequence parameters and models are provided in the supplementary information.^{15–21}

Depression and cognitive testing

Depression and cognitive tests were conducted within 24h of the MRI scan. The depression assessment was conducted using the Montgomery-Åsberg Depression Rating Scale (MADRS), which is more sensitive to treatment effects as opposed to the commonly used Hamilton Rating Scale.¹⁶ MADRS consists of 10 categories: apparent sadness, reported sadness, inner tension, reduced sleep, reduced appetite, concentration difficulty, lassitude, inability to feel, pessimistic thoughts and suicidal thoughts. Each category is scored between 0 and 6, and the total of all categories represents the severity of depression. An online cognitive assessment was conducted via Cambridge Brain Sciences (CBS).¹⁷ The cognitive battery consists of 12 tests: Odd One Out, Spatial Span, Monkey Ladder, Grammatical Reasoning, Polygons, Token Search, Spatial Planning, Rotations, Digit Span, Feature Match, Double Trouble and Pair Associates. These tests measure either reasoning, short-term memory, verbal memory or concentration.¹⁸ Patient and study control results were compared to an age- and sex-matched cohort of >10 000 healthy persons provided by CBS. The participant's score is calculated within one standard deviation (SD), within two SD or more than two SD relative to normative data. Scores between one and two SD of controls signify mild changes, while scores greater than two are considered severe.

Statistical analysis

Means and SDs are reported for demographics. An *F*-test to check for variance equality was conducted between patients and controls, along with tests for normality for each metric derived from the quantitative maps. Depending on whether variances were equal or unequal, a Weiss' *t*-test or student's *t*-test was conducted between patients and healthy controls to test for significant ($p < 0.05$) increases or decreases. A chi-square test was conducted for categorical variables. All statistical analyses were conducted using the SPSS software version 27.¹⁹ SPM's imcalc function was used to generate Z-score maps for each metric.¹⁵ Maps were thresholded at $Z < -3.1$ for significant decreases and $Z > 3.1$ for significant increases ($p < 0.01$, confidence interval = 99%). Cognitive test domains and depression total scores were correlated with imaging regions using a spearman correlation. Correlations were reported if they were significant ($p < 0.05$).

RESULTS

Baseline characteristics

Twenty-two patients diagnosed with iTTP and six healthy controls were recruited between 2016 and 2021. Two patients were excluded due to anti-phospholipid syndrome and systemic lupus erythematosus. Study demographics are provided in Table 1. Patient clinical characteristics are provided in Table 2. All patients have a history of positive ADAMTS13 inhibitor level. There was a small proportion of patients with persistently low ADAMTS13. All patients had ADAMTS13 activity <10% at the time of diagnosis. At the time of their imaging studies (after treatment, while in remission), nine patients had ADAMTS13 activities >70%, seven had activities between 10%–70% and four had activities <10%. These cut-offs are used to determine the increased risk of stroke in iTTP patients.²⁰

Magnetic resonance imaging

Standard-of-care

Of the 20 patients, 16 (80%) had radiological findings. Fourteen of these patients had white matter hyperintensities (WMH) of variable size >2–15 mm. WMHs were commonly found in the frontal, subcortical and periventricular

TABLE 1 Demographics of patients and controls.

Demographic characteristics	Patients (N=20)	Controls (N=6)	<i>p</i>
Female, <i>n</i> (%)	16 (80)	3 (50)	0.146
Relapse, <i>n</i> (%)	5 (25)		
Age (years)			
Mean (SD)	48 (14)	44 (16)	0.745
Median (25th, 75th percentiles)	53 (36, 58)	44 (31, 58)	
Range	24–71	24–66	
Medical history, <i>n</i> (%)			
Glomerulopathy	0 (0)		
HIV	0 (0)		
Hypertension	2 (10)		
Transplantation/Stem cell	0 (0)		
Coronary artery disease	0 (0)		
Collagen vascular disease	0 (0)		
Cerebral vascular event	0 (0)		
Malignancy	0 (0)		
Venous thrombosis	0 (0)		
Smoking	6 (30)		
Other ^a	7 (35)		
None	7 (35)		

^aOther symptoms reported by patients include: Fibromyalgia, migraines, hypothyroidisms, diabetes, Epstein–Barr virus, chronic lymphocytic leukaemia, multilevel cervical degenerative disc disease or unspecified.

TABLE 2 Clinical characteristics of immune-mediated thrombotic thrombocytopenic purpura patients at baseline and month 0 (30 days post remission).

Clinical characteristics	Baseline (at diagnosis)	Study period (30 days post remission)	<i>p</i>
Platelet count, $\times 10^9/L$			
Mean (SD)	24 (17)	281 (79)	<0.001
Median (25th, 75th percentiles)	19 (11, 32)	290 (254, 329)	
Range	5–76	59–418	
Haemoglobin, g/L			
Mean (SD)	90 (17)	133 (10)	<0.001
Median (25th, 75th percentiles)	86 (78, 102)	131 (128, 141)	
Range	65–125	106–152	
ADAMTS-13 Activity, %			
Mean (SD)	2.4 (1.7)	51 (35)	<0.001
Median (25th, 75th percentiles)	1 (1, 4)	61 (13, 84)	
Range	1–5	1–94	
Lactate dehydrogenase, U/L			
Mean (SD)	895 (472)	216 (69)	<0.001
Median (25th, 75th percentiles)	757 (489, 1079)	201 (161, 248)	
Range	312–2256	137–413	
Treatments			
Therapeutic plasma exchange, <i>n</i> (%)	20 (100)		
Immunosuppressants, <i>n</i> (%)	20 (100)		
Prednisone	20 (100)		
Rituximab	12 (60)		
Caplacizumab	8 (40)		
Eculizumab	1 (5)		
Vincristine	2 (10)		
Cyclophosphamide	2 (10)		
Symptoms, <i>n</i> (%)			
Headache	9 (45)	0 (0)	<0.001
Confusion	5 (25)	0 (0)	0.017
Seizure	0 (0)	0 (0)	–
Decrease level of consciousness	1 (5)	0 (0)	0.311
Chest pain	2 (10)	0 (0)	0.147
Shortness of breath	3 (15)	0 (0)	0.072
Abdominal pain	2 (10)	0 (0)	0.147
Fever	0 (0)	0 (0)	–
Haematuria	1 (5)	0 (0)	0.311
Bleeding	1 (5)	0 (0)	0.311
Bruising	10 (10)	2 (10)	0.006
Other ^a	9 (45)	3 (15)	0.038
None	4 (20)	14 (70)	0.001

^aOther symptoms reported by patients include: Kidney pain, urinary tract infection, blood clots or unspecified.

regions. Other clinical findings included lacunar infarcts, outpouchings, aneurysms, atrophy and punctate foci of abnormal susceptibility across various regions. These were uncommon among patients. Healthy controls had no radiological findings. Patient findings are summarized in Table 3.

Myelin water imaging

Relative to healthy controls, there was a significant increase in T1 relaxation times in the cingulate cortex ($p < 0.05$) and a significant increase in T2 relaxation times in the cingulate cortex, frontal lobe, parietal lobe and temporal lobe ($p < 0.05$).

TABLE 3 Summary of radiological findings.

Patient	Age/sex	White matter Hyperintensities	Other radiological findings (SWI, DWI, TOF-MRA)
1	38F	3	–
2	35F	–	–
3	61M	1	Thrombus
4	54F	15–20	Punctate foci of abnormal susceptibility Lacunar infarct
5	67M	–	Lacunar infarcts (3)
6	25F	–	–
7 ^a	51F	5	Punctate foci of abnormal susceptibility Lacunar infarct (2)
8	31F	–	–
9	36F	–	–
10	56F	5	A1 segment is hypoplastic
11	57F	8	M1 segment outpouching (2)
12 ^a	48F	10+	A1 segment is hypoplastic
13	24F	–	Irregularity at the skull base
14 ^a	48F	2	–
15 ^a	71F	20+	Irregularity at the skull base 3 mm Aneurysm
16	28F	5	–
17	56M	10+	–
18	61F	3	–
19	59M	8–10	Bilateral susceptibility artefact
20 ^a	57F	12+	Foci of chronic microbleeds (4)

Abbreviations: DWI, diffusion-weighted imaging; SWI, susceptibility-weighted imaging; TOF-MRA, time-of-flight magnetic resonance angiography.

^aRelapse patient.

in the patients with iTTP. T1 relaxation time in the frontal lobe and MWF in the cingulate cortex approached significance ($p < 0.10$). Representative T1, T2 and MWF maps are shown in Figure 1. Figure 2 shows plots for mean values in patients compared with controls in the six brain regions: cingulate cortex, frontal lobe, insular lobe, occipital lobe, parietal lobe and temporal lobe. Regions with a significant increase/decrease ($p < 0.05$) are denoted with an asterisk (*) or stated otherwise.

Vowel-Wise Z-score

Red clusters in Z-score maps for T1 relaxation time and T2 relaxation time indicate significantly increased voxels ($Z \geq 3.1$) in patients with iTTP relative to healthy controls. Red clusters in Z-score maps for MWF indicate voxels that were significantly decreased ($Z \leq -3.1$) in patients with iTTP relative to healthy controls. Clusters of significantly increased voxels were found mainly in the subcortical and periventricular regions of the T1 maps, as expected from radiological findings. Clusters mainly reside in the cingulate and frontal regions, as found in myelin water imaging analysis. Numerous clusters of significantly increased voxels were

found throughout the brain for T2 maps, which also agreed with myelin water imaging results. Small clusters of significantly decreased voxels can be seen throughout the brain for MWF maps (See Figure 3).

Depression

All but one patient (19/20) underwent the depression test, categories with missing data were re-weighted accordingly. Concentration difficulties were the most common, with an average score of 1.75. From total scores, 12 patients (63%) showed no signs of depression (score between 0 and 6), 7 (37%) showed mild signs of depression (score between 7 and 19) and none of the patients showed moderate (score between 20 and 34) or severe (score > 34) signs of depression (See Figure 4). There was a significant positive correlation between depression total scores and T1-relaxation in the following regions: frontal ($R = 0.412$, $p = 0.041$) and insula ($R = 0.499$, $p = 0.011$). There was no significant correlation between T2 relaxation and the depression total score. There was a significant negative correlation between depression total scores and MWF in the insula ($R = -0.436$, $p = 0.029$).

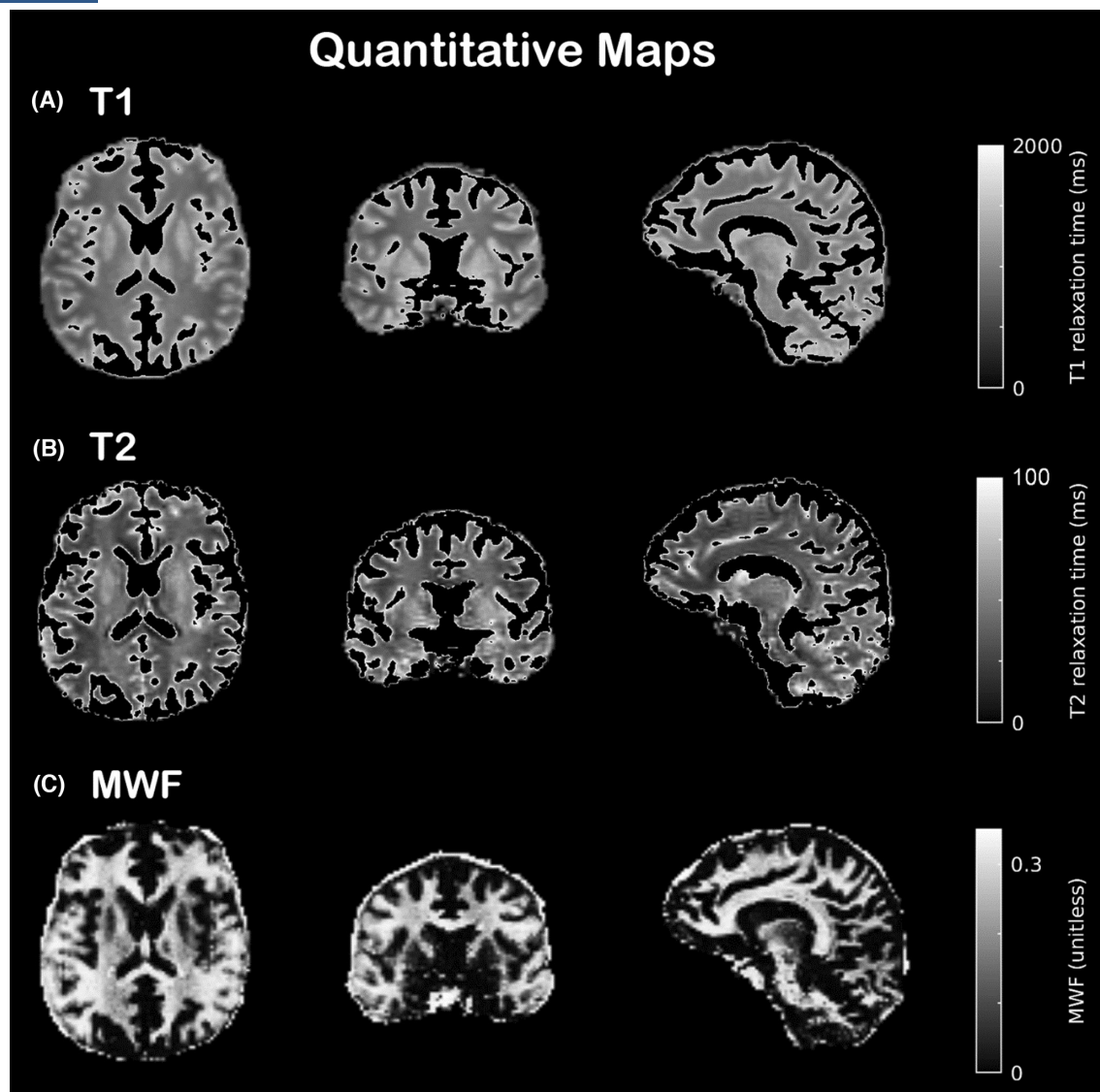


FIGURE 1 Representative axial, coronal and sagittal-oriented slices for quantitative magnetic resonance imaging maps. (A) T1 relaxation times; (B) T2 relaxation times; (C) myelin water fraction.

Cognitive testing

Twenty patients took the CBS cognitive assessment. If the patients missed any test(s) within the assessment, averages were re-weighted accordingly. Patients performed with scores less than 1 SD and/or 2 SDs compared to the healthy cohort from the database in all categories tested. Participants had reduced scores of more than 2 SD on tests of short-term memory (10 patients), verbal memory (10 patients) and concentration (12 patients). In comparison, the CBS results of the six healthy controls were within the normal range (See Figure 5).

DISCUSSION

In this study, significantly increased T1 and T2 relaxation times were found in iTTP patients when compared

to healthy controls. Increased T1 relaxation times were found in the cingulate cortex, and increased T2 relaxation times were found in the following lobes: the cingulate cortex, frontal, parietal and temporal lobes. While no significant MWF increases or decreases were found, the cingulate cortex had decreased MWF approaching significance ($p=0.07$). Decreased scores of less than 2 SDs were found in a variety of CBS tests when compared to a cohort of >10 000 age- and sex-matched controls, indicating a severe decrease. The changes in T1 and T2 signals appeared to be diffused. However, the cognitive changes related to short-term memory, verbal and concentration domains correlate with the MRI findings, as they were closely related to the signal changes on the frontal lobe and cingulate cortex.^{21,22} In contrast, our analysis of the study controls in comparison to the CBS-provided controls revealed only a sparse number of scores that fell below 1 SD. Notably, none of the scores exhibited a deviation beyond 2

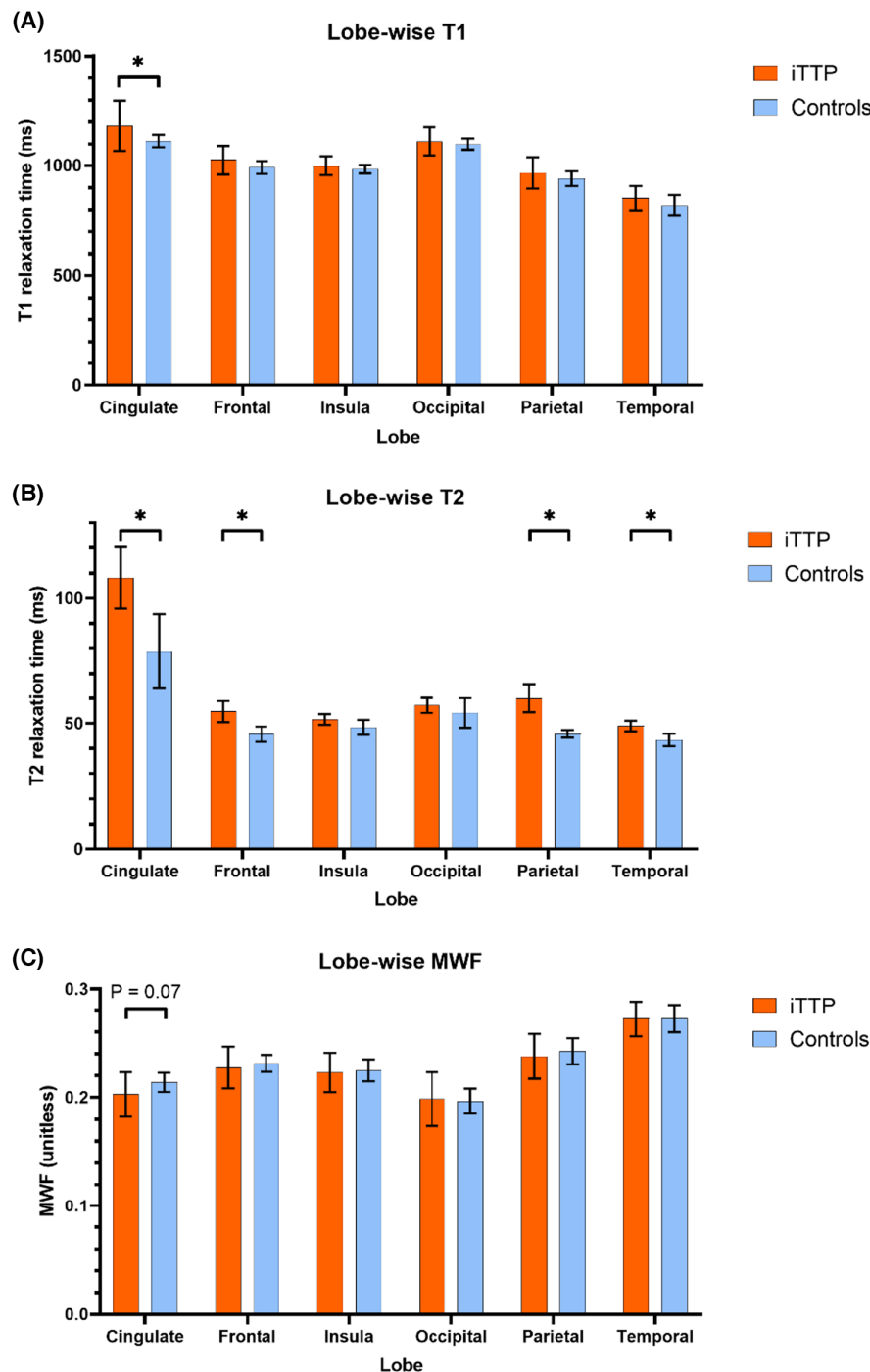


FIGURE 2 Lobe-wise averages for (A) T1 relaxation times; (B) T2 relaxation times; (C) myelin water fraction for patients (orange) and controls (blue). Statistically significant differences are denoted with (*) or otherwise stated.

SDs. Additionally, mild depressive symptoms occurred in seven iTTP patients (37%).

It is well known that neurocognitive changes frequently occur in iTTP patients in remission, previously reported in around 60% of cases^{4,23–25}; however, the underlying mechanism behind these changes is unclear. Our radiological findings found white matter hyperintense lesions in most patients, which is consistent with other MRI studies in iTTP.^{26–29} In particular, lesions were predominantly in the

frontal lobe, similar to findings by Alwan et al.²⁹; using MRI, they demonstrated the prevalence of white matter hyperintense lesions in patients with iTTP associated with an increased risk of cognitive impairment. Specifically, frontal executive functions, memory and general intellectual functioning were commonly affected alongside anxiety and depression. In our study, the blinded radiologist concluded that these WMHs were either indication of patients experiencing migraines or signs of small vessel

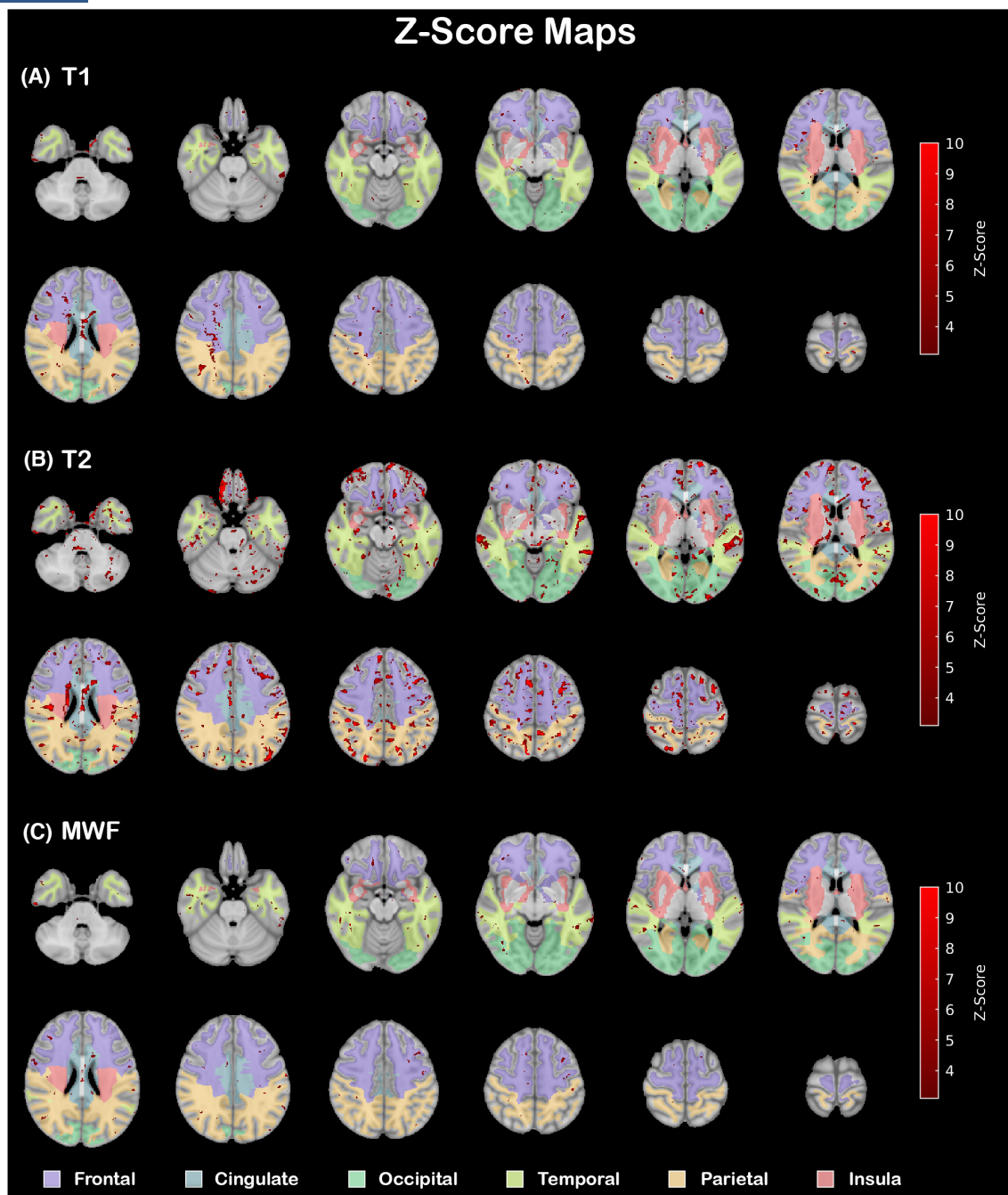


FIGURE 3 Z-score maps for quantitative metrics; (A) red regions signify areas of significant T1 relaxation time increases; (B) red regions signify areas of significant T2 relaxation time increases; (C) red regions signify areas of significant myelin water fraction decreases. Lobular regions are overlaid and colour coded.

ischaemic disease.³⁰ While this can be a common finding in older patients due to ageing, it is rare in younger patients, including our patient population with a mean age of 48 ± 14 years. A study by Wang et al. discovered a 26% prevalence of WMHs in healthy younger patients, whereas in our cohort, 44% of young patients exhibited WMHs, with the notable observation that the healthy controls showed no radiological findings.³¹ Frontal lesions were present in most patients, regardless of age, within the study, which may be due to the frontal lobe being more vulnerable to

ischaemic changes.³² Small-vessel ischaemic disease is commonly correlated with vascular risk factors and cognitive and motor impairment. As the disease progresses, it is associated with mental decline, strokes and cognitive-related diseases,³³ which may explain the depressive mood changes and decreased cognitive scores reported by our patients but is not conclusive. There were no statistically significant differences between patients who reported neurological symptoms at baseline and those who did not in terms of radiological abnormalities during remission.

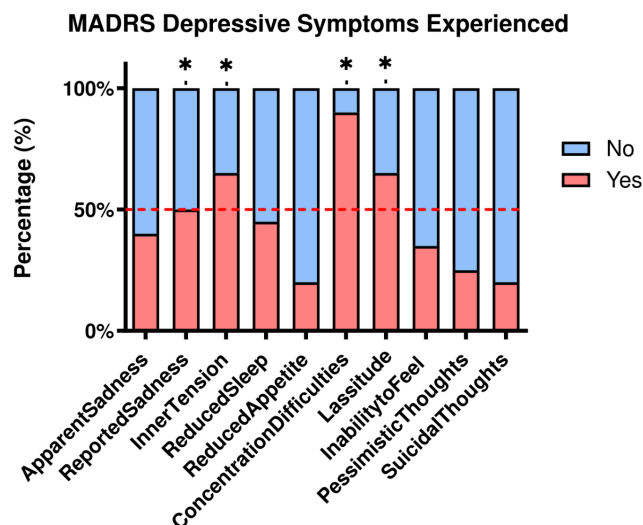


FIGURE 4 Summary of Montgomery-Åsberg Depression Rating Scale depression test findings. The red line indicates 50% of the participants.

CT perfusion findings from a previous study in iTTP found BBB disruption despite patients being in haematological remission.⁶ The exact reason for this remains undermined; however, clinical findings suggest vascular injury, such as a consequence from iTTP, could lead to damage of the blood–brain barrier and chronic leakage of fluid and macromolecules in the white matter.^{34,35} It is unclear if this injury heals over time or if there is progressive damage despite treatment. Another study on BBB integrity in HIV patients with thrombocytopenia found that platelets play a major role in affecting the intactness and permeability of the BBB by releasing chemokines and inflammatory mediators that alter endothelial cells.³⁶ Similarly, in patients with multiple sclerosis who have white matter lesions, there is breakdown of the BBB, attributed to cytokine/chemokines directly affecting endothelial cells and indirect chemokine-mediated injury.³⁷ As studied by Schwameis et al, thrombosis and inflammation are closely linked, and they can both cause and exacerbate each other.³⁸ Inflammation can lead to thrombosis by activating endothelial cells, platelets and leukocytes, which can promote the formation of microthrombi in small vessels. On the other hand, thrombosis can also cause inflammation by releasing pro-inflammatory mediators that can further activate endothelial cells and leukocytes. It is possible that iTTP with platelet aggregation and thrombocytopenia can similarly trigger this endotheliopathy in the brain.

T1 and T2 relaxation times depend on its structure and biochemical factors like density, water content, myelination, pH, etc.^{39–41} Changes in these factors are reflected in altered T1 and T2 times. In this study, increased T1 and T2 times suggest possible issues like neuroinflammation, white matter oedema or early demyelination. Identifying specific problems using T1 and T2 times alone is challenging, especially in patients with multiple issues. Our

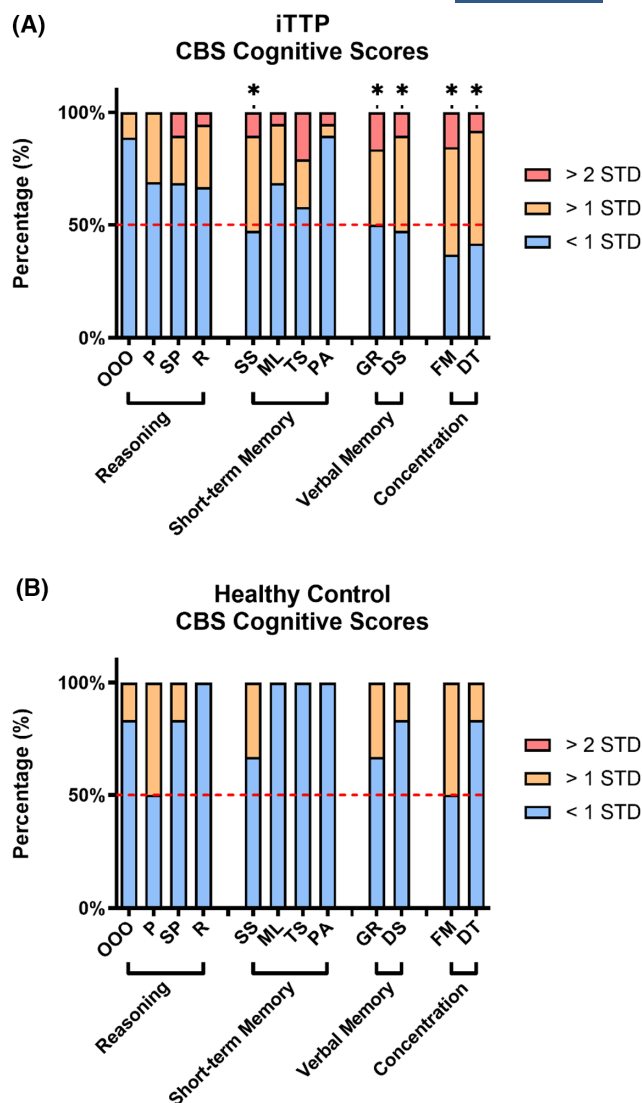


FIGURE 5 (A) Cambridge Brain Sciences (CBS) cognitive test findings for immune-mediated thrombotic thrombocytopenic purpura patients; (B) CBS cognitive test findings for controls. OOO, odds one out; P, polygons; SP, spatial planning; R, rotations; SS, spatial span; ML, monkey ladder; TS, token search; PA, pair associates; GR, grammatical reasoning; DS, digit span; FM, feature match; and DT, double trouble. The red dashed line represents 50% of the participants.

study found increased T1 and T2 times in the cingulate cortex, a brain region linked to emotions and behaviour regulation.^{42,43} This change might be related to reported symptoms like sadness, tension and lassitude, even though only 37% of patients showed mild signs of depression in assessments.

Despite not being able to determine the pathology present, this study did identify potentially afflicted, sensitive regions. To our knowledge, rehabilitation for cognitive function has not been documented in iTTP patients. However, some studies have used different forms of exercise to improve cognition in regions determined by this study.^{44–46} Of note, the impact of novel therapies such as caplacizumab and recombinant ADAMTS13, which may lead to a more

rapid correction of platelet count and pro-thrombotic environment, requires further study.^{2,47} In our study cohort, we also included eight patients who received caplacizumab during the initial treatment. We will conduct further studies to see if the impact of therapies, such as caplacizumab, can alleviate neurological complications. Furthermore, long-term preventative strategies, especially in patients with abnormal ADAMTS13, have not been thoroughly assessed and are needed. The efficacy of these treatments to reduce neurocognitive burden has also not been studied.

This study has limitations that should be acknowledged. First, the control group's sample size was small, potentially affecting the analysis's statistical power, ranging from 0.505 to 0.672. To achieve a reliable power of 0.80, a minimum of 39 patients and 12 controls are needed. Unfortunately, recruiting more patients is challenging due to the disease's rarity. Second, the age range of participants, especially those above 60, might introduce bias, as ageing alone can cause white matter changes. Third, the study lacked a standardized scale to classify white matter changes. Importantly, our findings do not fully explain the factors impacting cognitive function. Future research using longitudinal assessments, follow-up MRI and neurocognitive tests may provide insights into white matter injury progression. Techniques like diffusion tensor MRI and fibre tractography can reveal microstructural abnormalities and assess white matter integrity, offering valuable insights into cognitive disorders.^{48,49} Previous iTTP episodes might accumulate and influence brain function, potentially affecting neuroimaging results. This is crucial to acknowledge and could alter how we interpret the study's findings. While we do not have MRI on these patients' previous episodes, we are still recruiting and capturing data on relapsing patients. We may be able to look at this further in the future with more datasets. Additionally, investigating caplacizumab's efficacy in reducing post remission white matter injuries is a potential avenue for further exploration, given its rapid platelet normalization capabilities.

In conclusion, iTTP patients show increased T1 and T2 relaxation time in memory-related brain areas (cingulate cortex, frontal lobe) and white matter lesions indicating vessel issues. These findings suggest tissue problems linked to cognitive and mood issues, supported by testing and imaging correlations. This study connects neurocognitive regions with quantitative MRI, addressing overlooked depression and cognitive problems in iTTP. The paper highlights the importance of addressing these issues in treatment, suggesting that rehabilitation and intervention could prevent decline.

AUTHOR CONTRIBUTIONS

Shih-Han Susan Huang, Katerina Pavenski and Christopher J. Patriquin designed and conducted this pilot study. Jean Theberge and Jonathan D. Thiessen designed the imaging protocols and obtained the images. Sean C. L. Deoni developed and provided support for the imaging protocol. Michael T. Jurkiewicz and Leandro Tristao analysed the

imaging results. Jennifer Mandzia assisted in designing the study protocol. Adrian M. Owen provided assistance in cognitive testing. Fahad Hannan and Jeff Hamilton processed, analysed and interpreted the quantitative imaging data. Pauline K. Kosalka assisted in interpreting the data. All the authors contributed to the writing of the manuscript. All the authors provide intellectual content of critical importance to the work described and approve the version of the manuscript to be published.

ACKNOWLEDGEMENTS

This study received financial support from PSI and Answering TTP. We thank our MRI technologists, John Butler, Heather Biernaski and Yvonne Huston, for their help in acquiring all the imaging data, and Kerri Gallo for her help as a research coordinator.

FUNDING INFORMATION

Answering TTP, the Physicians' Services Incorporated (PSI) Foundation.

CONFLICT OF INTEREST STATEMENT

None. The results presented in this paper have not been published previously in whole or in part, except in abstract format.

DATA AVAILABILITY STATEMENT

For original data, please contact shuang45@uwo.ca.

ETHICS STATEMENT

The study received ethics approval from Clinical Trials Ontario (Project ID: 1318).

PATIENT CONSENT STATEMENT

All patients provided written informed consent before taking part in the study, and removal from participation was allowed at any point of the study.

PERMISSION TO REPRODUCE MATERIAL FROM OTHER SOURCES

Upon request.

CLINICAL TRIAL REGISTRATION NUMBER

NCT03187652.

ORCID

F. Hannan  <https://orcid.org/0009-0001-8321-683X>

S. H. S. Huang  <https://orcid.org/0000-0002-0848-130X>

TWITTER

F. Hannan  FHannanMP

REFERENCES

1. Kremer Hovinga JA, Coppo P, L'ammle B, Moake JL, Miyata T, Vanhoorelbeke K. Thrombotic thrombocytopenic purpura. *Nat Rev Dis Primers*. 2017;3(1):1–17.

2. Scully M, Cataland SR, Peyvandi F, Coppo P, Knöbl P, Kremer Hovinga JA, et al. Caplacizumab treatment for acquired thrombotic thrombocytopenic purpura. *N Engl J Med*. 2019;380(4):335–46.
3. Peyvandi F, Cataland S, Scully M, Coppo P, Knoebel P, Kremer Hovinga JA, et al. Caplacizumab prevents refractoriness and mortality in acquired thrombotic thrombocytopenic purpura: integrated analysis. *Blood Adv*. 2021;5(8):2137–41.
4. Deford CC, Reese JA, Schwartz LH, Perdue JJ, Kremer Hovinga JA, L'ammle B, et al. Multiple major morbidities and increased mortality during long-term follow-up after recovery from thrombotic thrombocytopenic purpura. *Blood*. 2013;122(12):2023–9.
5. Falter T, Schmitt V, Herold S, Weyer V, von Auer C, Wagner S, et al. Depression and cognitive deficits as long-term consequences of thrombotic thrombocytopenic purpura. *Transfusion*. 2017;57(5):1152–62.
6. Huang SHS, Pavenski K, Lee TY, Jurkiewicz MT, Bharatha A, Thiessen JD, et al. Blood–brain barrier permeability in survivors of immune-mediated thrombotic thrombocytopenic purpura: a pilot study. *Blood Adv*. 2021;5(20):4211–8.
7. Bouhrara M, Reiter DA, Bergeron CM, Zukley LM, Ferrucci L, Resnick SM, et al. Evidence of demyelination in mild cognitive impairment and dementia using a direct and specific magnetic resonance imaging measure of myelin content. *Alzheimers Dement*. 2018;14(8):998–1004.
8. Odrobina EE, Lam TY, Pun T, Midha R, Stanisiz GJ. MR properties of excised neural tissue following experimentally induced demyelination. *NMR Biomed*. 2005;18(5):277–84.
9. Stanisiz GJ, Webb S, Munro CA, Pun T, Midha R. MR properties of excised neural tissue following experimentally induced inflammation. *Magn Reson Med*. 2004;51(3):473–9.
10. Kleine LJ, Mulkern RV, Guttman CR, Colucci VM, Jolesz FA. In vivo characterization of cytotoxic intracellular edema by multicomponent analysis of transverse magnetization decay curves. *Acad Radiol*. 1995;2(5):365–72.
11. Deoni SC, Rutt BK, Arun T, Pierpaoli C, Jones DK. Gleaning multicomponent T1 and T2 information from steady-state imaging data. *Magn Reson Med*. 2008;60(6):1372–87.
12. George JN. Thrombotic thrombocytopenic purpura. *N Engl J Med*. 2006;354(18):1927–35.
13. Cuker A, Cataland SR, Coppo P, de la Rubia J, Friedman KD, George JN, et al. Redefining outcomes in immune TTP: an international working group consensus report. *Blood*. 2021;137(14):1855–61.
14. Medixant. RadiAnt DICOM Viewer. [cited 2022 Apr 25]. Available from: <https://www.radiantviewer.com>
15. Penny W, Ashburner J, Kiebel S, Henson R, Glaser D, Phillips C, et al. Statistical parametric mapping: an annotated bibliography. London: Wellcome Department of Imaging Neuroscience London, University College London; 2001.
16. Montgomery SA, Åsberg M. A new depression scale designed to be sensitive to change. *Br J Psychiatry*. 1979;134(4):382–9.
17. Hampshire A, Highfield RR, Parkin BL, Owen AM. Fractionating human intelligence. *Neuron*. 2012;76(6):1225–37.
18. Hampshire A, Highfield RR, Parkin BL, Owen AM. Supplemental information fractionating human intelligence. *Memory*. 2012;20(4):57.
19. IBM Corp. IBM SPSS Statistics for Windows. [cited 2022 Apr 25]. Available from: <https://www.ibm.com/spss>
20. Upreti H, Kasmani J, Dane K, Braunstein EM, Streiff MB, Shanbhag S, et al. Reduced ADAMTS13 activity during TTP remission is associated with stroke in TTP survivors. *Blood*. 2019;134(13):1037–45.
21. Chayer C, Freedman M. Frontal lobe functions. *Curr Neurol Neurosci Rep*. 2001;1(6):547–52.
22. Rolls ET. The cingulate cortex and limbic systems for emotion, action, and memory. *Brain Struct Funct*. 2019;224(9):3001–18.
23. Fiorani L, Vianelli N, Gugliotta L, Vignatelli L, Corbelli C, D'Alessandro R. Brain MRI and SPET in thrombotic thrombocytopenic purpura. *Ital J Neurol Sci*. 1995;16:149–51.
24. Han B, Page EE, Stewart LM, Deford CC, Scott JG, Schwartz LH, et al. Depression and cognitive impairment following recovery from thrombotic thrombocytopenic purpura. *Am J Hematol*. 2015;90(8):709–14.
25. Kennedy AS, Lewis QF, Scott JG, Kremer Hovinga JA, L'ammle B, Terrell DR, et al. Cognitive deficits after recovery from thrombotic thrombocytopenic purpura. *Transfusion*. 2009;49(6):1092–101.
26. Chaturvedi S, Yu J, Brown J, Wei A, Selvakumar S, Gerber GF, et al. Silent cerebral infarction during immune TTP remission: prevalence, predictors, and impact on cognition. *Blood*. 2023;142(4):325–35.
27. Neuman L, Joseph A, Bouzid R, Lescroart M, Mariotte E, Ederhy S, et al. Predictors of acute ischemic cerebral lesions in immune-mediated thrombotic thrombocytopenic purpura and hemolytic uremic syndrome. *J Neurol*. 2023;270(10):5023–33.
28. Bakshi R, Shaikh ZA, Bates VE, Kinkel PR. Thrombotic thrombocytopenic purpura: brain CT and MRI findings in 12 patients. *Neurology*. 1999;52(6):1285–8.
29. Alwan F, Mahdi D, Tayabali S, Cipolotti L, Lakey G, Hyare H, et al. Cerebral MRI findings predict the risk of cognitive impairment in thrombotic thrombocytopenic purpura. *Br J Haematol*. 2020;191(5):868–74.
30. Pohjasvaara T, Mäntylä R, Ylikoski R, Kaste M, Erkinjuntti T. Clinical features of MRI-defined subcortical vascular disease. *Alzheimer Dis Assoc Disord*. 2003;17(4):236–42.
31. Wang ML, Zhang XX, Yu MM, Li WB, Li YH. Prevalence of white matter hyperintensities in young clinical patients. *Am J Roentgenol*. 2019;213(3):667–71.
32. Chen Y, Chen X, Xiao W, Mok VC, Wong KS, Tang WK. Frontal lobe atrophy is associated with small vessel disease in ischemic stroke patients. *Clin Neurol Neurosurg*. 2009;111(10):852–7.
33. van Norden AG, de Laat KF, Gons RA, van Uden IW, van Dijk EJ, van Oudheusden LJ, et al. Causes and consequences of cerebral small vessel disease. The RUN DMC study: a prospective cohort study. Study rationale and protocol. *BMC Neurol*. 2011;11:1–8.
34. DeBette S, Markus H. The clinical importance of white matter hyperintensities on brain magnetic resonance imaging: systematic review and meta-analysis. *BMJ*. 2010;341:341.
35. Pantoni L. Pathophysiology of age-related cerebral white matter changes. *Cerebrovasc Dis*. 2002;13(Suppl. 2):7–10.
36. Nair M, Maria JM, Agudelo M, Yndart A, Vargas-Rivera ME. Platelets contribute to BBB disruption induced by HIV and alcohol. *J Alcohol Drug Depend*. 2015;3(1):182.
37. Minagar A, Alexander JS. Blood-brain barrier disruption in multiple sclerosis. *Mult Scler J*. 2003;9(6):540–9.
38. Schwameis M, Schörgenhofer C, Assinger A, Steiner MM, Jilka B. VWF excess and ADAMTS13 deficiency: a unifying pathomechanism linking inflammation to thrombosis in DIC, malaria, and TTP. *Thromb Haemost*. 2015;113(4):708–18.
39. Fatouros PP, Marmarou A, Kraft K, Inao S, Schwarz F. In vivo brain water determination by T1 measurements: effect of total water content, hydration fraction, and field strength. *Magn Reson Med*. 1991;17(2):402–13.
40. Lutti A, Dick F, Sereno MI, Weiskopf N. Using high-resolution quantitative mapping of R1 as an index of cortical myelination. *NeuroImage*. 2014;93:176–88.
41. Deoni SC. Quantitative relaxometry of the brain. *Top Magn Reson Imaging*. 2010;21(2):101–13.
42. Lichenstein SD, Verstynen T, Forbes EE. Adolescent brain development and depression: a case for the importance of connectivity of the anterior cingulate cortex. *Neurosci Biobehav Rev*. 2016;70:271–87.
43. Drevets WC, Savitz J, Trimble M. The subgenual anterior cingulate cortex in mood disorders. *CNS Spectr*. 2008;13(8):663–81.
44. Tao J, Liu J, Chen X, Xia R, Li M, Huang M, et al. Mind-body exercise improves cognitive function and modulates the function and structure of the hippocampus and anterior cingulate cortex in patients with mild cognitive impairment. *Neuroimage Clin*. 2019;23:101834.
45. Smith PJ, Sherwood A, Blumenthal JA. Effects of aerobic exercise on white matter hyperintensities: an exploratory analysis. *Gen Hosp Psychiatry*. 2018;53:84–5.
46. Shin MK. Effects of an exercise program on frontal lobe cognitive function in elders. *J Korean Acad Nurs*. 2009;39(1):107–15.

47. Scully M, Knöbl P, Kentouche K, Rice L, Windyga J, Schneppenheim R, et al. Recombinant ADAMTS-13: first-in-human pharmacokinetics and safety in congenital thrombotic thrombocytopenic purpura. *Blood*. 2017;130(19):2055–63.
48. Anjari M, Srinivasan L, Allsop JM, Hajnal JV, Rutherford MA, Edwards AD, et al. Diffusion tensor imaging with tract-based spatial statistics reveals local white matter abnormalities in preterm infants. *NeuroImage*. 2007;35(3):1021–7.
49. Rheault F, Houde JC, Descoteaux M. Visualization, interaction and tractometry: dealing with millions of streamlines from diffusion MRI tractography. *Front Neuroinform*. 2017;11:42.

How to cite this article: Hannan F, Hamilton J, Patriquin CJ, Pavenski K, Jurkiewicz MT, Tristao L, et al. Cognitive decline in thrombotic thrombocytopenic purpura survivors: The role of white matter health as assessed by MRI. *Br J Haematol*. 2023;00:1–12. <https://doi.org/10.1111/bjh.19246>