

4-1-2004

Measurement of Carotid Plaque Volume by 3-Dimensional Ultrasound

Anthony Landry
Robarts Research Institute

J. David Spence
Robarts Research Institute, jdspence@uwo.ca

Aaron Fenster
Robarts Research Institute

Follow this and additional works at: <https://ir.lib.uwo.ca/medpub>

Citation of this paper:

Landry, Anthony; Spence, J. David; and Fenster, Aaron, "Measurement of Carotid Plaque Volume by 3-Dimensional Ultrasound" (2004). *Department of Medicine Publications*. 291.
<https://ir.lib.uwo.ca/medpub/291>

Measurement of Carotid Plaque Volume by 3-Dimensional Ultrasound

Anthony Landry, BSc; J. David Spence, MD; Aaron Fenster, PhD

Background and Purpose—Measurement of carotid plaque volume and its progression are important tools for research and patient management. In this study, we investigate the observer variability in the measurement of plaque volume as determined by 3-dimensional (3D) ultrasound (US). We also investigate the effect of interslice distances (ISD) and repeated 3D US scans on measurement variability.

Materials and Methods—Forty 3D US patient images of plaques (range, 37.43 to 604.1 mm³) were measured by manual planimetry. We applied ANOVA to determine plaque volume measurement variability and reliability. Plaque volumes were measured with 9 ISDs to determine the effect of ISD on measurement variability. Additional plaque volumes were also measured from multiple 3D US scans to investigate repeated scan acquisition variability.

Results—Intraobserver and interobserver measurement reliabilities were 94% and 93.2%, respectively. Plaque volume measurement variability decreased with increasing plaque volume (range, 27.1% to 2.2%). Measurement precision was constant for ISDs between 1.0 and 3.0 mm, whereas plaque volume measurement variability increased with ISD. Repeated 3D US scan measurements were not different from single-scan measurements ($P=0.867$).

Conclusions—The coefficient of variation in the measurement of plaque volume decreased with plaque size. The volumetric change that must be observed to establish with 95% confidence that a plaque has undergone change is $\approx 20\%$ to 35% for plaques <100 mm³ and $\approx 10\%$ to 20% for plaques >100 mm³. Measurement precision was unchanged for ISDs <3.0 mm, whereas measurement variability increased with ISD. Repeated 3D US scans did not affect plaque volume measurement variability. (*Stroke*. 2004;35:864-869.)

Key Words: ultrasonography ■ carotid arteries ■ carotid artery diseases ■ carotid artery plaque ■ carotid stenosis

Measurement of carotid atherosclerosis burden and progression is an important tool for research and patient management. Studies of atherosclerosis encompass a broad range of phenotypes, including intima-media thickness, cross-sectional area of carotid plaque, carotid stenosis severity, plaque surface morphology, and plaque composition. Additionally, measurement of carotid plaque has been useful for risk stratification, evaluation of patient response to medical interventions,¹ evaluation of new risk factors,^{2,3} genetic research,^{4,5} and quantification of the effects of new therapies.⁶ Because many patients receive nonsurgical treatment, investigations involving quantification of plaque regression and progression are expanding.⁷⁻¹⁰

Conventional 2-dimensional (2D) ultrasound (US) has been useful in qualitative and quantitative assessments of plaque progression, morphology, and composition.^{1,5} Moreover, it has been shown that carotid plaque area and progression of plaque identified high-risk patients.¹ However, accurate assessment of plaque changes with 2D US is difficult because of the variability in the traditional 2D US examination.¹¹ Using conventional techniques, clinicians must localize a 2D US image plane in the body that is difficult to

reproduce, thereby making detailed monitoring of plaque changes with 2D US difficult.

Improved US techniques are required for accurate and reproducible monitoring of plaque changes. Improvements that hold promise are compound imaging,¹² which improves the definition of the plaque surface, and 3-dimensional (3D) US techniques, which improve 3D visualization and quantification of pathology.¹¹ 3D US has the potential to allow quantitative monitoring of plaque volume changes, which can provide accurate and reliable information about plaque response to therapy.^{6-10,13-18} Because carotid plaque progression is not limited to changes in 1 or 2 directions, measurements of plaque volume have the potential to be more sensitive to change than do measurements of plaque area, intima-media thickness, and carotid stenosis. For this reason, sample sizes required to test the effects of new therapies might be smaller for measurements of plaque volume than for traditional 2D measurements. With improved strategies to treat atherosclerosis nonsurgically, sensitive, noninvasive, 3D imaging techniques allowing direct plaque visualization and quantification of plaque features are becoming more important in serial monitoring of disease progression or regression.⁸

Received October 23, 2003; final revision received December 22, 2003; accepted December 24, 2003.

From the Imaging Research Laboratories, Robarts Research Institute, London, Ontario, Canada.

Correspondence to Aaron Fenster, PhD, Imaging Research Laboratories, Robarts Research Institute, PO Box 5015, 100 Perth Dr, London, Ontario, N6A 5K8, Canada. E-mail afenster@imaging.robarts.ca

© 2004 American Heart Association, Inc.

Stroke is available at <http://www.strokeaha.org>

DOI: 10.1161/01.STR.0000121161.61324.ab

Furthermore, studies of 3D plaque volume measurement allow for the possibility of investigating volume changes that occur in multiple dimensions, such as plaque surface morphology, plaque geometry, and plaque distribution.

In this article, we report on the intraobserver and interobserver variability in the measurement of carotid plaque volume by 3D US. We also explore the reliability and reproducibility of our experimental results and report on the effect of interslice distance (ISD) on the precision of our measurement technique. Finally, we investigate the variability in the measurement of plaque volume introduced from repeated 3D US scans.

Materials and Methods

Patient Data

Forty 3D US carotid plaque images were used in this study and were obtained from patients (23 men, 17 women; mean±SD age, 73.8±6.2 years; mean±SD carotid stenosis, 74±23%) who were being followed up in the Premature Atherosclerosis Clinic and the Stroke Prevention Clinic at the university campus of the London Health Sciences Centre, London, Ontario, Canada. Patients in the Premature Atherosclerosis Clinic were referred because of vascular disease not explained by usual risk factors such as age or because of a strong family history of vascular disease. Patients were referred to the Stroke Prevention Clinic because of a stroke or transient ischemic attack and in some cases, because of asymptomatic carotid stenosis.

Five or 6 3D US scans were performed of both the left and right carotid arteries of each patient, and the best 3D US images were selected for the study, based on optimal image quality (imaging artifacts, shadows, contrast, easily identifiable plaques, etc) and whether the plaques were contained entirely within the 3D US scan. Plaques were identified on the basis of visible changes in morphology where the local thickening of the intimal layer exceeded 1.0 mm. Plaques were also selected for the study to maximize the range of plaque volumes measured. Plaque geometry and distribution were not selection criteria for inclusion in the study.

Image Acquisition, Reconstruction, and Display

The 3D US images were acquired with a mechanical linear 3D scanning system (LIS Inc).¹¹ To produce 3D images, a transducer (50 mm; L12-5, Philips) was translated along the neck of the patient for ≈8 seconds for an approximate distance of 4.0 cm while video frames from an US machine (ATL HDI 5000, Philips) were digitized and saved to a computer workstation. The resulting transverse 2D images were parallel to each other, with a mean spatial interval (0.15 mm) and constant transducer angle ($\theta=0^\circ$). The 3D images were displayed using intersecting orthogonal planes by means of a reconstructed 3D volume that was available for viewing immediately after the scan.¹¹ Figure 1 shows carotid plaque images obtained by 3D US that have been sliced to reveal the plaque in multiple planes.

Plaque Volume by Manual Planimetry

Five observers were trained to identify and measure plaque volume with the 3D US images. Before making measurements, observers were instructed to manipulate the 3D US image in multiple orientations to familiarize themselves with the overall geometry and distribution of the plaque within the carotid vessel.

The 3D US images of plaque volumes were measured by manual planimetry, a method that has been investigated on test phantoms¹⁹ and patient anatomy.^{14,15} Each observer sliced the 3D image with an ISD of 1.0 mm from 1 end of the plaque to the other (along the vessel axis in the scan direction) and traced the individual plaque boundaries on the image plane by using a mouse-driven cross-hair cursor. The areas measured in each slice were summed and multiplied by the ISD (ie, slice thickness) to calculate total plaque volume. After measuring a plaque, each observer reviewed the 3D image to ensure that the set of measured plaque boundaries matched the plaque

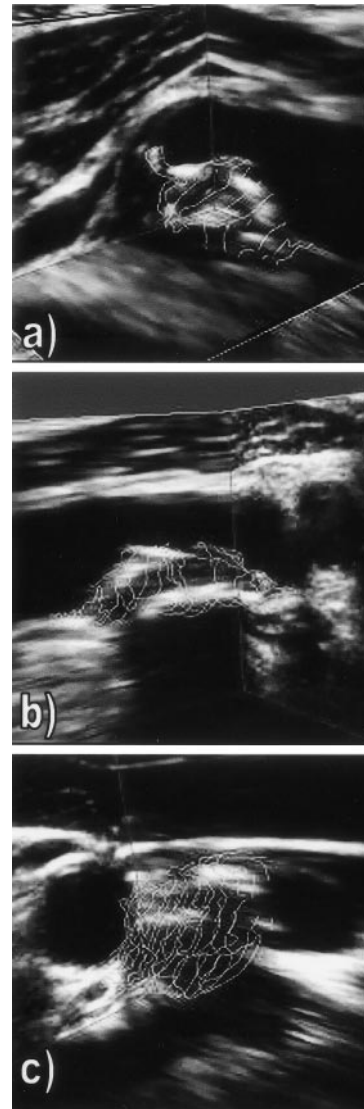


Figure 1. Carotid plaque images obtained with 3D US. The 3D image is viewed with a multiplanar reformatting approach and has been sliced to reveal the plaque in multiple orientations.

volume. Mismatches were adjusted by dragging the boundary to fit the correct contour. The outlining of a typical plaque, consisting of 10 to 30 slices, required <8 minutes. Figure 2 shows the process of volume determination by manual planimetry.

Study Protocol

Each observer was trained during several tutorial sessions to identify and measure plaque volume on 3D US images of carotid plaque. Subsequently, 3 studies (summarized in Table 1) were performed.

First we conducted a multiple-observer study to investigate observer variability in the measurement of plaque volume. Each of the 5 observers measured the volume of 40 plaques (range, 37.43 to 604.10 mm³) 5 times by using an ISD of 1.0 mm (multiple-observer study, Table 1). Second, we investigated the effects of ISD on the relative accuracy and variability of our plaque volume measurement technique. For this study, a single observer measured the volume of 5 plaques (range, 42.15 to 604.10 mm³) 5 times by using 9 ISDs ranging from 1.0 mm to 5.0 mm in 0.5-mm increments (single-observer Study, Table 1). Third, we investigated plaque volume measurement variability from repeated 3D US scans. In this study, the carotid arteries of 5 patients were each scanned 5 times, and a single observer

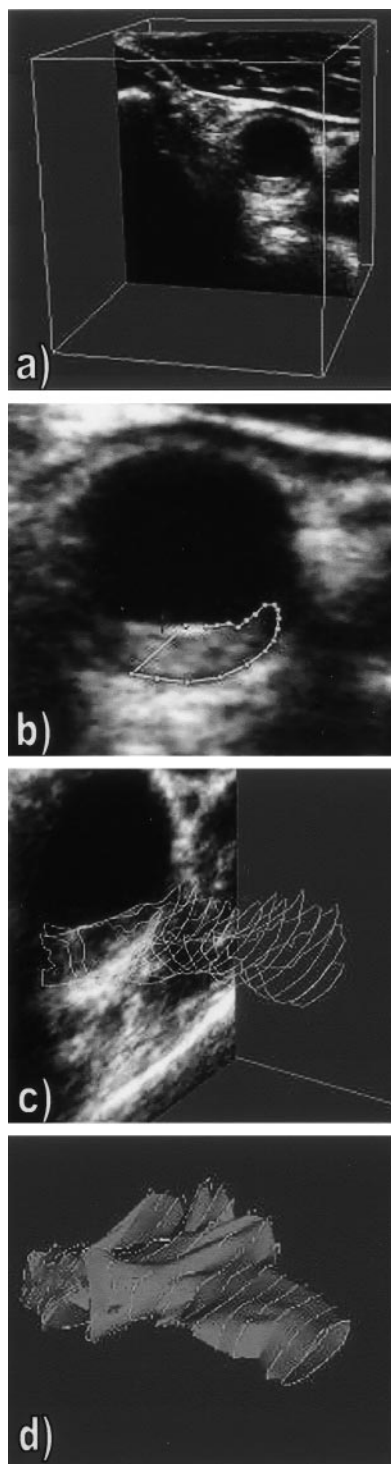


Figure 2. 3D US carotid plaque images showing the process of volume determination by manual planimetry: a, 3D US image of carotid plaque; b, manual outlining of a plaque slice boundary with a mouse-driven cross-hair cursor; c, successive plaque slice boundaries and axial plaque view; and d, outlined plaque volume and graphic isosurface.

measured the volume of each plaque (range, 23.90 to 522.50 mm³) 10 times by using an ISD of 1.0 mm (repeated scan study, Table 1). To avoid measurement bias that might result from plaque familiarity, the plaques investigated in all 3 studies were randomized and measured 2 to 3 weeks apart.

Statistical Analysis: Multiple Observer Study

With methods described by Eliasziw et al,²⁰ a 2-way, random-effects ANOVA was performed on the plaque volume measurements from the multiple-observer study. For the entire data set of measured plaque volumes as well as for subsets of the plaques (grouped by volume), we determined the standard errors of measurement (SEM), the minimum detectable changes in plaque volume ($\Delta V = Z_{\alpha} \sqrt{2SEM}$) detectable at the 95% confidence level ($\alpha = 0.05$, $Z_{\alpha} = 1.96$), and the coefficients of reliability (ρ) for intraobserver and interobserver measurements of plaque volume.

Results

Analysis of Variance

In the analysis of plaque volume measurement variability, we applied ANOVA to the entire data set as well as to 5 subsets (a, b, c, d, e) of the 40 plaques measured in the multiple-observer study and tabulated the results in Table 2. Each subset consisted of 7 or 8 plaques, which were grouped together by volume.

CV Versus Average Plaque Volume

Figure 3 is a plot of the intraobserver coefficient of variation (CV) (SD divided by the mean) in the measurement of plaque volume as a function of mean plaque volume for the 40 plaque volumes measured in the multiple-observer study (triangle). Figure 3 shows that as plaque volume increased, the CV in the measurement of plaque volume decreased. For the plaque volumes measured in this study (range, 37.43 to 604.10 mm³), the values for the intraobserver CV ranged from 19.2% to 1.9%. For the same range of plaque volumes, the interobserver CV ranged between 24.1% and 2.2%.

Variability of Repeated 3D US Scan Acquisitions

Figure 3 also shows the CV for the measurements of plaque volume made by repeated 3D US scans (open diamond). For the range of plaque volumes measured in the repeated scan study (range, 23.90 to 522.50 mm³), the CV ranged from 15.1% to 3.9% for the smallest to the largest plaque volumes measured. Measurements made from repeated 3D US scans were not different from measurements made from a single scan ($P = 0.867$).

Effects of ISD

To investigate the effect of ISD on relative plaque volume measurements, the mean measured volume of each plaque (as determined by the multiple-observer study) was used as a reference volume to normalize the plaque volumes of the single-observer study. Figure 4 shows that the relative plaque volume remained unchanged for ISDs between 1.0 and 3.0 mm and then decreased to 0.83 for increased ISDs up to 5.0 mm. The error bars in Figure 4 show that plaque volume measurement variability increased with ISD.

Discussion

Conventionally, the use of US in the carotid artery is limited to measurement of stenosis to determine whether a patient should undergo carotid endarterectomy. However, risk factors other than stenosis are prognostically important. Studies of atherosclerosis encompass a broad range of phenotypes, including clinical events such as stroke or myocardial infar-

TABLE 1. Study Protocol

Plaque Volume Study	Volume Range, mm ³	No. Plaques	No. Observers	No. 3D US Scans	No. Measurements/Plaque	ISD, mm	No. Plaque Volumes Measured
Multiple-observer study	37.43–604.10	40	5	1	5	1.0	1000
Single-observer study	42.15–651.23	5	1	1	5/ISD	1.0–5.0	225
Repeat-scan study	23.90–522.50	5	1	5	10/scan	1.0	250

ISD indicates interslice distance.

tion, transient ischemic attacks or unstable coronary syndromes, and measurements derived from noninvasive assays, such as lumenography, US, computed tomography, or magnetic resonance imaging.²¹ Noninvasive modalities can also measure different aspects of atherogenesis. For instance, US examination of the carotid arteries can provide determinations of intima-media thickness, the total cross-sectional area of carotid plaques, the total plaque volume, and the extent of carotid stenosis. Although each of these phenotypes assay “atherosclerosis,” they represent different stages of atherogenesis, which is a complex multistep process that has several physical, biochemical, molecular, and genetic determinants.²¹

Plaque progression is yet another distinct phenotype. Spence et al⁵ have shown that progression of plaque area is affected by different risk factors from baseline plaque and that these differences are more sensitive in evaluating genetic factors in atherosclerosis, because age, which accounts for half the variation in plaque explained in the regression model, does not explain progression. Spence et al¹ have explored the efficacy of tracking plaque regression and progression with 2D US by monitoring the sum of longitudinal cross-sectional areas of all plaques observed in the common, external, and internal carotid arteries on both sides (total plaque area). 3D US studies have also been undertaken to monitor the progression and regression of plaque. Hennerici et al²² performed serial prospective 3D US examinations of 4 flat and 17 soft carotid plaques during an average of 17 months in 7 patients with heterozygous hypercholesterolemia during heparin-induced extracorporeal LDL elimination on precipitation from plasma. By means of a quantitative 3D US analysis, significant plaque volume reduction was reported in all subjects, along with a marked reduction in total and LDL cholesterol and fibrinogen serum levels. Furthermore, Schminke et al⁸ sought to establish an in vivo method for visualizing structural changes in the carotid plaques in a prospective study involving 32 patients. After a mean of 18.9

months, carotid artery plaque progression had occurred in 15% of plaques, with plaque volume increasing by 59% in these cases. Plaque volume remained constant in 85% of cases.

Because carotid plaque progression is not limited to changes in 1 direction, it is important to measure progression in 3D. Barnett et al² have shown that plaque cross-sectional area increases 2.4 times faster than does plaque thickness. This phenomenon probably occurs because of the effects of arterial flow on plaque growth.²³ For this reason, sample sizes required to show effects of therapy are smaller for measurements of plaque area than for measurements of thickness, such as intima-media thickening.⁶ Therefore, it is very likely that measurement of plaque volume will be even more sensitive to change, because plaques grow and regress circumferentially as well as in length and thickness.

We have determined the observer variability in the measurement of plaque volume as a function of mean volume. Our values of 6.5% and 6.9% obtained for the intraobserver and interobserver measurement variability of the plaques investigated are comparable to the corresponding variability reported by Delcker et al,^{14–16} as well as the results obtained in vitro on plaque phantoms.¹⁹ In addition, coefficients of reliability in our study were similar to those reported by other investigators and very close to unity (see Table 2) for intraobserver and interobserver measurements, suggesting clinical utility.¹⁷ Although other investigators have measured plaque volume spanning a similar range as ours,^{17,18} our study differs in that we have reported the intraobserver and interobserver variabilities as a function of plaque volume.

We have also investigated the effect of ISD on plaque volume accuracy and variability. Figure 4 shows that relative plaque volume measurement remained unchanged for ISDs between 1.0 and 3.0 mm but then decreased for ISDs from 3.0 to 5.0 mm. In addition, we have found that measurement variability increased with ISD. In a previous article, we

TABLE 2. Summary of ANOVA Results for Multiple-Observer Study, Grouped in 5 Subsets by Volume

Plaque Subset	Plaque No.	V, mm ³	SEM _{inter} /V, %	SEM _{intra} /V, %	DV _{inter} , %	DV _{intra} , %	r _{inter}	r _{intra}
a	1–8	65.4	13.1	12.5	34.8	28.2	0.93	0.84
b	9–16	130.5	6.8	7.0	18.8	19.4	0.88	0.85
c	16–24	247.4	4.9	4.9	13.5	13.5	0.91	0.89
d	25–32	426.0	5.5	4.2	15.2	11.6	0.91	0.87
e	33–40	560.6	4.3	3.9	12.0	10.8	0.92	0.89
Global data	1–40	276.3	6.9	6.5	18.9	16.7	0.91	0.87

V indicates average volume measured; SEM, standard error in measurement; DV, minimum detectable volume change (between successive measurements with 95% confidence); r, coefficient of reliability (indicates measurement consistency and reproducibility relative to one).

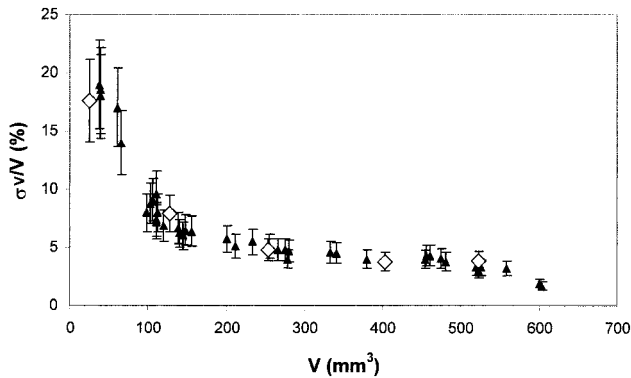


Figure 3. Intraobserver CV in the measurement of plaque volume as a function of mean plaque volume for the 40 plaques measured during the multiple-observer study (triangle) and the 5 plaque volumes measured in the repeated 3D US scan study (open diamond). Error bars represent 1 SD.

determined that the plaque volume measurement variability was dominated by variability in the determination of the initial and final slice locations (plaque edges).¹⁹ The initial slice location and the variability in the plaque boundary for each slice are not dependent on selection of the ISD. Therefore, the nonlinear relation between measurement accuracy and ISD (Figure 4) is a result of the inaccurate determination of the final edge of the plaque for ISDs >3.0 mm. Thus, our measurement technique systematically underestimates the plaque volume as the ISD exceeds 3.0 mm. Moreover, most 3D US images are formed by reconstructing a series of 2D image planes of known position. However, it must be noted that in many commercial and experimental 3D US systems, the 2D image planes are digitized by a frame grabber at a constant rate, which is independent of the rate of image acquisition, by the US machine. This approach might lead to decreased resolution in the reconstructed images.²⁴ Thus, the choice of spacing between consecutive images planes is important. If the spaces are large, resolution will suffer. However, narrowly spaced planes require more image planes, resulting in increased scan times. Because the acquired plane spacing was 0.15 mm, the resolution in the 3D US scan direction was not affected.²⁴

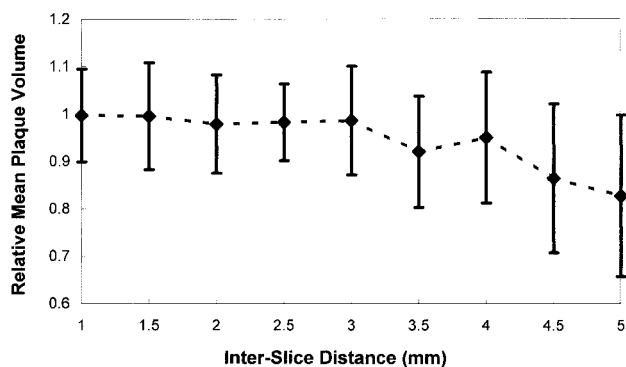


Figure 4. Relative mean plaque volume as a function of ISD for 5 plaque volumes measured by a single observer 5 times with each ISD investigated. Relative volume was constant for ISDs of 1.0 to 3.0 mm but then decreased to 0.83 for an ISD of 5.0 mm. Plaque volume measurement variability is shown by error bars, which represent 1 SD.

We have investigated the variability in the measurement of plaque volume by using repeated 3D US scans and found that the CVs determined from the measurement of plaque volume were not different for repeated 3D US scans than for measurements made from a single 3D US scan ($P=0.867$).

Using the results from Figure 3 and Table 2, we can quantify the change in plaque volume that must be observed to confidently determine whether a plaque has undergone change. For example, for a plaque with a volume of 250 mm³, we must measure a volume change of $\approx 14\%$ (Table 2) in a follow-up measurement to establish, with 95% confidence, that the plaque has undergone change and that the difference in measurement is not a result of observer variability. For the smaller plaques investigated in this study (volume <100 mm³), a volume change of $\approx 20\%$ to 35% must be measured to reliably determine that a plaque has undergone change. Thus, longer time periods will be required to observe changes in individual plaques.

Potential Contributions to Variability

Dropouts and shadowing, which are present owing to attenuation of the US beam, might be present in the reconstructed 3D US images. Thus, the plaque boundaries in the 3D US images of some of the plaques might not be well defined. This problem appears to be minimized by the Sono-CT capability of the equipment used, which includes views from several planes around the artery. Furthermore, in some instances, determining the location of the plaque boundary in contact with the vessel wall is difficult. Therefore, the exact selection of the boundary in the images varied, depending on the perception of each observer during the measurement process.

Although every effort was made to maintain a consistent measurement protocol among all observers, there might have been variability introduced by identification of the plaque itself. We have defined plaque as a measurable change in the vessel surface morphology when the intimal thickening exceeds 1.0 mm. This definition proved to be useful but did not overcome all of the plaque identification problems encountered. In some cases, it was difficult to determine the extent of the plaque in the vessel wall. Plaque identification at the carotid bifurcation and in areas of poor image resolution or in shadow also created some difficulty in plaque identification. Although the observers in this study were trained to follow the same measurement techniques, minor differences in plaque outlining strategies were still observed.

The variability of measurement can be partially influenced by carefully selecting operator-controlled parameters, such as the number of slices and the initial and final slice locations. However, the measurement process becomes more tedious. Outlining a plaque consisting of multiple slices takes ≈ 5 to 7 minutes. This process could be simplified by implementing algorithms for an automated or semiautomated segmentation of plaque volume.^{25,26} Our manual technique and the related theoretical description of plaque volume measurement variability¹⁹ could be used to investigate and refine the effectiveness of an automated or semiautomated technique.

Conclusions

Plaque volume can be measured accurately and reliably by 3D US. ANOVA revealed that the SE in the measurement of

plaque volume was dependent on plaque volume. Thus, the CV in the measurement of plaque volume decreased with increasing plaque size. The volumetric change that must be observed to establish with 95% confidence that a plaque has undergone change was $\approx 20\%$ to 35% for plaques $< 100 \text{ mm}^3$ and $\approx 10\%$ to 20% for plaques $> 100 \text{ mm}^3$. Plaque volume measurement precision is unchanged for ISDs $< 3.0 \text{ mm}$, whereas plaque volume measurement variability increased with ISD. Furthermore, measurements made on repeated 3D US scans were not different from measurements made on a single 3D US scan ($P=0.867$).

Acknowledgments

This work has been supported by the Canadian Institutes for Health Research, the Ontario R&D Challenge Fund, the Natural Sciences and Engineering Research Council of Canada, the Heart and Stroke Foundation of Ontario, and the Department of Medical Biophysics at the University of Western Ontario. A.F. holds a Canada Research Chair and acknowledges the Canada Research Chair Program. We thank Chris Blake, Congjin Chen, Jack Spence, and Jeremy Gill at the Robarts Research Institute for their participation and support in the technical aspects of this project. We also thank the plaque volume measurement operators for their diligent and patient work during data collection.

References

- Spence JD, Eliasziw M, DiCicco M, Hackam DG, Galil R, Lohmann T. Carotid plaque area: a tool for targeting and evaluating vascular preventive therapy. *Stroke*. 2002;33:2916–2922.
- Barnett PA, Spence JD, Manuck SB, Jennings JR. Psychological stress and the progression of carotid artery disease. *J Hypertens*. 1997;15:49–55.
- Spence JD, Sarquella-Brugada G, Zhao G, Brugada R, Marian AJ, Hegele R, Freeman D, Malinow MR. Homocyst(e)ine level but not MTHFR genotype predicts carotid atherosclerosis. *Atherosclerosis*. 1997;134:82–83.
- Hegele RA, Ban MR, Anderson CM, Spence JD. Infection-susceptibility alleles of mannose-binding lectin are associated with increased carotid plaque area. *J Invest Med*. 2000;48:198–202.
- Spence JD, Ban MR, Hegele RA. Lipoprotein lipase (LPL) gene variation and progression of carotid artery plaque. *Stroke*. 2003;34:1178–1182.
- Hackam DG, Peterson JC, Spence JD. What level of plasma homocyst(e)ine should be treated? Effects of vitamin therapy on progression of carotid atherosclerosis in patients with homocyst(e)ine levels above and below $14 \mu\text{mol/L}$. *Am J Hypertens*. 2000;13:105–110.
- Liapis C, Kakisis J, Papavassiliou V, Ntanou A, Kontopoulou S, Kaperonis E, Koumakis K, Gogas J. Internal carotid artery stenosis: rate of progression. *Eur J Vasc Endovasc Surg*. 2000;19:111–117.
- Schminke U, Motsch L, Griewing B, Gaull M, Kessler C. Three-dimensional power-mode ultrasound for quantification of the progression of carotid artery atherosclerosis. *J Neurol*. 2000;247:106–111.
- Serena J. Ultrasonography of the progression of atherosclerotic plaques. *Rev Neurol*. 1999;29:851–856.
- Norris JW, Bornstein NM. Progression and regression of carotid stenosis. *Stroke*. 1986;17:755–757.
- Fenster A, Downey DB, Cardinal HN. Three-dimensional ultrasound imaging. *Phys Med Biol*. 2001;46:67–99.
- Jespersen SK, Wilhelm JE, Sillesen H. Multi-angle compound imaging. *Ultrason Imaging*. 1998;20:81–102.
- Steinke W, Hennerici M. Three-dimensional ultrasound imaging of carotid artery plaques. *J Card Tech*. 1989;8:15–22.
- Delcker A, Diener HC. 3D ultrasound measurement of atherosclerotic plaque volume in carotid arteries. *Bildgebung*. 1994;61:116–121.
- Delcker A, Diener HC. Quantification of atherosclerotic plaque in carotid arteries by 3-dimensional ultrasound. *Br J Radiol*. 1994;67:672–678.
- Delcker A, Tegeler C. Influence of ECG-triggered data acquisition on reliability for carotid plaque volume measurements with a magnetic sensor 3-dimensional ultrasound system. *Ultrasound Med Biol*. 1998;24:601–605.
- Palombo C, Kozakova M, Morizzo C, Andreuccetti F, Tondini A, Palchetti P, Mirra P, Parenti G, Pantian NG. Ultra-fast 3-dimensional ultrasound: application to carotid artery imaging. *Stroke*. 1998;29:1631–1637.
- Griewing B, Schminke U, Morgenstern C, Walker ML, Kessler C. Three-dimensional ultrasound angiography (power mode) for the quantification of carotid artery atherosclerosis. *J Neuroimaging*. 1997;7:40–45.
- Landry A, Fenster A. Theoretical and experimental quantification of carotid plaque volume measurements made by 3-dimensional ultrasound using test phantoms. *Med Phys*. 2002;29:2319–2327.
- Eliasziw M, Young SL, Woodbury MG, Fryday-Field K. Statistical methodology for the concurrent assessment of interrater and intrarater reliability: using goniometric measurements as an example. *Phys Ther*. 1994;74:777–788.
- Hegele RA. The pathogenesis of atherosclerosis. *Clin Chim Acta*. 1996;256:21–38.
- Hennerici M, Kleophas W, Gries FA. Regression of carotid plaques during low-density lipoprotein cholesterol elimination. *Stroke*. 1991;22:989–992.
- Steinman DA, Thomas JB, Ladak HM, Milner JS, Rutt BK, Spence JD. Reconstruction of carotid bifurcation hemodynamics and wall thickness using computational fluid dynamics and MRI. *Magn Reson Med*. 2002;47:149–159.
- Smith WL, Fenster A. Optimum scan spacing for 3-dimensional ultrasound by speckle statistics. *Ultrasound Med Biol*. 2000;26:551–562.
- Mao F, Gill J, Downey D, Fenster A. Segmentation of carotid artery in ultrasound images: method development and evaluation technique. *Med Phys*. 2000;27:1961–1970.
- Zahalka A, Fenster A. An automated segmentation method for 3-dimensional carotid ultrasound images. *Phys Med Biol*. 2001;46:1321–1342.