

1-1-2019

Unexpected Gallbladder Metastasis of Clear Cell Renal Carcinoma

Ian White
Western University

Shane Smith
Western University

Kamilia Rizkalla
Western University

Edward Davies
Western University

Follow this and additional works at: https://ir.lib.uwo.ca/military_medicine

Citation of this paper:

White, Ian; Smith, Shane; Rizkalla, Kamilia; and Davies, Edward, "Unexpected Gallbladder Metastasis of Clear Cell Renal Carcinoma" (2019). *Office of Military Academic Medicine*. 3.
https://ir.lib.uwo.ca/military_medicine/3

Unexpected Gallbladder Metastasis of Clear Cell Renal Carcinoma

Ian White¹, Shane Smith² , Kamilia Rizkalla³ and Edward Davies²

¹Department of Physiology and Pharmacology, University of Western Ontario, London, ON, Canada. ²Division of General Surgery, London Health Sciences Centre, University of Western Ontario, London, ON, Canada. ³Department of Pathology and Laboratory Medicine, University of Western Ontario, London, ON, Canada.

Clinical Pathology
Volume 12: 1–3
© The Author(s) 2019
Article reuse guidelines:
sagepub.com/journals-permissions
DOI: 10.1177/2632010X19861112



ABSTRACT: Renal cell carcinoma (RCC) commonly metastasizes to areas such as the lungs, liver, bone, brain, adrenals, and lymph nodes. We present a rare case of a 59-year-old female patient with RCC metastasis to the gallbladder. The patient had undergone right nephrectomy for RCC more than 6 years prior to the metastasis. During routine follow-up, a polypoid lesion of the gallbladder was identified. Laparoscopic cholecystectomy was performed, and pathologic examination of the specimen revealed metastatic RCC. The patient was completely asymptomatic, which reinforces the importance of postoperative follow-up. Renal cell carcinoma is one of the few common malignancies for which there is good evidence of survival benefit from surgical resection of the metastatic tumours.

KEYWORDS: clear cell renal carcinoma, metastasis, gallbladder, metastatic renal cell carcinoma, gallbladder polyp

RECEIVED: May 15, 2019. **ACCEPTED:** June 10, 2019.

TYPE: Brief Report

FUNDING: The author(s) received no financial support for the research, authorship, and/or publication of this article.

DECLARATION OF CONFLICTING INTERESTS: The author(s) declared no potential conflicts of interest with respect to the research, authorship, and/or publication of this article.

CORRESPONDING AUTHOR: Shane Smith, Division of General Surgery, London Health Sciences Centre, University of Western Ontario, Rm. C8-114, 339 Windermere Road, London, ON N6A 5A5, Canada. Email: shane.smith@lhsc.on.ca

Introduction

Renal cell carcinoma (RCC) accounts for approximately 3% of all adult malignancies, and clear cell type represents about 70% of all RCC. It is well known for its high rate of metastasis, with approximately 30% of patients having metastatic disease at initial presentation, and another third of patients develop metastasis during follow-up.¹ We report a rare case of RCC, clear cell type, metastasizing into the gallbladder.

Case Report

A 59-year-old woman was admitted to the hospital with an upper pole mass in her right kidney. A right radical nephrectomy and caval thrombectomy were successfully performed and the patient was discharged. The patient enrolled in a blinded randomized controlled trial of the effects of adjuvant sunitinib/placebo or sorafenib/placebo in high-risk, non-metastatic RCC.² Due to some symptoms experienced by the patient, she was presumed to have been assigned to an active treatment arm.

The patient was performing extremely well with negative scans. Six years later, she complained of lower urinary tract symptoms and right flank pain. Kidney functions were normal; however, an ultrasound test showed a pedunculated, 2-cm lesion within the gallbladder body (Figure 1). The cause of the lesion was unclear, and surgery was offered because the lesion was greater than 1 cm in size. The preoperative differential diagnoses included gallbladder polyp, adenomyomatosis, and less likely gallbladder malignancy. The patient underwent an uncomplicated laparoscopic cholecystectomy.

Pathological examination showed a normal-sized gallbladder with an intact wall. On opening the gallbladder, a 1.1 cm polypoid tumour was attached to the mucosa. Microscopically,

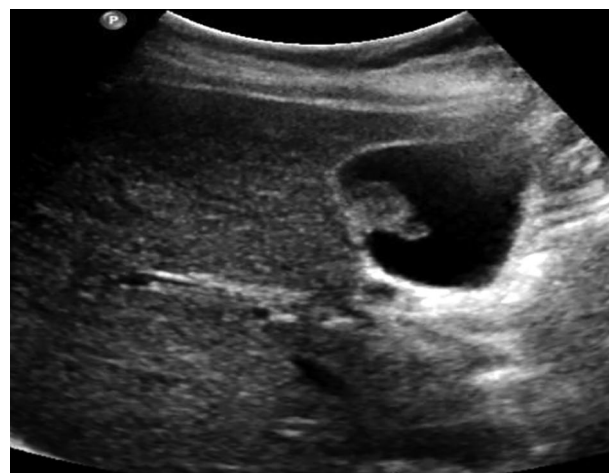

Figure 1. Ultrasound demonstrating a 2-cm pedunculated gallbladder polyp.

the lesion was composed of malignant clear cells with an overlying ulcerated epithelium (Figures 2 and 3). Immunohistochemistry showed positive staining of the neoplastic cells for vimentin, and cytokeratin AE1/AE3, and negative staining for cytokeratin 7 (Figures 4 and 5). The morphologic and phenotypic profiles were consistent with a metastasis from the patient's previous primary clear cell RCC. The cystic duct node was negative for malignancy. The patient has since been in good health.

Discussion

Metastases to the gallbladder (MGB) are very uncommon. There are case reports of multiple different malignancies that can metastasize to the gallbladder, usually in cases of diffuse



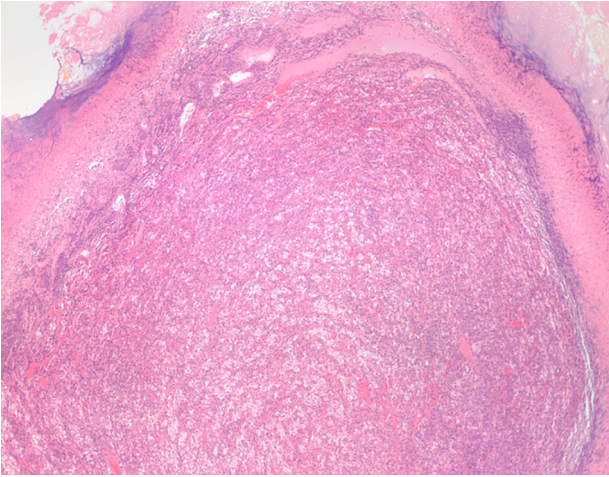


Figure 2. Low power view (40× magnification) of a cellular nodule within the gallbladder wall.

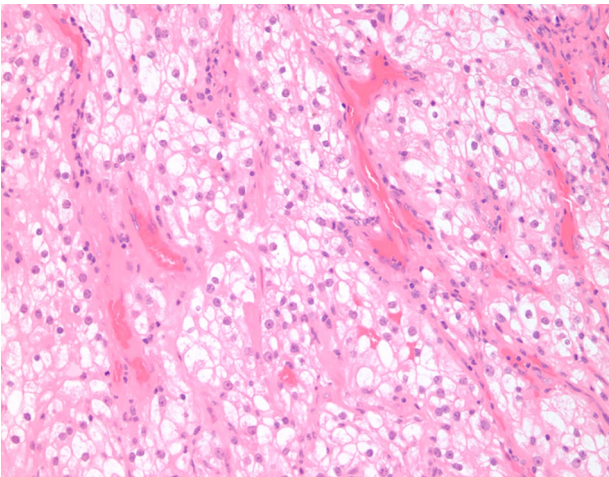


Figure 3. The 200× magnification illustrates the abundant clear cytoplasm, round nuclei, and prominent nucleoli nested within a capillary network. No sarcomatoid features were present in either primary or metastatic renal cell carcinoma.

metastasis. Isolated MGB are less common and have been described with primaries of gastric cancer, RCC, hepatocellular cancer, non-small cell cancer of the lung, and melanoma. In a review of computed tomography (CT) scan findings of metastasis to the gall bladder, Choi et al³ described a series of 24 patients with metastasis to the gall bladder. The most common primary tumour metastasized to the gallbladder was gastric cancer (n = 8), followed by RCC (n = 4) and hepatocellular carcinoma (n = 3). All gallbladder metastases (n = 21) presented either with infiltrative wall thickenings (n = 15) or as polypoid lesions (n = 6). Metastatic adenocarcinomas to the gallbladder presented as infiltrative masses with persistently enhancing wall thickenings, while non-adenocarcinomatous metastases usually presented as polypoid lesions with early wash-in and wash-out.³

Like many cancers, RCC has typical locations to which distant metastases occur: lungs, liver, brain, adrenals, and lymph nodes. Renal cell carcinoma, especially clear cell RCC, is also

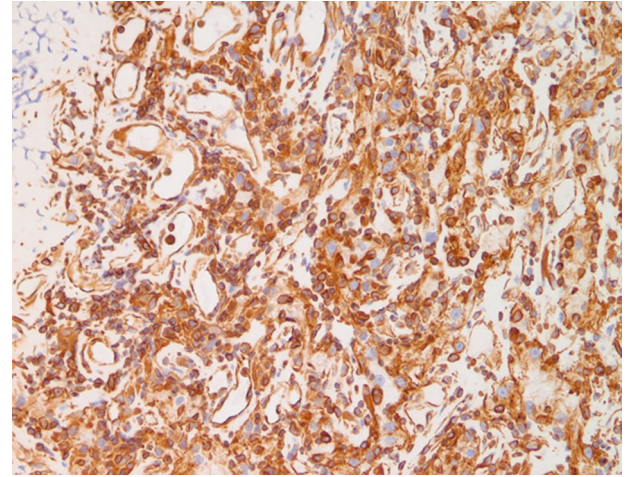


Figure 4. The neoplastic cells have cytoplasmic positivity for vimentin immunomarker, characteristic of renal clear cell carcinoma but uncommon in other carcinomas.

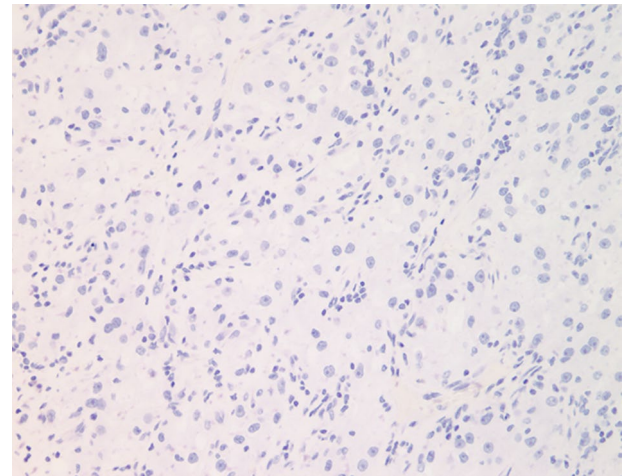


Figure 5. The neoplastic cells stain negatively for the cytokeratin marker CK7, which is positive in biliary tract and many other carcinomas, but characteristically negative in renal cell carcinoma.

well known to metastasize to unusual locations, sometimes decades after initial tumour treatment.⁴ It is unknown why metastases often present so late.⁴

Gallbladder metastases from RCC are very rare, although they have been previously described.^{5–9} Most present metachronously, with a median time to presentation of 5 years. There is one case report of a gallbladder metastasis presenting 27 years after the primary tumour.¹⁰ Some cases are only detected at post-mortem examination.¹¹ Most of such lesions are asymptomatic, although some may present as biliary colic or acute cholecystitis.⁸

Identification and resection of solitary/localized metastases from RCC has a proven survival benefit, and evidence of good outcomes after resection of gallbladder metastases has been published.^{12,13}


In the case of a patient with a current or past history of RCC, a symptomatic or incidental gallbladder lesion should raise the possibility of metastasis, and cholecystectomy for

diagnostic and therapeutic purposes is indicated. This case highlights RCC's propensity for metastasis to unusual locations, sometimes following a long disease-free interval.

Author Contributions

ED performed the surgery, KR performed pathological analysis, SS and IW performed literature review and drafted the manuscript. All authors reviewed and had input into the final manuscript.

ORCID iD

Shane Smith  <https://orcid.org/0000-0001-5612-6807>

REFERENCES

1. Barata PC, Rini BI. Treatment of renal cell carcinoma: current status and future directions. *CA Cancer J Clin.* 2017;67:507–524.
2. Haas NB, Manola J, Uzzo RG, et al. Adjuvant sunitinib or sorafenib for high-risk, non-metastatic renal-cell carcinoma (ECOG-ACRIN E2805): a double-blind, placebo-controlled, randomised, phase 3 trial. *Lancet.* 2016;387:2008–2016.
3. Choi WS, Kim SH, Lee ES, et al. CT findings of gallbladder metastases: emphasis on differences according to primary tumors. *Korean J Radiol.* 2014;15:334–345.
4. Richards KA, Abel EJ. Surveillance following surgery for nonmetastatic renal cell carcinoma. *Curr Opin Urol.* 2016;26:432–438.
5. Shyr BU, Chen SC, Shyr YM, Lee RC, Wang SE. Metastatic polyp of the gallbladder from renal cell carcinoma. *BMC Cancer.* 2017;17:244.
6. Costa Neves M, Neofytou K, Giakoustidis A, et al. Two cases of gallbladder metastasis from renal cell carcinoma and review of literature. *World J Surg Oncol.* 2016;14:87.
7. Chung PH, Srinivasan R, Linehan WM, Pinto PA, Bratslavsky G. Renal cell carcinoma with metastases to the gallbladder: four cases from the National Cancer Institute (NCI) and review of the literature. *Urol Oncol.* 2012;30:476–481.
8. Sand M, Bechara FG, Kopp J, Krins N, Behringer D, Mann B. Gallbladder metastasis from renal cell carcinoma mimicking acute cholecystitis. *Eur J Med Res.* 2009;14:90–92.
9. Jain D, Chopra P. Metastatic renal cell carcinoma of gall bladder. *Saudi J Kidney Dis Transpl.* 2013;24:100–104.
10. Aoki T, Inoue K, Tsuchida A, et al. Gallbladder metastasis of renal cell carcinoma: report of two cases. *Surg Today.* 2002;32:89–92.
11. Weiss L, Harlos JP, Torhorst J, et al. Metastatic patterns of renal carcinoma: an analysis of 687 necropsies. *J Cancer Res Clin Oncol.* 1988;114:605–612.
12. Ljungberg B. The role of metastasectomy in renal cell carcinoma in the era of targeted therapy. *Curr Urol Rep.* 2013;14:19–25.
13. Seeliger B, Callari C, Diana M, Mutter D, Marescaux J. Polypoid gallbladder lesion in the context of renal cell carcinoma: is laparoscopic cholecystectomy a reasonable option? *J Investig Med High Impact Case Rep.* 2013;1:2324709613499008.