

4-2011

# Heart Treatment in Ancient Egyptian Mummification

Andrew D. Wade

*The University of Western Ontario, awade4@uwo.ca*

Andrew J. Nelson

*The University of Western Ontario, anelson@uwo.ca*

Follow this and additional works at: <https://ir.lib.uwo.ca/anthropres>



Part of the [Archaeological Anthropology Commons](#)

---

## Citation of this paper:

Wade, Andrew D. and Nelson, Andrew J., "Heart Treatment in Ancient Egyptian Mummification" (2011). *Anthropology Presentations*.  
3.

<https://ir.lib.uwo.ca/anthropres/3>

# Heart Treatment in Ancient Egyptian Mummification

Andrew D Wade & Andrew J Nelson  
Department of Anthropology, University of Western Ontario

## Introduction

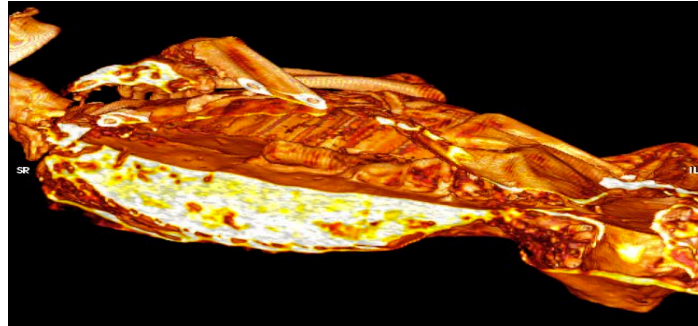
Descriptions in the popular and academic literature, of the treatment of the heart as part of the Egyptian mummification tradition, are derived from accounts by classical authors.

Our reliance on these normative descriptions, in the absence of Egyptian accounts, has obscured the wide range of mummification practices and the intrasocietal changes occurring in ancient Egypt. It has impeded the study of geographic, chronological, and socio-political variations in ancient Egyptian mortuary practice and ideology.

The goals of this study were to demonstrate:

- patterns of heart retention, removal, and replacement between
  - time periods
  - sexes
  - social statuses
- the relationship between classical descriptions and the patterns apparent in the empirical data

This study focuses on computed tomography (CT) as a non-destructive gold standard for mummies studies, and in the examination of heart treatment indications and variations with time, sex, and status.



**Ancient Sources:** The treatment of the viscera are discussed by Herodotus, Porphyry, and Plutarch without specific mention of the heart. The Ptolemaic Period Greek historian, Diodorus Siculus, is the only author to make explicit mention of the treatment of the heart. It from his account that modern stereotypes of heart treatment are formed; that is, that the heart was always retained or replaced if accidentally removed.

*When they have gathered to treat the body after it has been slit open, one of them thrusts his hand through the opening in the corpse into the trunk and extracts everything but the kidneys and heart, and another one cleanses each of the viscera, washing them in palm wine and spices. [1]*

**Radiological Appearance:** Among the structures present in the body cavity, the heart is among the most readily identifiable by its position. The heart, when it is retained in the chest, appears as a dense mass suspended in the pericardium (Fig. 1, left) [2,3,4]. The pericardium itself appears as a linear opacity, "a tent tethered between the sternum...thoracic spine" [5] and diaphragm (Fig. 2). The diaphragm and/or pericardium may remain in the heart's absence (Fig. 3, right).

## Samples

A sample of 150 dated mummies adequately described in the literature:

- 21 intact hearts
- 59 absent hearts
- 70 indeterminate/missing data

A sample of 7 mummies observed directly using computed tomography:

- 1: Redpath RM2718 – New Kingdom
- 2: ROM 910.5.3 – 21<sup>st</sup> Dynasty
- 3: Djedmaatesankh – 22<sup>nd</sup> Dynasty
- 4: Hetep-Bastet – 26<sup>th</sup> Dynasty
- 5: Pa-Ib – Late Period
- 6: Sulman Mummy – Ptolemaic Period
- 7: Lady Hudson – Roman Period

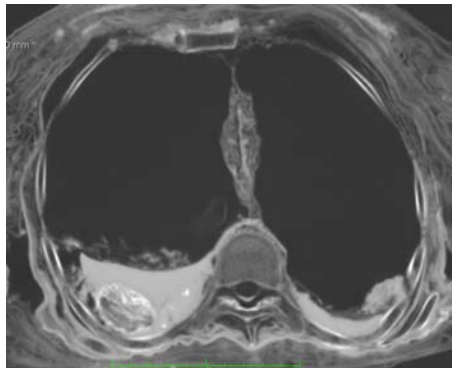


Figure 1. CT scan of the chest of RM2718, showing the heart intact in the pericardial sac, despite removal of the lungs and other organs.

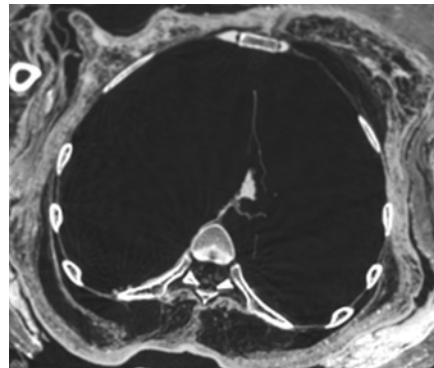


Figure 2. CT scan of the chest of ROM 910.5.3, showing remnants of the great vessels in the incised pericardium.

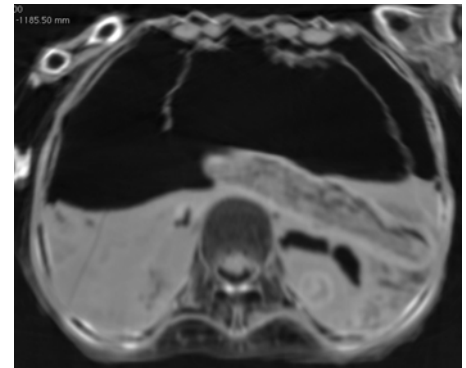


Figure 3. CT scan of the chest of Pa-Ib, showing the remnants of the incised diaphragm in the absence of the heart. (Sectioned 3D Reconstruction Above)

## Heart Treatment Trends...

The heart was noted as intact in only 21 of the 80 individuals where this organ's disposition was recorded. In barely more than a quarter of the individuals in this sample was the heart retained *in situ*. In only one case was the heart possibly sewn back into place, and in one other case was a heart scarab present, presumably to replace the removed heart.

Where descriptions permitted, the sample was considered with respect to status, divided coarsely into Elite and Commoner remains, following Kemp's three status groups: "literate men...those subordinate to them (doorkeepers, soldiers, quarrymen, and so on), and the illiterate peasantry" [6] who were not mummified. The heart was noted as intact, specifically in elites, as early as the Middle Kingdom, in this sample.

Male retention and absence of the heart preceded female heart retention and absence, respectively. The incidence of heart retention increased initially over time, but prevalence decreased beginning in the New Kingdom and especially in the Third Intermediate Period (Fig. 4).

With the heart enclosed in its pericardial sac and connected by six major vessels, in addition to the pulmonary veins and arteries severed in lung removal, it is fanciful to consider the possibility of it being accidentally removed by a slip of the scalpel; more so when such accidents would have to occur in nearly seven of every ten cases, followed by the loss of the organ in more than 98% of those cases.

That heart absence has coincided with lung retention in four cases further condemns the case for accidental excision.

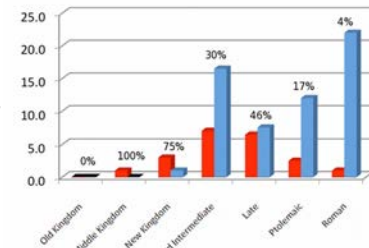


Figure 4. Graph showing the incidence of heart retention (red) and removal (blue). The retention prevalence is noted as a percentage.

## ...vs. Classical Norms

Rather than supporting the classical norm of universal heart retention, the distributions observed here are in agreement with heart retention as a privilege of the elite, remaining so even following the demotisation of mummification in the New Kingdom.

Retention of the heart peaked in incidence in the Third Intermediate Period, at the same time as the dramatic increase in evisceration following mummification's demotisation, and declined steadily until the Roman Period (Fig. 4).

Removal of the heart is identified among males by the New Kingdom and among females by the Third Intermediate Period. **Mummies were increasingly absent their hearts from the New Kingdom onward** (Fig. 4).

It is likely that retention of the heart began among the male elite, as all privileges tended to begin [7,8] and as befits its importance as the seat of intelligence and emotion. As time progressed, the nobles gained increasing access to mummification and retained their hearts. With the demotisation of mummification, however, the **commoners being mummified were not receiving the same treatment, possibly to ensure that the elite maintained a more favourable afterlife than their subjects.**

## Conclusions

The stereotype of universal heart retention, or replacement on accidental removal, is far from the truth. The heart was uncommonly retained *in situ*, and rarely returned or replaced by a heart scarab. The hypothesis constructed from the stereotyped account by Diodorus is, therefore, falsified by these data. This supports previous work [9] refuting the normative brain treatment accounts of Herodotus.

The classical descriptions should only be considered as, at best, a possible snapshot of mummification performed by one particular workshop; a snapshot that does not express the full range of variation in the practice throughout the entirety of Egypt over the course of three millennia, nor necessarily even the period in which the account was written.

## IMPACT Mummy dBase

Currently, an international, collaborative radiographic mummy database, is being established by the authors at Western to undertake large-scale radiological studies of variability in patterns of health and disease and in mummification practices in Egyptian and other mummies.

## Literature Cited

- [1] Diodorus Siculus. 1933. Library of history. Loeb classical library edition, transl. by CH Oldfather. Cambridge: Harvard University Press. Bk 1, para 91.
- [2] Smith GE, Wood-Jones F. 1910. The archaeological survey of Nubia. Report for 1907-1908. Volume II: Report on the human remains. Cairo: National Printing Department.
- [3] Rideout DF. 1977. Autopsy of an Egyptian mummy (NAkht - ROM I); 2. Radiologic examination. Canadian Medical Association Journal 117:463.
- [4] Aufderheide AC, Cartmell L, Zions M. 2004. Bio-anthropological features of human mummies from the Kellis 1 cemetery; The database for mummification methods. In: Bowen GE, Hope CA, editors. The oasis papers 3: Proceedings of the third international conference of the Dakkheh Oasis Project. Oxford: Oxbow Books. p.137-151.
- [5] Scott JW, Home PD, Hart GD, Savage H. 1977. Autopsy of an Egyptian mummy (NAkht - ROM I); 3. Gross anatomic and miscellaneous studies. CMAJ 117:464.
- [6] Kemp B.J. 1983. Old Kingdom, Middle Kingdom and Second Intermediate Period c. 2686-1552 BC. In: Trigger BG, Kemp BJ, O'Connor D, Lloyd AB, editors. Ancient Egypt: A social history. Cambridge: Cambridge University Press. p.84
- [7] Smith GE, Dawson WR. 1924. Egyptian mummies. London: George Allen & Unwin Ltd.
- [8] Strouhal E. 1992. Secular changes of embalming methods in ancient Egypt. Proceedings of the I World Congress on Mummy Studies, p.859-866.
- [9] Wade AD, Garvin GJ, Nelson AJ. A synthetic radiological study of brain treatment in ancient Egyptian mummies. Submitted to the Journal of Comparative Human Biology.

## Acknowledgments

The authors wish to thank Gerald Conlogue and Ronald Beckett of Quinipiac University; Stephanie Holowka of Toronto's Sick Kids Hospital; Barbara Lawson of the Redpath Museum; Roberta Shaw, Gayle Gibson and Mark Trumpp of the Royal Ontario Museum; and Audrey Genois and Marie-Eve Beauger of the Université du Québec à Montréal for access to scans and opportunities to scan the mummies at their institutions. We thank the St. Joseph's Health Care, London Health Sciences Centre, University of Ottawa Heart Institute, and Ottawa Hospital radiology departments for their assistance and guidance. Funding for this project was provided by a SSHRC Doctoral Canada Graduate Scholarship (ADW), a France and Araki Desmarais Ontario Graduate Scholarship (ADW), a Western Graduate Thesis Research Award (ADW), and a University of Western Ontario Faculty Scholar Grant (AJN). The ROM scans were funded by the Office of Social Science, the Schulich School of Medicine and Dentistry, and the Vice President, Research at UWO.

## For further information

Please contact [awade@uwo.ca](mailto:awade@uwo.ca)  
Andrew Wade,  
Department of Anthropology,  
Social Science Centre,  
University of Western Ontario,  
London, ON, N6A 5C2

