
Electronic Thesis and Dissertation Repository

6-29-2015 12:00 AM

An fMRI Study of Command Following and Communication Using Overt and Covert Motor Responses: Implications for Disorders of Consciousness

Natalie R. Osborne, *The University of Western Ontario*

Supervisor: Dr. Adrian Owen, *The University of Western Ontario*

A thesis submitted in partial fulfillment of the requirements for the Master of Science degree in Psychology

© Natalie R. Osborne 2015

Follow this and additional works at: <https://ir.lib.uwo.ca/etd>



Part of the [Psychology Commons](#)

Recommended Citation

Osborne, Natalie R., "An fMRI Study of Command Following and Communication Using Overt and Covert Motor Responses: Implications for Disorders of Consciousness" (2015). *Electronic Thesis and Dissertation Repository*. 3032.

<https://ir.lib.uwo.ca/etd/3032>

This Dissertation/Thesis is brought to you for free and open access by Scholarship@Western. It has been accepted for inclusion in Electronic Thesis and Dissertation Repository by an authorized administrator of Scholarship@Western. For more information, please contact wlsadmin@uwo.ca.

AN FMRI STUDY OF COMMAND FOLLOWING AND COMMUNICATION USING
OVERT AND COVERT MOTOR RESPONSES: IMPLICATIONS FOR DISORDERS
OF CONSCIOUSNESS

(Thesis format: Monograph)

by

Natalie Osborne

Graduate Program in Psychology

A thesis submitted in partial fulfillment
of the requirements for the degree of
Master of Science

The School of Graduate and Postdoctoral Studies
The University of Western Ontario
London, Ontario, Canada

© Natalie Osborne, 2015

Abstract

We used functional magnetic resonance imaging (fMRI) to explore neural mechanisms of command following or communicating using executed or imagined movements, in order to understand why most covertly aware patients cannot communicate. 15 healthy participants executed or imagined arm movements that were either selected by them or pre-determined. We also explored non-volitional motor activity by passively moving participants. Response selection involved greater activity in high-level associative areas in frontal and parietal regions than following commands. Furthermore, there was no interaction between response and modality. Neural activity during passive movement exceeded that of active (volitional) movement in sensorimotor regions. Our results suggest that the ability to select between motor responses is not dependent on how that response is expressed (via motor execution/imagery). They also suggest a potential neural basis of the distinction in cognitive abilities seen in DOCs. Finally, passive movement could be applied to study unresponsive patients' motor systems.

Keywords:

Functional Magnetic Resonance Imaging (fMRI); Disorders of Consciousness; Command Following; Communication; Motor Execution; Motor Imagery; Passive Movement

Acknowledgments

I would like to thank my advisor Dr. Adrian Owen for his expertise and guidance, as well as his mentorship and extreme generosity in providing me with incredible opportunities to network with other scientists and share my research abroad. I would especially like to thank my mentor Dr. Davinia Fernández-Espejo, with whom I collaborated on the design, analysis and interpretation of my project. Davinia patiently guided me through every step of my research, teaching me not only the practical skills required, but more importantly, how to think both critically and creatively. Working with Davinia and Adrian has been a perfect mix of inspiring and enjoyable, and I'm very grateful for their guidance.

I'd also like to express my sincere gratitude to the members of the BMI, in particular Dr. Jody Culham for her advice on designing my fMRI paradigms, Dr. Damian Cruse for his counsel on my project and Matlab Wizardry skills, and Haitao Yang for his inexhaustible source of patience and friendly technical support. I'd like to thank the Robarts team (Oksana Opalevych, Joe Gati and Trevor Szekeres) who cheerfully accommodated my increasingly complicated scanning set-ups. Special thanks also to Dawn Pavich for her constant support and knowing smile, Denise Soanes for her cheery hellos, and Devin and Lauren for lending me a hand. I'd like to acknowledge the financial support I received from Western and my Ontario Graduate Scholarships that allowed me to pursue my degree, and all my wonderful, amazing Owen and Grahn labmates that made my time here truly priceless.

Finally, I'd like to thank my friends and my Invoketress dance sisters for giving me balance, and my family for giving me everything else. I'm very grateful for my parents' unconditional support, encouragement, and constant entreaties to come home on the weekends. I'm thankful for my patient brother Alex, who helped me improve my work, and my precocious sister Alaina, who helped me forget it. I'd like to dedicate this thesis to my cousin Michael, who reminds me to smile everyday and appreciate the opportunity to do something I love.

Table of Contents

Abstract.....	ii
Acknowledgments	iii
List of Figures.....	vi
List of Tables	vii
Chapter 1: Introduction.....	1
1.0 Disorders of Consciousness.....	1
1.1 Consciousness: Arousal and Awareness	1
1.1.2 Coma.....	1
1.1.3 Vegetative State.....	2
1.1.4 Minimally Conscious State.....	3
1.1.5 Anatomical Features of DOC	3
1.2 Diagnosing DOCs.....	4
1.2.1 Behavioural Assessments	4
1.2.2 Command Following vs. Communication in Behavioural Assessments.....	8
1.2.3 Limitations of Behavioural Assessments	9
1.3 Assessing Covert Cognition in DOCs	10
1.3.1 Active Paradigms: Command Following	12
1.3.2 Command Following vs. Communication: Covert Assessments	17
1.4 Passive Paradigms	19
1.5 Motor Function in DOCs.....	20
1.5.1 Using Passive Movement to Investigate Sensorimotor Function.....	22
1.6 Study Objectives.....	23
Chapter 2: Experiment – Comparing Command Following and Communication in different response modalities.....	26
2.1 Materials and Methods	27
2.1.1 Participants	27
2.1.2 fMRI paradigm	27
2.1.3 Image acquisition.....	29
2.1.4 fMRI data analysis.....	29
2.3 Results	31
2.3.1 Factorial Analysis	31
2.3.2 One-way ANOVA	34
Chapter 3: General Discussion	38
3.0 Discussion.....	38

3.1 Validation of the Motor Task	38
3.2 Action Selection, compared to Command Following recruits a fronto-parietal network	38
3.3 Response Modality: Differences in Executed versus Imagined Movements	42
3.4 A lack of interaction between response and modality	43
3.5 Passive Movement elicits similar brain activity to executed movement.....	43
3.6 Implications for DOC Patients	47
3.7 Passive Movement: Applications for DOC Patients	49
3.8 Conclusion	51
References	51
Appendix I	61
Appendix II: Ethics.....	62
Curriculum Vitae	63

List of Figures

Figure 1: Representation of different DOCs, including coma, VS and MCS along the traits of wakefulness, awareness and mobility (ability to produce behaviour volitionally). Figure taken from (Monti et al. 2009).	5
Figure 2: Paradigm for fMRI experiment. Each block was 20 seconds long. During rest blocks (in orange), subjects lay still in the scanner.	28
Figure 3: The positive effect of Task compares brain activity elicited in conditions with motor execution to motor imagery. Results thresholded at FWE-corrected $p < 0.05$ for cluster level activation.	32
Figure 4: The positive effect of level of selection compares brain activity in action selection to command following conditions. Results thresholded at FWE-corrected $p < 0.05$ for cluster level activation.	33
Figure 5: This contrast compares brain activity during passive movement to conditions where participants initiated movement themselves (including action selection and command following). Results thresholded at FWE-corrected $p < 0.05$ for cluster level activation.	36
Figure 6: This contrast compares brain activity during passive movement compared to rest conditions. Results thresholded at FWE-corrected $p < 0.05$ for cluster level activation.	37

List of Tables

Table 1: Subscale diagnostic criteria for VS, MCS and EMCS from the CRS-R ^(Kalmar & Giacino 2007)	6
Table 2: fMRI studies with active paradigms.....	15
Table 3: EEG studies with active paradigms.....	16
Table 4: Activity Elicited by Motor Execution and Imagery	31
Table 5: Motor Imagery vs. Motor Execution.....	32
Table 6: Action Selection vs. Command Following.....	33
Table 7: Executed Movement: Passive vs. Active	35
Table 8: Passive vs. Active Movement	36
Table 9: Passive Movement vs. Rest.....	37

Chapter 1: Introduction

1.0 Disorders of Consciousness

1.1 Consciousness: Arousal and Awareness

Consciousness forms an integral part of the human experience, one that neuroscientists and philosophers alike strive to understand more thoroughly. In the field of clinical neurosciences, it is thought to be comprised of two factors: arousal and awareness (Steven Laureys et al. 2004). Arousal in this case refers to wakefulness, which is generated by the brainstem and reticular activating systems (McCormick & Bal 1997). Awareness refers to mindfulness of the self or the environment, and is believed to arise from regular functioning across and between brain systems (Steven Laureys et al. 2004). The exact brain regions responsible for creating our conscious experience are not yet known, although there are several theories involving thalamocortical (Schiff 2010; Schiff 2008; Fernández-Espejo et al. 2012; Monti et al. 2014) and fronto-parietal networks (Noirhomme et al. 2010; Jin & Chung 2012; Fernández-Espejo et al. 2012).

Disorders of Consciousness (DOC) are defined as impairment to one or both of these components, and consist of a spectrum of disorders including coma, the vegetative state (VS), and minimally conscious state (MCS). This impairment is often caused by severe brain injury, which may be traumatic (eg. motor vehicle accident) or non-traumatic (eg. stroke, cardiac arrest, infection) in nature (Multi-Society Task Force on PVS 1994).

1.1.2 Coma

A comatose state is clinically defined as a complete lack of arousal and responsiveness, in which patients are unable to be aroused by any external stimulation and lie with their eyes closed (Steven Laureys et al. 2004). To be diagnosed as comatose, a person must be in this state for at least one hour. After about two weeks to a month, comatose patients who survive their acute injury typically begin to recover consciousness. However, some

patients may recover wakefulness but remain in a disordered state of consciousness, such as VS or MCS (Steven Laureys et al. 2004). Positron Emission Tomography (PET) is a neuroimaging technique that measures brain activity as a function of the glucose metabolized in brain tissue. Measurements of cerebral metabolism of glucose in coma patients, which is believed to be an indicator of brain function, is typically reduced by 30 to 50 per cent of normal levels (Bergsneider et al. 2001).

1.1.3 Vegetative State

The VS is also known as unresponsive wakefulness syndrome (UWS) because patients have a circadian rhythm and sleep-wake cycles that lead to periods where they appear awake with their eyes open, but are thought to remain unaware of themselves or their environment (Steven Laureys et al. 2004). After one month in this condition, a patient is considered to be in a “persistent” VS. The VS is considered to be “permanent”, and therefore recovery of consciousness unlikely, after three months in patients with non-traumatic brain injuries, and one year in patients with traumatic injuries (Vanhaudenhuyse et al. 2012). While VS patients do not show volitional behaviour in response to external stimuli, they can show several automatic, unconscious reactions produced by the brainstem or limbic system, such as grimacing, crying, and laughing (Steven Laureys et al. 2004).

Resting-state PET scans of VS patients reveal global cortical metabolism that is roughly half that of healthy individuals (Rudolf et al. 1999). Metabolism is usually relatively normal in lower brain areas including the brainstem, reticular system, hypothalamus and basal forebrain (Laureys et al. 1999), which reflect VS patients’ intact autonomic activity (eg, breathing) and wakefulness. Importantly, metabolism is impaired in higher associative cortices (Laureys et al. 1999) that are thought to be required for more complex cognitive functions including attention, memory and language.

1.1.4 Minimally Conscious State

Patients in a MCS begin to show clear, reproducible evidence of consciousness. However, this increased level of environmental and self-awareness is not stable, and fluctuates over time (Vanhaudenhuyse et al. 2012). Some of the behaviours that characterize MCS are visual fixation and pursuit of objects, appropriate emotional responses (eg. laughing at a joke), behavioural responses to verbal commands and recovery of basic motor functions, such as manipulating objects (Vanhaudenhuyse et al. 2012). There is considerable variability in the degree of regained cognitive function among patients in the MCS state, and individuals may emerge from this state or remain MCS. Emergence from MCS (EMCS) occurs when a patient is able to communicate or use objects reliably and accurately (Vanhaudenhuyse et al. 2012). Interestingly, resting-state PET studies still show decreased cortical metabolism in MCS patients, with slightly greater metabolism than in the VS (S Laureys et al. 2004).

1.1.5 Anatomical Features of DOC

The different profiles of brain damage that can result in a disorder of consciousness can vary widely. Neuropathological and structural neuroimaging studies have revealed diverse patterns of brain damage in this population (Adams et al. 2000; Kampfl et al. 1998; Juengling et al. 2005; Fernández-Espejo et al. 2011; Fernández-Espejo et al. 2012) with damage profiles that seem to be unique to each patient. Subcortical damage can be found in varying degrees and occasionally in isolation, while cortical damage can range from severe to almost non-existent (Adams et al. 2000; Graham et al. 2005). The specific origin of injury typically results in characteristic damage patterns. For example, strong shearing forces experienced during physical trauma, such as a traffic collision, can sever connective fibres and are particularly destructive to the brain's white matter tracts. This is known as Diffuse Axonal Injury, or DAI (Smith et al. 2003). Most traumatic DOC patients show some degree of DAI and/or subcortical damage, specifically to the thalamus and its white matter (Adams et al. 1999; Jennett et al. 2001; Fernández-Espejo

et al. 2011; Fernández-Espejo et al. 2012; Fernández-Espejo et al. 2010). However, there are currently no well-established structural “biomarkers” that can distinguish between different DOCs (Fernández-Espejo et al. 2011). Therefore, the primary method for diagnosis is bedside behavioural assessment, typically performed multiple times by the patient’s clinical team.

1.2 Diagnosing DOCs

1.2.1 Behavioural Assessments

Measuring wakefulness in an individual is relatively straightforward, as people with restored sleep/wake cycles typically have periods where their eyes are open and they appear awake. Furthermore, electroencephalography (EEG) recordings can detect neural activity patterns that are characteristic of sleeping and waking states in DOC patients (De Biase et al. 2014). But how does one determine if someone (or something) is aware? The most straightforward method is to ask for a response that indicates the person is aware of themselves and their surroundings. Before the advent of neuroimaging techniques that allow researchers to measure an individual’s brain activity, these responses were by necessity behavioural. However, the absence of behavioural signs of awareness does not necessarily equal an absence of consciousness (Monti et al. 2009). Figure 1 (Monti et al. 2009) provides a visual representation of DOCs and their relationship to the arousal, awareness and behavioural components of consciousness.

Behavioural assessments rely on pre-determined and observable behaviours made by the patient in response to certain visual, auditory and tactile stimulation administered by the evaluator. The presence, or absence, of specific responses to these stimuli is used to make inferences about the patient’s level of conscious awareness and cortical processing (Schnakers 2012). These assessments include a variety of subscales designed to evaluate everything from low-level reflexive responses to volitional command following and communication. There are currently multiple behavioural assessments for consciousness that are used in hospitals and primary care facilities throughout the world, including the

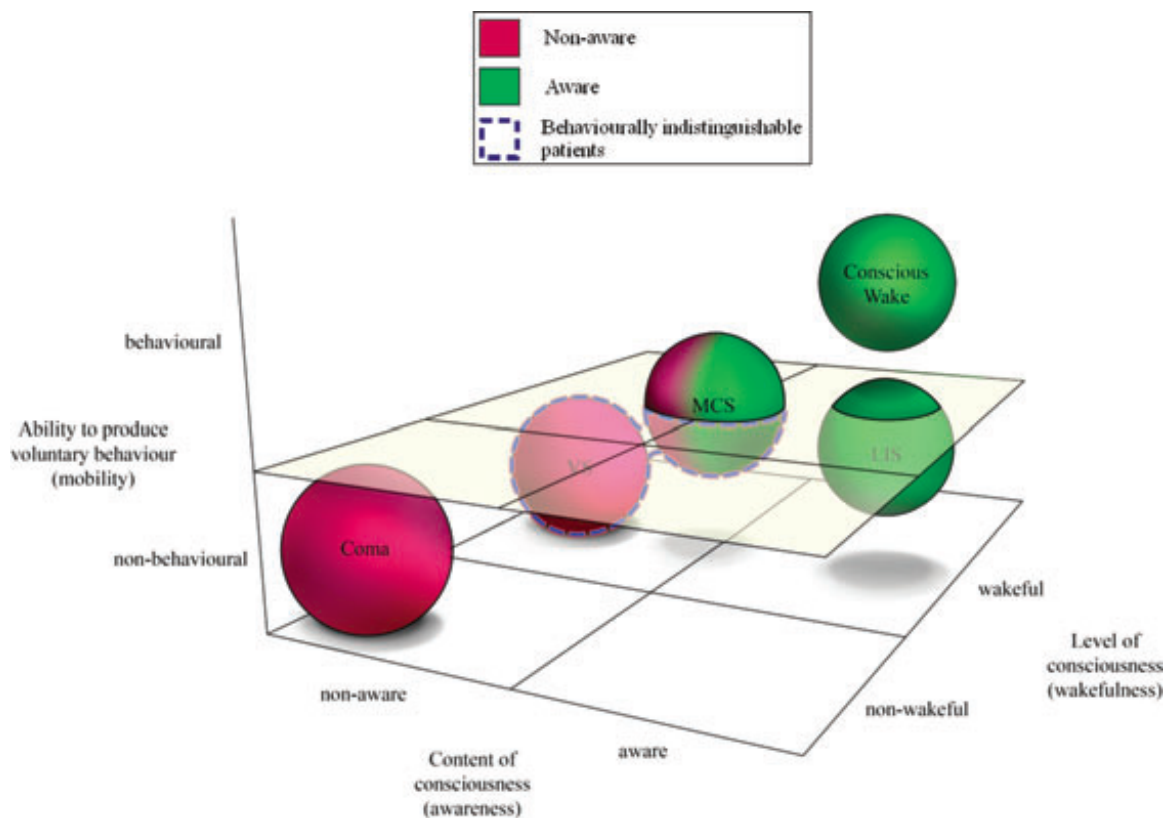


Figure 1: Representation of different DOCs, including coma, VS and MCS along the traits of wakefulness, awareness and mobility (ability to produce behaviour volitionally). Figure taken from (Monti et al. 2009).

Glasgow Coma Scale (Teasdale & Jennett 1974), the Full Outline of Unresponsiveness scale (Wijdicks et al. 2005), The Wessex Head Injury Matrix (Shiel et al. 2000), the Sensory Modality Assessment and Rehabilitation Technique (Gill-Thwaites & Munday 2004), and the JFK Coma Recovery Scale-Revised (CRS-R) (Schnakers 2012; Guldenmund et al. 2012), amongst others. Along with the Sensory Modality Assessment and Rehabilitation Technique (SMART), The JFK CRS-R is internationally recognized as the gold standard for differential diagnosis in DOC patients (Schnakers et al. 2009). The CRS-R is one of the more widely used diagnostic tests because it doesn't require any formal training by its creators, and is free to use. Its diagnostic criteria are summarized in Table 1.

Table 1: Subscale diagnostic criteria for VS, MCS and EMCS from the CRS-R^(Kalmar & Giacino 2007)

Diagnosis	Scale	
	Score	Behavioural Response
Auditory Function Scale		
MCS	4	Consistent Movement to Command
MCS	3	Reproducible Movement to Command
VS	2	Localization to Sound
VS	1	Auditory Startle
VS	0	None
Visual Function Scale		
MCS	5	Object Recognition
MCS	4	Object Localization: Reaching
MCS	3	Visual Pursuit
MCS	2	Fixation
VS	1	Visual Startle
VS	0	None
Motor Function Scale		
EMCS	6	Functional Object Use
MCS	5	Automatic Motor Responses
MCS	4	Object Manipulation
MCS	3	Localization to Noxious Stimulation
VS	2	Flexion Withdrawal
VS	1	Abnormal Posturing
VS	0	None/Flaccid
Oromotor/Verbal Function Scale		
MCS	3	Intelligible Verbalization
VS	2	Vocalization/Oral Movement
VS	1	Oral Reflexive Movement
VS	0	None
Communication Scale		
EMCS	2	Functional: Accurate
MCS	1	Non-Functional: Intentional
VS	0	None
Arousal Scale		
VS	3	Attention
VS	2	Eye Opening without Stimulation
VS	1	Eye Opening with Stimulation
VS	0	Unarousable

Adapted from (D. Cruse et al. 2012). Abbreviations: CRS-R = Coma Recovery Scale-Revised; EMCS = emergence from minimally conscious state; MCS = minimally conscious state; VS = vegetative state

The CRS-R is comprised of a series of subscales that assess function across auditory, visual, motor and oromotor or verbal categories. The scale also includes evaluation of a

patients' general state of arousal during the examination, and if certain criteria are met, an assessment of communication abilities (Kalmar & Giacino 2007). Patients are assigned a numeric score depending on their levels of responses in each category. This score ranges from 0 to 23, and corresponds to a diagnosis of VS, MCS or EMCS. In some cases, the presence of certain responses, such as replicable and accurate communication, can by definition denote a certain diagnosis (in this case, EMCS), regardless of the patient's performance in other categories (Kalmar & Giacino 2007). This is because some sensory modalities (eg. vision) may be impaired in a patient, leading to low scores in this category despite preservation of other cognitive resources.

The CRS-R provides multiple alternatives when assessing higher-level functions to account for the heterogeneous nature of DOC patients' physical abilities. Evaluators can ask specifically for eye, limb or mouth movements to command, depending on the patient's individual capabilities (Kalmar & Giacino 2007). It's important to note that responses in this assessment, regardless of the category, always require some type of motoric output by the patient. One of the subscales that specifically assesses command following is the Auditory Function Scale. This subscale is also one that compares more easily with neuroimaging studies of command following, which generally use auditory instructions for the patients (Fernández-Espejo & Owen 2013). In the Auditory Function Scale, patients are given various verbal commands, such as touching one of two objects presented to them ("touch the ball"), or making specific movements ("look up"). If they successfully follow these commands every time, and within 10 seconds of receiving the instruction, they're considered to show "Consistent Movement to Command" and receive the highest possible level in that subscale (4). Less consistent responding equates to "Reproducible Movement to Command" and a score of 3. However, both scores indicate command following, which is a marker of the MCS diagnosis. "Localization to Sound" is worth a score of 2, and assigned when a patient is capable of orienting (turning their head or eyes) towards an out-of-view auditory stimulus, such as a voice or a ringing bell. Finally, if a patient only responds to a sudden loud noise, for example by fluttering or blinking their eyes, they're considered to show an "Auditory Startle", worth a score of 1. These last two responses are considered to be relatively automatic or reflexive processes

rather than conscious, volitional action, and therefore correspond to a VS diagnosis (Kalmar & Giacino 2007). If a patient shows none of these responses, they're given a score of 0 for the Auditory Function Scale.

1.2.2 Command Following vs. Communication in Behavioural Assessments

If a patient demonstrates command following in any of the subscales, evaluators will administer the CRS-R's Communication Scale's six situational orientation questions. First, at least one clear behavioural response will be established with the patient for the purposes of communication. This behaviour, such as a head nod, will typically signify a "yes" response. Then evaluators will ask a series of six questions based on visual or auditory stimuli. For example, they may ask "Am I touching my ear right now?" while touching their ear, and again when they're not. Correct answers to all six questions constitute "Functional Communication", that is, providing reliable and clear responses that are factually accurate. Functional communication is considered an indisputable sign of consciousness, and consequently changes a patient's diagnosis to emerging from the minimally conscious state (EMCS) (Kalmar & Giacino 2007). The ability to communicate with a patient allows for more accurate assessment of their physical condition and well being, as well as opening up possibilities for various neurorehabilitation strategies (Whyte et al. 1999).

Interestingly, a patient may also receive the score of "Non-Functional: Intentional Communication" if they respond to at least two of the questions. Importantly, these responses may or may not be accurate. This score corresponds to a diagnosis of MCS, and is believed to reflect intention to communicate, or "communication readiness" which may be impaired by the fluctuating levels of consciousness characteristic of MCS patients (Bardin et al. 2011). Very few works have systematically studied the occurrence of behavioural command following or communication in MCS patients. A recent report including a cohort of 52 MCS patients identified command following in 33 per cent, and non-functional communication in 19 per cent of them. Importantly, only 17 per cent of

chronic patients (more than 1 year after the initial injury) showed command following abilities, and none were able to communicate (Estraneo et al. 2014).

Non-functional communication is an interesting link between the two cognitive tasks, command following and functional communication, that mark the diagnostic boundaries of the minimally conscious state. The ability to communicate accurate answers is thought to depend on preservation of a number of high-order cognitive processes, such as autobiographical memory, semantic representations, mental orientation, etc. However, when accuracy is not taking into account, as in non-functional communication, providing responses to binary questions essentially requires the ability to select between two alternative behaviours, representing ‘yes’ / ‘no’. Producing responses to command, and selecting between these responses to “answer” a question (albeit inaccurately) are both considered MCS behaviours. This diagnostic point might suggest that the one ability is not significantly different than the other, at least in regards to awareness. Interestingly, not all MCS patients who can follow commands can provide even inaccurate responses to binary questions. So while responding to commands and selecting between responses both fall in the MCS category, some patients can demonstrate the former but not the latter. The specific cognitive mechanisms underlying the differences between the ability to respond to a command, and the ability to select between two potential responses to answer a binary question, have not been explored.

1.2.3 Limitations of Behavioural Assessments

While behavioural assessments are the standard diagnostic tool used by clinicians, there are some challenges associated with their accuracy and reliability. Childs et al. found that 18 out of 49, or 37 per cent, of VS patients were misdiagnosed as VS, when they were actually MCS, with standard behavioural tests (Childs et al. 1993). A similar finding was reported in a 1996 study, where 43 per cent (17 out of 40) patients were misdiagnosed (Andrews et al. 1996). More recently, a study using the CRS-R as a diagnostic tool found a misdiagnosis rate of 41 per cent (18/44 patients) (Schnakers et al. 2009). This variability may in part be due to the subjective nature of certain criterion in behavioural

assessments, such as determining if a motor response (eg. eyeblink) is reflexive, spontaneous, or a volitional action made by the patient (Guldenmund et al. 2012). To further complicate matters, there are many clinical features associated with severe brain damage that can interfere with the behavioural responses recruited to investigate conscious awareness. These include motor system impairments, hearing or vision problems, spasticity, seizures, and pain; as well as the potentially confounding effects of any medication administered to treat these issues (Guldenmund et al. 2012). Fluctuations in attention and wakefulness during administration of the test may also misrepresent a patient's true level of consciousness by providing only a "snapshot" of their current state of arousal. Because no gold-standard measure of consciousness currently exists, it is difficult to definitively evaluate any given assessments' diagnostic reliability and validity (Guldenmund et al. 2012). This is a serious concern for this clinical population, as diagnosis can dictate a DOC patient's clinical care and legal rights, and confidence in diagnostic accuracy is especially important considering that patients considered to be VS could have life-sustaining treatments removed (Fins 2003).

1.3 Assessing Covert Cognition in DOCs

A small group of patients who are incapable of performing volitional movements to command can perform volitional motor imagery when instructed in neuroimaging paradigms. These paradigms commonly use functional magnetic resonance imaging (fMRI), which measures oxygenated blood flow in the brain, or EEG (Cruse et al. 2011; D. Cruse et al. 2012; Forgacs et al. 2014). This is a phenomenon known as "covert" cognition, which describes DOC patients who display no outward signs of consciousness, but show brain activity consistent with complex cognitive functioning indicative of awareness (Fernández-Espejo & Owen 2013)

Neuroimaging allows researchers to assess patients' neural responses to a variety of auditory, visual and tactile stimuli, and make inferences about what these responses may signify in terms of their residual cognitive abilities. Multiple studies using different neuroimaging techniques, including PET, EEG, and fMRI, have reported group level

brain activity in primary sensory cortices but not secondary or tertiary association regions in VS patients presented with auditory, visual or tactile stimuli (Laureys et al. 2002; S Laureys et al. 2004). Collectively, these findings lead researchers to conclude that any residual cognitive processing seen in VS patients does not reach the brain areas required to create conscious awareness or experiences of these stimuli (Steven Laureys et al. 2004). However, there have been reported cases where patients diagnosed as vegetative do have significant brain activation in higher associative areas in response to painful (de Tommaso et al. 2013), auditory, and visual stimuli which was revealed when patients were analyzed at the single subject level, rather than the group (Owen et al. 2002; Menon DK, Owen AM, Williams EJ, Minhas PS, Allen CMC, Boniface SJ, Pickard JD 1998; Fernández-Espejo et al. 2008; Monti et al. 2013). Neuroimaging results also show activation in higher associative areas and greater functional connectivity across different brain regions when MCS patients are presented with auditory (Boly et al. 2004) or somatosensory stimuli (Boly et al. 2005) compared to VS patients. Some MCS patients also react to emotional relevant stimuli, such as their own name or a story narrated by a familiar voice, with brain activity patterns similar to healthy controls (Perrin et al. 2006; Beckinschtein et al. 2004).

The diverse range of preserved cognitive capacity seen in DOC patients has led to the development of two general types of neuroimaging tasks: passive and active. Passive tasks present stimuli to patients without requiring any type of effortful response on their behalf. These tasks are useful for exploring sensory processing abilities in patients, and advantageous because they don't rely exclusively on the patients' ability to wilfully participate or understand task instructions. However, this also means that limited conclusions can be drawn regarding conscious cognitive processes with passive paradigms (Bruno et al. 2010). By contrast, active paradigms do require effortful and voluntary mental responses from patients. Therefore, successful performance in active paradigms can indicate awareness.

1.3.1 Active Paradigms: Command Following

In 2006, Owen and colleagues used fMRI to demonstrate preserved awareness in a patient diagnosed as being VS (Owen et al. 2006). The paradigm, which has become a gold standard for evaluating covert awareness in DOC patients, involved mental imagery of motor and spatial-navigation tasks. Importantly, in a healthy brain, these two tasks elicit activity in distinct regions (Boly et al. 2007). Therefore, researchers can discern between the tasks being performed in the scanner based on the pattern of brain activity produced. The motor task, in which participants are asked to imagine playing tennis, activates the supplementary motor area, a region involved in motor planning and imagery (Lotze & Halsband 2006). In contrast, the spatial navigation task, where participants are asked to imagine walking around the different rooms in their house, activates parahippocampal gyrus, posterior parietal-lobe and the lateral premotor cortex (Owen et al. 2006). The VS patient reported in Owen et al.'s landmark 2006 study was able to successfully perform both mental imagery tasks, demonstrating she was able to follow commands. That is, her brain activity changed reliably with the different imagery commands and resembled that of healthy controls performing the same tasks. Successful performance of mental imagery tasks like this one requires fairly complex cognitive functions typically associated with normal consciousness, including sustained attention, language comprehension (of the instructions), and working memory (to maintain the appropriate mental imagery during the task) (Cruse et al. 2011). This wilful modulating of one's brain activity in response to instruction represents covert command following, which is considered proof of awareness. Therefore, this finding was especially significant because the patient showed no observable behavioural evidence of command following or in fact any signs of awareness during standard behavioural assessments of consciousness. Nevertheless, her robust and accurate mental responses to commands in the fMRI paradigm suggested that she retained residual cognitive functions and possessed conscious awareness of herself and her surroundings (Owen et al. 2006).

Almost a decade later, a growing number of neuroimaging studies have used a variety of cognitive tasks to explore covert command following in DOC patients, including mental imagery, attention and verbal reasoning. To date, 61 patients have successfully followed commands by modulating their brain activity in both fMRI and EEG paradigms (cases of command following demonstrated in neuroimaging paradigms are summarized in Table 2 and 3. In some cases the same patient is reported in multiple paradigms). Several studies have employed auditory or visual attention to probe residual cognitive functioning in DOC patients (Naci & Owen 2013; Monti et al. 2014; Schnakers et al. 2008; Lulé et al. 2013; Pan et al. 2014). Attention tasks were proposed as a less demanding alternative to mental imagery, based on the observation that significant brain activity is not always elicited in mental imagery tasks even in healthy volunteers (Guger et al. 2003). In these tasks, participants are asked to focus their attention on specific stimuli, such as photos, words or numbers. Selective and sustained attention are considered conscious mental processes needed to perform basic cognitive tasks and form cohesive thoughts about ourselves and our surroundings (Naci & Owen 2013). Therefore, patients who showed brain activity in attention networks in response to commands are considered to be aware (Naci & Owen 2013; Monti et al. 2014; Schnakers et al. 2008; Lulé et al. 2013; Pan et al. 2014).

However, mental imagery is still the most commonly used cognitive task in neuroimaging paradigms that investigate covert consciousness (Monti et al. 2010; Hampshire et al. 2013; Forgacs et al. 2014). Since 2006, the tennis-house neuroimaging paradigm has been used in multiple studies to demonstrate covert command following in both VS and MCS patients (Fernández-Espejo & Owen 2013; Gibson et al. 2014). For example, a study by Monti et al. 2010 found that five out of 23 DOC patients, four of which were diagnosed as VS and one as MCS, accurately and reliably followed instructions to imagine playing tennis or walking around their house (Monti et al. 2010). Motor imagery in particular is frequently used in covert command following tasks, ranging from relatively complex, full-body motor imagery, such as swimming (Bardin et al. 2011; Goldfine et al. 2012), to smaller more specific actions, such as squeezing your hand (Bekinschtein et al. 2011). Cruse and colleagues were able to distinguish between

the sensorimotor patterns of two imagined actions (squeezing your right hand or wiggling the toes of both feet) in healthy participants, VS (Cruse et al. 2011; Damian Cruse et al. 2012) and MCS patients (D. Cruse et al. 2012) using EEG. Similar to previous neuroimaging studies, the three VS patients who successfully followed commands with motor imagery in this paradigm did not show even low-level behavioural signs of awareness, such as visual fixation or localization to painful stimuli, when assessed at the bedside (Cruse et al. 2011). Interestingly, 38 per cent of the MCS patients who successfully performed the motor imagery task also showed no motoric responses to commands in bedside tests (D. Cruse et al. 2012).

Coyle and colleagues recently used the hand and toe motor imagery task to train four MCS patients with an EEG-based Brain Computer Interface (BCI) (Coyle D, Stow J, McCreadie K, McElligott J, Carroll A 2014). All the patients exceeded the 70 per cent criterion for a dual-task BCI, indicating that they could successfully perform each motor imagery task to command. Coyle et al. also provided patients with visual or auditory real-time feedback during training sessions. This feedback was produced by analyzing their sensorimotor rhythms as they performed the mental imagery, and presented as a visual or auditory stimulus that could be influenced directly by the patient's changing brain activity. For example, a patient could guide a virtual basketball into a hoop by imagining squeezing their hand to move the ball left or wiggling their toe to move the ball right. The patient who had the most training sessions also had the best performance, with classification accuracies over 80 per cent. The researchers believe this performance enhancement is evidence of sensorimotor learning, which would likely only take place if the patient was consciously aware throughout the training sessions (Coyle D, Stow J, McCreadie K, McElligott J, Carroll A 2014).

Table 2: fMRI studies with active paradigms.

Study	DOC patients tested	fMRI Task	Number of patients who followed commands [✦]	Diagnosis & Aetiology
Owen et al. 2006	1	Mental Imagery (tennis & house)	1	1 VS: T
Monti et al. 2010*	54	Mental Imagery (tennis & house)	5	4 VS, 1 MCS: all T
Bardin et al. 2011	6	Motor Imagery (swimming)	2	1 MCS: NT, 1 (E)MCS: T
Bekinschtein et al. 2011	5	Attempted hand movement	2	2 VS: T
Fernández-Espejo & Owen 2013*	1	Mental Imagery (tennis & house)	1	1 VS: T
Naci et al. 2013*	3	Auditory Attention (counting target words)	3	2 MCS: 1 T, 1 NT, 1 VS: T
Hampshire et al. 2013	1	Mental Imagery & Verbal Reasoning	1	VS: T
Monti et al. 2013	1	Visual Attention (look at face/house)	1	1 MCS : T
Forgacs et al. 2014	26	Mental Imagery (swimming & deck of cards)	4	3 MCS: 2 T, 1 NT, 1 EMCS: T
Gibson et al. 2014	6	Mental Imagery (tennis & house)	3	2 VS: 1 T, 1 NT, 1 MCS : NT
Monti et al. 2014	28	Auditory Attention (counting target words)	10	3 VS: 1 T, 2 NT; 6 MCS: 3 T, 3 NT, 1 EMCS: NT
Total: 33				

Asterisk (*) indicate studies in which patients also functionally communicated, ✦ Locked-in State patients were not included in this table. Abbreviations: VS = Vegetative state, MCS = Minimally Conscious State, EMCS = Emerging from Minimally Conscious State, (E)MCS = fluctuating between MCS and EMCS diagnosis, T = brain injury of traumatic origin, NT = non-traumatic brain injury.

Table 3: EEG studies with active paradigms.

Study	DOC patients tested	EEG Task	Number of patients who followed commands [‡]	Diagnosis & Aetiology
Schnakers et al. 2008	22	Auditory Attention (counting target names)	9	9 MCS: 5 T, 4 NT
Cruse et al. 2011	16	Motor Imagery (squeeze hand, wiggle toes)	3	3 VS: 2 T, 1 NT
Goldfine et al. 2011	3	Motor Imagery (swimming) & spatial navigation (house)	1	1 (E)MCS: T
Cruse et al. 2012a	23	Motor Imagery (squeeze hand, wiggle toes)	5	5 MCS: T
Cruse et al. 2012b	1	Attempted movement (squeeze hand)	1	1 VTS:T
Lulé et al. 2013	18	Auditory Attention to target word	1	1 MCS: NR
Pan et al. 2014	6	Visual Attention to target photo	4	2 VS: 1 T, 1 NT, 2 MCS: 1 T, 1 NT
Gibson et al. 2014	6	Motor Imagery (squeeze hand, wiggle toes)	2	1 VS: T, 1 MCS: NT
Horki et al. 2014	6	Mental imagery (imagine playing sport, spatial navigation) & attempted foot movement	2	2 MCS, T
Coyle et al. 2015	4	Motor imagery (hand squeeze, wiggle toes)	4	4 MCS: 1 T, 2 NT, 1 NR
Total: 32				

‡ Locked-in State patients were not included in this table. Abbreviations: VS = Vegetative state, MCS = Minimally Conscious State, EMCS = Emerging from Minimally Conscious State, (E)MCS = fluctuating between MCS and EMCS diagnosis, T = brain injury of traumatic origin, NT = non-traumatic brain injury, NR = not reported.

1.3.2 Command Following vs. Communication: Covert Assessments

As described above, a small number of patients who are incapable of responding overtly are able to follow commands by willfully modulating their brain activity in mental imagery tasks (Fernández-Espejo & Owen, 2013). An even smaller proportion may be able to use these differential brain responses to communicate answers to binary yes/no questions, which has served as the theoretical basis for the development of brain-computer interfaces (BCIs) that could help patients express their thoughts externally to communicate with others. Of the 61 patients who have successfully demonstrated command following in neuroimaging tasks, to our knowledge only three have been able to functionally communicate using these mental responses. In all three cases this communication occurred despite the patients showing no externally observable communicative abilities over repeated behavioural testing.

The first DOC patient who used mental imagery to communicate was reported in Monti et al's 2010 study. This patient was a 22 year-old male who was in a VS after a traumatic brain injury. He had no behavioural signs of command following or communication, but his robust brain responses during the tennis/house task indicated that he was able to perform both tasks to command. Therefore, researchers asked him to perform one type of mental imagery to signify yes and the other to signify no, and asked him six binary (yes/no) autobiographical questions. He correctly answered five of these questions by performing the appropriate mental imagery task, while no response could be detected for the last question (Monti et al. 2010).

The second patient to communicate solely by modulating his brain activity did so using the same tennis/house fMRI task. He was a 38 year-old male who was consistently diagnosed as VS after a traumatic brain-injury in a motor vehicle accident 12 years previously (Fernández-Espejo & Owen 2013). When his ability to successfully follow commands with this mental imagery task was discovered, researchers asked him a series of questions about himself, his environment, and his care. Like the first patient, he did not always respond to questions, which may have been due to fluctuations in attention and

arousal during different scanning sessions. However, the authors were able to decode answers to twelve questions, including correct responses to questions about his name, the name of his personal support worker and the date (Fernández-Espejo & Owen 2013). This patient also demonstrated functional communication when tested with a separate fMRI paradigm, described below.

An fMRI study in our lab led by Naci (2013) posed a series of binary questions to healthy volunteers and asked them to answer by focussing their attention on the appropriate response word (“yes” or “no”) among a series of words presented through headphones (Naci et al. 2013). They were able to successfully decode 90 per cent of the subjects’ answers by measuring activity in brain regions associated with attention. These attention-specific regions of interest (ROI) were defined individually for each subject based on their brain activity during a previous selective attention task requiring them to count how many times they heard a target word in a series of unrelated words (Naci et al. 2013). When three DOC patients were tested with the same auditory attention tasks, all three were able to selectively attend to target words, and two successfully communicated answers to questions by modulating their attention (Naci & Owen 2013). One of these patients was the same 38 year-old male diagnosed as VS that was described previously (Fernandez-Espejo & Owen 2013). In this task he accurately responded to all four questions by selectively attending to the correct answer. The second patient was a 25 year-old male diagnosed as MCS after a traumatic brain injury. Appropriate brain activity in this patient’s predetermined attention-specific ROIs was seen for two out of four questions (Naci & Owen 2013). In the other two questions, the correct response could be decoded from activity in areas outside the ROIs that are also associated with attention. Interestingly, neither patient was able to display any behavioural signs of command following or communication in repeated bedside assessments conducted by the research team leading up to and at the time of the fMRI scan (Naci & Owen 2013; Fernández-Espejo & Owen 2013).

These three patients provide evidence that neuroimaging techniques can be used to establish functional communication with DOC patients who demonstrate covert cognition

but are incapable of communicating behaviourally. Researchers rarely report non-successful attempts to establish functional communication with DOC patients using neuroimaging techniques, therefore it is difficult to estimate the total number of patients who can use mental responses to follow commands, but not communicate. However, a reasonable inference is that the majority of patients who successfully follow commands in neuroimaging tasks are unable to communicate in these tasks (Fernández-Espejo & Owen 2013).

As with behavioural assessments for DOCs, the specific cognitive distinctions between command following and communication in covert tasks have not been explicitly studied. In their paper on brain-computer interface (BCI) use in DOC patients, Kübler and Kotchoubey speculated about the cognitive demands required for patients to communicate with, versus merely operate, a typical dual-task BCI (Kübler & Kotchoubey 2007). Operating a BCI requires patients to wilfully modulate their brain activity in response to different commands made by the experimenter (eg: imagine playing tennis, imagine walking around your house). In the case of these command following tasks, the requested response is dictated or “pre-set” by the experimenter (Kübler & Kotchoubey 2007). Whereas in communication tasks, a patient must allocate their attention to make a decision about the response they will make (yes/no) and choose the correct mental task (eg. imagine tennis) that signifies this response (Kübler & Kotchoubey 2007). This extra level of decision-making required in communication versus command following could be one factor that influences whether a patient can perform one or both tasks.

1.4 Passive Paradigms

While active paradigms have shown great success in demonstrating covert awareness in DOC patients, they are very cognitively demanding and therefore only effective in a small subset of them. Measuring brain responses to passive presentations of different stimuli can provide information on residual functioning in their corresponding neural systems. For example, designing tasks that present patients with noise, words and sentences and then analyzing the resulting brain activity may reveal a spectrum of

responses, from automatic, low level auditory processing to high level, semantic comprehension. Paradigms that passively present stimuli, such as sound clips with or without emotional content (eg. noise, words, stories, versus patient's name, baby cries), or images (eg. computer screen displays, faces) have successfully been used in DOC patients to study auditory, emotional and visual processing respectively (S Laureys et al. 2004; Perrin et al. 2006; Owen et al. 2002). Interestingly, to our knowledge a neuroimaging paradigm designed specifically to explore passive movement has not been formally studied in DOC patients. A recent fMRI study in our group reported a patient who displayed similar patterns of neural activity as healthy controls when they were exposed to the same audiovisual stimuli (Naci et al. 2014). This activity was elicited simply by showing the patient a movie clip, without giving any specific directions or asking for a mental response. Passive paradigms have also been used in coma patients, largely in an effort to find specific neural responses to external stimuli that have prognostic value (Vanhaudenhuyse et al. 2008). Neuroimaging studies have presented coma patients with tactile (Logi et al. 2003; Gofton et al. 2009) and auditory stimulation, including the patient's name (Fischer et al. 2008), and compared the resulting brain responses to patients' subsequent clinical progression. For example, absent or abnormal components of a brain response called a somatosensory evoked potential (SSEP), which occurs in response to tactile stimulation, typically indicates a poor clinical outcome (Cruse et al. 2014).

1.5 Motor Function in DOCs

The main disadvantage to diagnostic tests that rely exclusively on behavioural observations is the considerable variability that exists in DOC patients' motor function (Pistoia et al. 2013). In these assessments, motor responses such as eye, mouth and limb movements are the only means for patients to demonstrate conscious awareness. Impaired motor functioning in these patients can result in limited, unreliable, or non-existent voluntary motor behaviour, which can erroneously be interpreted as a lack of awareness (S Laureys et al. 2004). Despite the significance of motor responses in terms of clinical diagnostic tests, motor function has not been extensively studied in this population. The degree of cortical reorganization that occurs in motor-related brain areas after serious

traumatic or non-traumatic injury has not been thoroughly characterized (Lapitskaya et al. 2013a). A recent study involving 47 DOC patients (24 VS, 23 MCS) found abnormalities in certain neurophysiological markers of corticospinal pathway and motor cortex function compared to healthy controls (Lapitskaya et al. 2013b). Interestingly, some measures of motor system integrity, such as motor and sensory evoked potentials, did not differ from normal healthy volunteers, indicating that an inability to wilfully move may not always be associated with typical signs of an impaired motor system. However, the overall finding in the patients studied was one of decreased excitability in the corticospinal pathways necessary for generating movement (Lapitskaya et al. 2013b).

The possibility of using neurostimulation techniques to improve sensorimotor function in DOC patients, and thereby establish a reliable means to express residual awareness has been proposed (Angelakis et al. 2014; Pistoia et al. 2013). In 2013 Pistoia et al. created a paradigm designed to stimulate motor activity that combined visual demonstrations of a specific movement (opening and closing the hand) with transcranial magnetic stimulation (TMS) applied to the motor cortex in six VS patients. They reported improvements in motor responsiveness in four of these patients when they were asked to observe and imitate a researcher's hand movements, as measured by increases in their motor evoked potentials (MEPs) (Pistoia et al. 2013). Exactly how this improvement occurred is not understood, and may be partially attributed to a general recovery of consciousness (three of the four patients later regained higher motor and command following abilities) (Pistoia et al. 2013).

As described above (section 1.3.1), motor imagery has proven to be one possible alternative to overt movement in assessments of consciousness. The interesting dissociation that neuroimaging experiments have revealed between intact motor imagery and absent motor execution abilities in DOC patients could be explained by differences in their neural basis. Motor imagery involves an internal mental representation of an overt action without any concurrent executed movement (Jeannerod 1995). In contrast, motor execution involves physically performing the movement. Neuroimaging studies have shown that motor imagery and execution produce similar patterns of brain activity (Porro

et al. 1996; Lotze & Halsband 2006), leading some to consider motor imagery and motor preparation (the mental processes leading up to but not including actual movement) as essentially equivalent (Stephan et al. 1995; Jeannerod 1995). However, there is growing evidence for subtle but important differences in functional brain activation and connectivity between motor imagery and execution (James M. Kilner et al. 2004; Carrillo-de-la-Peña et al. 2008; Xu et al. 2014). While both tasks share a common network of sensorimotor areas, when compared directly, executing a movement typically recruits more cerebellum, primary motor and somatosensory cortices than imagining that movement, which involves more inferior parietal and frontal regions including pre-supplementary motor area (SMA) and superior and inferior frontal gyri (Gerardin et al. 2000; Szameitat et al. 2012; Machado et al. 2013; Burianová et al. 2013). Subtle but important differences in cortical damage to the neural mechanisms behind motor execution and imagery could explain why some DOC patients can perform one and not the other in response to commands.

1.5.1 Using Passive Movement to Investigate Sensorimotor Function

Whether a particular DOC patient's inability to execute movement to command arises from specific impairments in their motor system, or cognitive processes associated with volition, or a combination of both is not known. Passive movement, where an experimenter moves a participant while they remain relaxed, activates the same motor-related regions as executed movement, albeit to a lesser extent. Numerous neuroimaging studies in healthy volunteers have found similar patterns of brain activity between active and passive movement. Alary et al. (1998) found significant activation in brain areas associated with movement (cerebellum, premotor cortex, supplementary motor area, or SMA) and somatosensory regions (primary sensorimotor cortex, inferior parietal cortex) when subjects' wrists were passively extended (Alary et al. 1998). Two fMRI studies that directly compared passive vs. active elbow flexion reported weaker, yet significant brain activity when an MRI-compatible robot moved subject's arms (passive) compared to when subjects moved themselves (active) (Yu et al. 2011; Estévez et al. 2014). Activation in passive and active movement conditions involved similar brain structures,

including the primary motor (M1) and somatosensory cortex (S1), cingulate motor area (CMA), SMA, thalamus, basal ganglia and cerebellum.

To our knowledge, only one study has reported investigating neural responses to passive movement in a single DOC patient (Horki et al. 2014). These researchers were hoping to exploit the similarity in brain activity between active and passive movement in their development of motor imagery-based BCIs, with the goal of using brain activity elicited during passive movement as a classifier for subsequent motor imagery (Horki et al. 2014). However, brain activity produced in response to passive movement itself can provide valuable information about a patient. Both command following and response selection require decision-making, or volitional intention, by the patient, whether it be the decision to move to command, or selecting between two alternative actions to communicate. Passive movement is considered to be a different process than voluntary movement initiated by an individual (Haggard 2008) because it lacks a conscious intention to move. In philosophical terms, the conscious decision to act is the answer to the question, “what is left over if I subtract the fact that my arm goes up from the fact that I raise my arm?” (Haggard 2008). In cognitive neuroscience, decisions regarding volitional movement are thought to arise from various frontal and parietal brain areas. Brain responses to passive movement (movement in the absence of wilful intention) could help indicate why a patient may be incapable of volitional movement to command, by providing information on their sensorimotor function.

Overview of Thesis

1.6 Study Objectives

A clear distinction between command following and communication can be found in both behavioural and neuroimaging assessments of DOC patients: not all MCS patients who can follow commands can communicate. Importantly, the underlying neural basis behind these cognitive distinctions in DOC patients has never been explored. Furthermore, motoric action is the most common modality for patients to respond to commands or questions. Whether an action is executed in a bedside assessment, or imagined in a

neuroimaging paradigm, both responses require patients to make a volitional decision to act. However, an absence of motor responses (executed or imagined) to cognitive tasks may not indicate a lack of awareness, but rather impairments to a patient's motor system.

This study designed an fMRI paradigm for healthy participants, in order to answer three important questions raised when assessing residual cognitive function in DOC patients.

- 1) First, we wanted to determine if there is clear neural evidence for a cognitive difference between command following and communication, and characterize the brain structures that contribute to this distinction.
- 2) Second, we wanted to explore if this distinction depends on how the response is made, by studying the two most common response modalities used in DOC assessments, motor execution and motor imagery. We know that some DOC patients can respond to commands or questions in one modality but not the other. Therefore, we also wanted to investigate if an interaction exists between the cognitive resources involved in choosing to respond, and those involved in expressing the response (execution/imagery), or if these processes are distinct in the brain.
- 3) Third, we wanted to explore the existence of a hierarchy in volitional movement, from passive movement (with no wilful motoric output by the individual) to command following (volitional response), and finally action selection, which represents greater movement-decision making by the participant. This hierarchy could help explain the range in behavioural abilities seen in DOC patients. Furthermore, activation in sensorimotor regions, induced by somatosensory signals associated with passive movement, could indicate whether or not an unresponsive patient's sensorimotor pathways are functionally intact.

Involvement of higher-order cognitive processes in communication will vary according to the specific question being asked, and their individual contributions to accurate

communication can be difficult to disentangle. Our experiment employed a simpler cognitive aspect of communication that is inherent to many communication paradigms used in DOC patients. This is a binary response format, where one response is assigned to indicate a “yes” answer, and a different response is designated as a “no” answer. Regardless of the accuracy of their answer, this format requires the ability to select between two alternative behaviours. In our experiment, participants were allowed to select between two motor responses, and this “action selection” represented binary communication in its most basic form. This extra level of response selection is an important step in communicating an answer, compared to simply performing an action in response to command.

Therefore, our fMRI paradigm involved two distinct arm movements where healthy participants used both motor execution (behavioural) and motor imagery (mental) to express their responses. We measured brain activity elicited when healthy participants selected between two possible movement alternatives (‘action selection’) versus when participants’ movements were dictated to them (‘command following’). This allowed us to explore the effects of these different levels of selection and task expression, and whether or not an interaction exists between them. We also included a condition where the experimenters passively moved participants’ arms. This allowed us to characterize the neural response to passive movement and compare it to conditions where participants have increasing levels of volitional control over their movements, such as deciding whether to move (command following) and if so, which movement to perform (action selection).

Chapter 2: Experiment – Comparing Command Following and Communication in different response modalities

This experiment explored neural activity associated with action selection and command following using executed and imagined movements in healthy participants. Because there is a possibility this experiment may one day be adapted for use in DOC patients, our paradigm used a block design, with a block length of 20 seconds and a total task length of 8 minutes. Block designs, where brain activity is elicited during concentrated periods of time alternated with rest, allow for the collection of neural data with a reasonable level of statistical power in a relatively short period of time (Aguirre & D’Esposito 1999). They are especially advantageous for DOC patients, whose brain injuries and physical condition often limit the time they can spend comfortably in the MR scanner. The block length of 20 seconds was chosen based on previous pilot experiments in our lab that aimed to determine the ideal block length for optimizing brain activity associated with motor imagery tasks.

The fMRI paradigm used in this experiment was based in part off of a previous motor imagery/motor execution experiment in our lab (Fernández-Espejo et al, accepted). In that study, participants lay in the scanner with a tennis ball placed before them, and their right arm bent at the elbow with their forearm rested across their stomach. They were instructed to either imagine or perform a swinging movement with their right forearm when they heard a regularly timed cue, in an attempt to “hit” the ball. The current experiment used this right forearm movement because it was shown to reliably elicit the appropriate, expected brain activity both when executed and imagined (Fernández-Espejo et al, accepted). In addition, we also included another movement where participants raised and lowered their right forearm in a “lifting” motion. These two movements represented a binary response system, which is frequently used in behavioural assessments of communication in DOC patients (Kalmar & Giacino 2007). We modelled “action selection”, by asking participants to select a motor response from the two movement alternatives six times over the block, thereby creating a sequence of six movements. To demonstrate “command following”, participants were given a

predetermined sequence of six movements. Six movements were chosen because this was the maximum number that could be physically performed within a 20 second time frame, factoring in the time for audio instruction cues, pauses in between movements, and performance of the movements themselves (approximately two seconds each). This is also the same pacing of the cued movements used in Fernández-Espejo et al's experiment (Fernández-Espejo et al, accepted). Furthermore, the CRS-R communication scale involves six questions to which patients are asked to respond (Kalmar & Giacino 2007).

2.1 Materials and Methods

2.1.1 Participants

Fifteen right-handed healthy volunteers (ages 19 to 29, average 24 years; 8 females) with no history of neurological or psychiatric disease participated in the study. All volunteers gave written informed consent and were compensated for their participation in the experiment. The Health Sciences Research Ethics Board of the University of Western Ontario provided ethical approval for the study.

2.1.2 fMRI paradigm

Participants lay supine with their right arm bent at an approximately 90° angle, so that their forearm rested across their torso. Because movements of the shoulder and upper arm may induce artifacts in the participant's data (Rossit et al, 2013), a strap around the participant's chest was used to minimize upper arm and shoulder movements, while allowing for full rotation at the elbow.

Figure 2 describes the fMRI paradigm used in this experiment. While in the MRI scanner, participants were instructed to either execute or imagine a series of movements involving their right forearm. We used two different arm movements: a 'slide', which involved sliding the forearm forward and back; and a 'lift', which involved lifting and lowering the forearm. Each sequence involved six movements (combining 'slides' and 'lifts'). The beginning of each block was cued with the word 'move' or 'imagine'. Within each block

(imagery or execution), participants either received a pre-determined sequence or were asked to create one. For the blocks with pre-determined sequences, each individual action was cued with the word ‘slide’ or ‘lift’. For those where the subject had to create their own sequence, each action was cued with the word ‘go’. In another condition, participants were instructed to relax while a researcher moved their arm. This “passive” movement condition used the same pre-determined movement sequences as before, but without the accompanying auditory cues. Finally, we included a “rest” condition where participants were told to relax and lie still in the scanner. There were 4 blocks of each condition, each lasting 20 seconds and presented in a pseudorandom order for a total of 24 blocks over 8 minutes.

	Action Selection	Command Following	Passive
	Subjects choose which movement to perform (slide/lift) when they hear the word “go” to create their own sequence	Subjects are given different movement sequences by experimenters Eg. “slide lift lift slide lift slide”	Subjects lie still as they are passively moved by experimenters
Motor Imagery	Green	Red	n/a
Motor Execution	Dark blue	Light blue	Purple

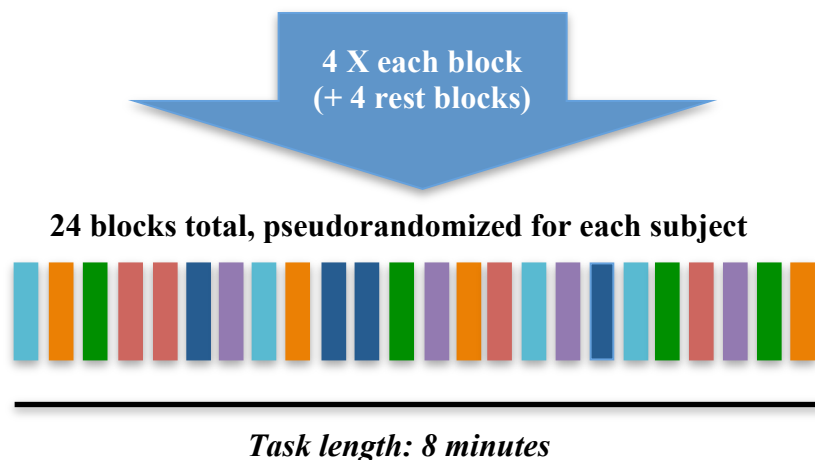


Figure 2: Paradigm for fMRI experiment. Each block was 20 seconds long. During rest blocks (in orange), subjects lay still in the scanner.

Each participant was randomly assigned four out of a possible 48 unique movement sequences, which were presented pseudo-randomly throughout the blocks. All participants completed 2 runs of this task. An infrared MR-compatible camera (MRC Systems GmbH), placed above the participant's head, was used to record participants' actions for each run.

2.1.3 Image acquisition

Data was acquired in a 3T Siemens scanner (Magnetom Prisma, Siemens, Germany) with a Siemens 32-channel head-coil at the Centre for Functional and Metabolic Mapping (CFMM) at Robarts Research Institute. Audio instructions and task cues were presented using Matlab® R2011a on a MacBook Pro laptop (OSX 10.6.8) and an MRI-compatible high-quality digital sound system via noise-attenuated headphones (Sensimetrics, S14).

The fMRI protocol included two sessions of 240 volumes each, using echo-planar images (36 axial slices, TR = 2000 ms, TE = 30 ms, matrix size = 70×70, slice thickness = 3 mm, in-plane resolution = 3×3 mm, flip angle = 78°). A high-resolution T1-weighted MPRAGE structural image (TR = 2300 ms, TE = 2.32 ms, IT = 900, matrix size = 256×256, voxel size 1×1×1 mm, flip angle = 8°) was also acquired.

2.1.4 fMRI data analysis

We performed Independent Component Analysis using the FSL MELODIC tool (<http://www.fmrib.ox.ac.uk/fsl>) in order to remove motion artifacts (Friston et al, 1996; McKeown et al, 1998; Beckmann & Smith, 2004). We visually inspected all the components and identified those that corresponded to head-motion artifacts and were correlated with the execution blocks (an average of 5±2.6 components per subject per run). Finally, we removed the identified components from the fMRI data. The de-noised data was then pre-processed and analyzed with SPM8 (<http://www.fil.ion.ucl.ac.uk/spm>). After manually AC-PC reorienting the data, the following spatial pre-processing steps took place: realignment, co-registration of the structural and functional data, spatial normalization to Montreal Neurological Institute (MNI) space, and smoothing with an 8-

mm FWHM Gaussian kernel. High-pass filtering with a cut-off period of 128 seconds was used to remove linear drift.

To address this study's first and second aim, a single subject fixed-effect 2-by-2 factorial analysis was performed for each subject at the whole-brain level. Factor 1 was defined as "Task" with two levels (motor imagery / motor execution) and Factor 2 was defined as "Level of selection", with two levels (action selection/command following). The design matrix modeled scans as belonging to the action selection/motor execution, command following/motor execution, action selection/motor imagery, or command following/motor imagery conditions using the canonical hemodynamic response function (Friston et al. 1995) the participant's rest condition used as a baseline. Realignment parameters and passive movement blocks were modeled as effects of non-interest. All 15 participants were included in the group analyses, which consisted of one-sample t-tests for each contrast of interest. The statistical threshold was set at a Family Wise Error (FWE) corrected $p < 0.05$ at the cluster-level. Two additional contrasts, individually comparing move and imagine conditions to rest, were also included to confirm that the task elicited a similar pattern of activation as previous motor tasks in our lab (Owen et al. 2006; Fernández-Espejo et al. 2014).

For the study's third aim, we performed a single subject, one-way ANOVA to compare passive movement to "active" movement conditions, where participants executed movements that were either determined by the experimenter (command following) or selected between two possible alternatives (action selection). Therefore, the single factor of "Executed Movement" had three levels: Action Selection, Command Following and Passive. The design matrix modeled scans as belonging to one of these three conditions, with the participant's rest condition as a baseline, once again using the canonical hemodynamic response function (Friston et al. 1995). Realignment parameters and all blocks involving imagined movement were modeled as effects of non-interest. We performed a one-sample t-test for each contrast of interest in all 15 participants for the group analyses. To further explore brain activity elicited by passive movement, we included three additional contrasts comparing passive movement to rest, passive to "all

active” movement (command following and action selection combined) and “all active” to passive movement. For all analyses, the FSL Harvard-Oxford Cortical and Subcortical Structural Atlases were used for anatomical identification (see Appendix I).

2. 3 Results

2.3.1 Factorial Analysis

Motor Execution and Motor Imagery vs. rest

Motor execution (move conditions) compared to rest significantly activated the right cerebellum and left sensorimotor area, including the primary motor (M1) and somatosensory (S1) cortices, located on the pre and post-central gyrus respectively. Motor imagery (imagine conditions) compared to rest elicited significant activity in several regions including the left supplementary motor area (SMA) and somatosensory association cortex as well as the left prefrontal cortex (frontal pole & middle frontal gyrus). Significant group activations are shown in Table 4.

Table 4: Activity Elicited by Motor Execution and Imagery

Motor Execution > rest						
<i>Brain structure</i>	<i>Coordinates</i>			<i>Cluster size (k)</i>	<i>T value</i>	<i>p value</i>
	<i>x</i>	<i>y</i>	<i>z</i>			
Cerebellum	24	-46	-26	172	12.3	0.033
Precentral/Postcentral gyrus	-30	-25	58	195	7.87	0.023
Motor Imagery > rest						
Middle temporal gyrus	-66	-40	1	359	12.03	0.001
Frontal pole	-36	47	-8	645	7.35	<0.001
Middle frontal gyrus	-36	5	61	153	6.78	0.029
Superior temporal gyrus	66	-16	1	260	6.54	0.004
Angular gyrus	-45	-55	55	295	6.49	0.002
Juxtapositional lobule cortex	-3	8	55	166	4.8	0.022

*Results thresholded at FWE-corrected $p < 0.05$ for cluster level activation

Motor Imagery vs. Motor Execution

The positive effect of *task* (i.e. motor execution versus motor imagery) revealed significant clusters of activation in the right cerebellum, as well as the left sensorimotor

area, as shown in Figure 3. The latter included M1, the primary somatosensory cortex (S1), and the superior parietal lobule.

The negative effect of *task* (i.e. motor imagery versus motor execution) revealed significant activity in the right S1 and M1, left inferior frontal gyrus and right occipital pole (representing the primary and secondary visual cortices). Group activations are shown in Table 5.

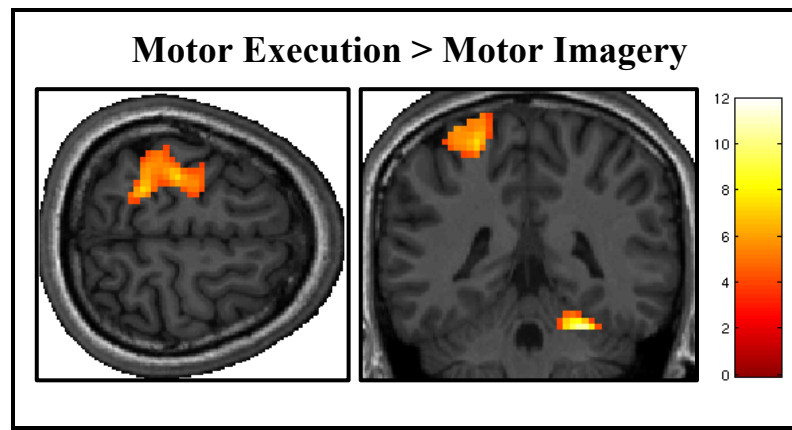


Figure 3: The positive effect of Task compares brain activity elicited in conditions with motor execution to motor imagery. Results thresholded at FWE-corrected $p < 0.05$ for cluster level activation.

Table 5: Motor Imagery vs. Motor Execution

Positive effect of Task (Motor Execution > Motor Imagery)						
<i>Brain structure</i>	<i>Coordinates</i>			<i>Cluster size (k)</i>	<i>T value</i>	<i>p value</i>
	<i>x</i>	<i>y</i>	<i>z</i>			
Cerebellum	24	-46	-26	197	11.91	0.03
Superior parietal lobule/postcentral gyrus	-24	-43	61	409	7.33	0.002
Negative effect of Task (Motor Imagery > Motor Execution)						
Postcentral/ Precentral gyrus	39	-25	61	2332	10.22	<0.001
Inferior frontal gyrus	-57	20	22	6391	9.28	<0.001
Occipital pole	12	-88	28	852	7.0	<0.001

*Results thresholded at FWE-corrected $p < 0.05$ for cluster level activation

Action selection vs. command following

The positive effect of *level of selection* (i.e. conditions where the participant had to choose between two actions versus those in which the action was determined by the

experimenter) revealed significant activity in frontal regions including the left middle frontal gyrus, and the right paracingulate gyrus (including pre-SMA) as illustrated in **Figure 4**. There was also significant activation in the somatosensory association cortex, specifically the right angular gyrus and left supramarginal gyrus, as well as the left insula. The inverse contrast (command following versus action selection) showed bilateral activation in the lateral occipital cortex (extrastriate visual area) and primary auditory cortices. Group activations are shown in Table 6.

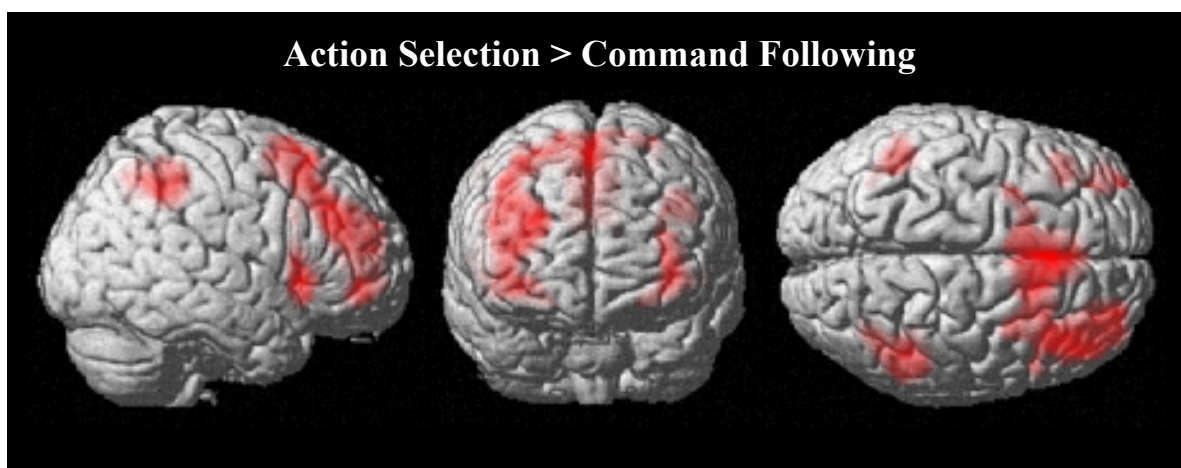


Figure 4: The positive effect of level of selection compares brain activity in action selection to command following conditions. Results thresholded at FWE-corrected $p < 0.05$ for cluster level activation.

Table 6: Action Selection vs. Command Following

Positive effect of Level of Selection (<i>action selection > command following</i>)						
<i>Brain structure</i>	<i>Coordinates</i>			<i>Cluster size (k)</i>	<i>T value</i>	<i>p value</i>
	<i>x</i>	<i>y</i>	<i>z</i>			
Paracingulate gyrus	3	20	46	2826	9.67	<0.001
Middle frontal gyrus	-36	29	31	441	8.83	<0.001
Angular gyrus	45	-49	40	439	7.16	<0.001
Supramarginal gyrus	-48	-46	40	189	6.54	0.009
Insular cortex	-33	17	1	193	5.89	0.008
Negative effect of Level of Selection (<i>command following > action selection</i>)						
Lateral occipital cortex	51	-67	7	952	11.91	<0.001
Lateral occipital cortex	-48	-73	10	251	9.59	0.003
Superior temporal gyrus	-63	-19	1	666	7.98	<0.001
Heschl's gyrus	48	-13	1	600	6.72	<0.001

*Results thresholded at FWE-corrected $p < 0.05$ for cluster level activation

Interactions

There were no significant interactions between Task and Level of Selection. No significant effects were found even when we lowered the statistical threshold to an uncorrected $p < 0.01$. We explored whether a positive interaction existed between level of selection and task; that is, if the process of action selection elicited greater brain activity than command following when the action was executed versus imagined. No significant effects were found for the positive interaction at an acceptable statistical threshold, nor when thresholds were lowered to uncorrected $p < 0.01$. We also included the inverse, negative interaction and similarly, no significant activity was found at corrected $p < 0.01$ at the cluster-level.

2.3.2 One-way ANOVA

There was a significant main effect of executed movement (comprising action selection, command following and passive movement) with one very large cluster of activation spread across several regions of the brain, including SMA, M1, S1, inferior parietal lobule, frontal poles, and middle and superior frontal gyri, with the cluster peak located in the right frontal lobe ($x=12, y=32, z=7$). The post hoc pairwise contrasts are discussed below.

Executed movement: Action selection vs. command following

Motor execution conditions where the participant chose between two actions versus those in which the action was determined by the experimenter revealed a large cluster of activity in the right paracingulate gyrus (including pre-SMA) that extended into the left hemisphere. Activity was also seen in the right angular and supramarginal gyri. This pattern of activity is similar to that observed when action selection was compared to command following across motor execution and motor imagery conditions in the Factorial Analysis. Group activations are shown in

Table 7.

Table 7: Executed Movement: Passive vs. Active

Action Selection > Command Following						
<i>Brain structure</i>	<i>Coordinates</i>			<i>Cluster size (k)</i>	<i>T value</i>	<i>p value</i>
	<i>x</i>	<i>y</i>	<i>z</i>			
Paracingulate gyrus	6	23	43	1427	9.87	<0.001
Inferior parietal lobule (angular gyrus/supramarginal gyrus)	48	-46	55	247	6.20	0.004
Command Following > Passive Movement						
Superior temporal gyrus	63	-19	1	178	6.32	0.038
Passive Movement > Command Following						
Precentral gyrus/Superior frontal gyrus	-12	-16	64	6750	10.60	<0.001

*Results thresholded at FWE-corrected $p < 0.05$ for cluster level activation

Executed movement: command following vs. passive

Motor execution conditions where the participant performed actions dictated by the experimenter versus those in which the participant was passively moved by the experimenter elicited significant activity in the right primary auditory cortex, with a cluster in the left primary auditory cortex approaching significance ($p = 0.065$). Group activations are shown in

Table 7.

An additional contrast exploring activity that was greater during passive movement compared to motor execution conditions where participants followed commands revealed a large cluster of activity over the left M1 and extending to include left S1, the superior parietal lobule and the SMA. (See

Table 7).

Passive vs. Active Movement

We compared passive movement to all “active” executed movement (collapsed across command following and action selection conditions). Significant activity was seen in left sensorimotor areas including S1, M1 and the somatosensory association cortex. Another

significant cluster of activity was seen in the left inferior frontal gyrus. A similar cluster with almost identical coordinates that approached significance at F.W.E. ($p = 0.051$) was seen in the right inferior frontal gyrus. The inverse contrast (executed movement versus passive movement) revealed no significant activity. See **Figure 5** for group activity and Table 8 for group activations.

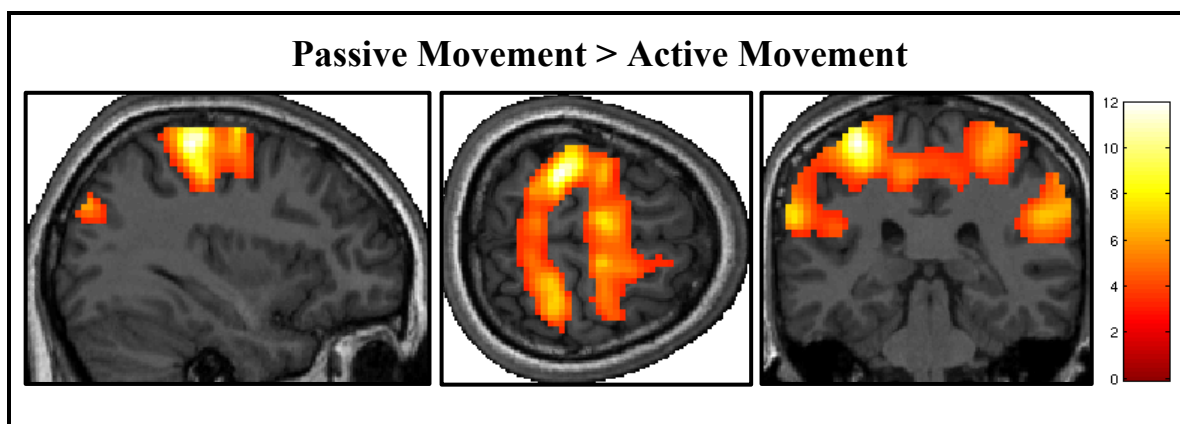


Figure 5: This contrast compares brain activity during passive movement to conditions where participants initiated movement themselves (including action selection and command following). Results thresholded at FWE-corrected $p < 0.05$ for cluster level activation.

Table 8: Passive vs. Active Movement

Passive > Active Movement (Action Selection + Command Following)						
<i>Brain structure</i>	<i>Coordinates</i>			<i>Cluster size (k)</i>	<i>T value</i>	<i>p value</i>
	<i>x</i>	<i>y</i>	<i>z</i>			
Postcentral/Precentral gyrus, Superior parietal lobule	-33	-34	61	7063	14.16	<0.001
Inferior frontal gyrus	-54	8	13	172	5.73	0.046

*Results thresholded at FWE-corrected $p < 0.05$ for cluster level activation

Passive vs. rest

The passive movement condition produced robust activity in several brain regions when compared to rest, such as M1 and S1, as well as parietal regions including the somatosensory association cortex and secondary somatosensory cortex (S2) as shown in **Figure 6**. Significant activity was also found in frontal areas including the right inferior frontal gyrus and left central opercular cortex, as well as bilateral extrastriate visual

cortex (lateral occipital cortex) and auditory association area (middle temporal gyrus). A complete list of significant activations is shown in Table 9.

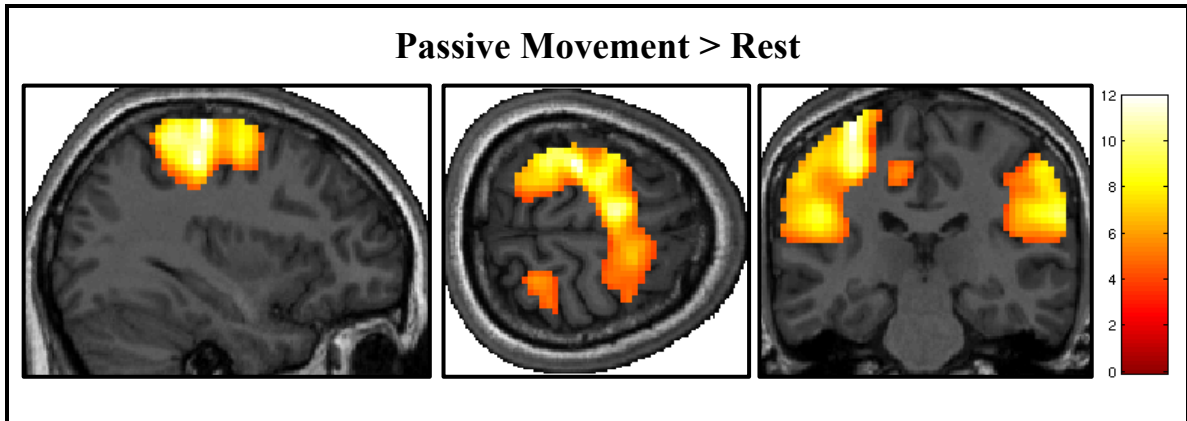


Figure 6: This contrast compares brain activity during passive movement compared to rest conditions. Results thresholded at FWE-corrected $p < 0.05$ for cluster level activation.

Table 9: Passive Movement vs. Rest

Passive > rest						
<i>Brain structure</i>	<i>Coordinates</i>			<i>Cluster size (k)</i>	<i>T value</i>	<i>p value</i>
	<i>x</i>	<i>y</i>	<i>z</i>			
Postcentral/Precentral gyrus	-33	-28	64	3123	11.65	<0.001
Supramarginal gyrus	66	-25	25	1287	9.79	<0.001
Inferior frontal gyrus	57	17	16	369	9.73	0.003
Lateral occipital cortex/Middle temporal gyrus	-54	-64	4	203	9.68	0.027
Central opercular cortex	-48	2	7	219	7.92	0.021

*Results thresholded at FWE-corrected $p < 0.05$ for cluster level activation

Chapter 3: General Discussion

3.0 Discussion

Here, we provide the first report of the differences in brain activity elicited by command following and the level of response selection necessary for binary communication, in tasks involving either external behavioural responses (i.e. motor execution) or covert neural responses (i.e. motor imagery). Our results provide evidence to support that, while motor imagery and execution may be dissociable processes, the mechanisms underlying the ability to select between two actions are not dependent on how the motor response is expressed (i.e. executed or imagined). Furthermore, we found that passive and active movement share very similar patterns of neural activity, particularly in sensorimotor regions, but seem to recruit different frontal brain areas.

3.1 Validation of the Motor Task

The motor imagery and execution tasks produced similar activation patterns as previous neuroimaging experiments (Michelon et al. 2006; Mokienko et al. 2013; Gerardin et al. 2000). Specifically, motor imagery compared to rest elicited activity in frontal regions, including the SMA, similar to the well-established “tennis” motor imagery paradigm used in our lab (Fernández-Espejo et al. 2014; Boly et al. 2007). Motor execution compared to rest activated contralateral M1 and ipsilateral cerebellum, an activation pattern typically reported in neuroimaging studies of executed movement (Machado et al. 2013; Formaggio et al. 2013).

3.2 Action Selection, compared to Command Following recruits a fronto-parietal network

Both behavioural and neuroimaging studies agree in suggesting that most VS or MCS patients who are overtly or covertly able to follow commands do not show communication abilities (Estraneo et al. 2014; Monti et al. 2010; Naci & Owen 2013; Owen 2011), but the neural correlates behind this divergence are not well understood. We found significantly higher activity in frontal regions, including the pre-SMA, and middle frontal gyrus when participants had to select between two possible actions (pre-requisite for binary communication) compared to when the examiner dictated their actions to them (command following). The middle frontal gyrus (Wiese et al. 2004) and pre-SMA (Mostofsky & Simmonds 2008; Haggard 2008) are thought to be involved with higher order executive functions related to voluntary motor control. The peak in the cluster of activation in the left middle frontal gyrus was located in the dorsolateral prefrontal cortex (DLPFC). Activity in this region was reported in several PET studies (Jahanshahi et al. 1995; Jenkins et al. 2000; Weeks et al. 2001) comparing externally-triggered movements (eg. cued by an auditory or visual stimulus) and self-initiated movements (eg. self-paced by the participant). In Weeks et al.'s study, participants also chose between two possible finger movements to perform. DLPFC involvement is thought to reflect the increased demand on working memory in the self-initiated condition, where participants must keep track of their own movements' timing rather than simply responding to cues (Weeks et al. 2001). In our experiment, participants determined the type, rather than the timing, of their movements in the action selection condition. They were instructed that the six-movement sequences they created during these blocks should be novel, and should not include more than three repetitions of the same movement (eg. slide). Therefore, it is not surprising that action selection elicited greater activity in the DLPFC, as participants likely held their selected movements in working memory to create their sequences.

Activity in pre-SMA has previously been observed in motor experiments where participants were asked to control certain aspects of the movements they performed, such as direction, timing, or type (Jahanshahi et al. 1995; Deiber et al. 1999; Jenkins et al.

2000; Jankelowitz & Colebatch 2002; Gowen & Miall 2007). In a 2008 review, Haggard proposed that voluntary action is a form of decision-making (Haggard 2008) that involves two decisions: whether to act, and what to do. The latter is further broken down into choosing between a goal (or task), and selecting between possible movements to achieve it. Regions within the pre-SMA are activated when participants choose between different tasks (eg. following a specific, cued movement plan or making their own movement plan) as well as quickly switching between these two tasks (Nachev et al. 2005). The pre-SMA is thought to help form and initiate action intentions (eg. which task to do) by forwarding inputs from the basal ganglia and prefrontal cortex to the SMA and M1 (Nachev et al. 2007; Haggard 2008). Activity in the pre-SMA increases when participants are asked to specifically pay attention to their intention to move during tasks with self-paced movements (Lau et al. 2004). Prefrontal areas including the pre-SMA are also thought to influence action selection by preferentially enhancing a particular desired action among several alternatives represented in the parietal cortex (Cisek & Kalaska 2010). Importantly, all of the above studies involved decision-making with executed movements, although Haggard suggests that the same process of voluntary action preparation occurs for actions that are prepared but not executed. In his 2007 fMRI study, participants chose when to make simple key presses and in some cases, when to prepare to key-press but not perform the action at the last moment (Brass & Haggard 2007). While cancelling a planned movement and motor imagery are not identical mental processes, our results indicate that the pre-SMA is also recruited when decisions about imagined movements are made, as in the condition where participants selected between imagining two action alternatives.

Additionally, in our study action selection elicited activity in the left insula. The insula has been associated with self-awareness, specifically in relation to the body and its movements (Tsakiris et al. 2007). In particular, several neuroimaging studies have implicated the insula in the sense of agency or personal authorship of voluntary movements, although the specific location of activity varies from right posterior (Farrer et al. 2003) to bilateral anterior (Farrer & Frith 2002). Finally, action selection compared to command following also revealed significant activation in the somatosensory

association cortex, specifically the left supramarginal and right angular gyri. This is in agreement with a 2004 fMRI study by Wiese and colleagues, who found increased activation in the left inferior parietal lobe when subjects self-initiated finger movements, compared to when these movements were performed in response to visual cues.

The right angular gyrus has also been associated with awareness of action authorship, specifically, in matching our movement intentions to their outcomes to determine whether a movement is under our control or another's (Farrer et al. 2008). In Farrer's studies, increased right angular gyrus activity corresponded to an increased mismatch between action intention and outcome, which contributed to the sense that the participant did not perform the actions. In contrast, our results show increased activity in this region in the condition where participants had greater control over their movements (action selection). Important methodological differences could account for this discrepancy in findings; Farrer's experiments involved manipulating the perceived outcomes of participants' actions (through modifying visual feedback displays of the consequences of their movements) as well as directly asking participants to evaluate their sense of action authorship. In our experiment, participants kept their eyes closed in the scanner and received no feedback, auditory or visual, regarding their movements other than their own proprioception. Furthermore, they were not asked about their personal experience of agency throughout the different movement conditions, as that was not the focus of our study.

More generally, the activity seen in the inferior parietal lobule may reflect a complimentary motor-decision pathway to the more frontal-system described above. Some action related decisions, such as choosing between movement alternatives, are thought to use a parietal brain circuit that involves sensory feedback relayed from primary sensory areas to the parietal cortex, and then to premotor areas and M1 (Haggard 2008). Cisek & Kalaska proposed that this "dorsal" system originally evolved to allow organisms to react to their environment (eg. reaching for a moving object), and has since been adapted to participate in more complex decision-making, beyond those involving visually guided movements (Cisek & Kalaska 2010). Both the frontal and parietal areas

activated when participants choose their own actions, compared to when their actions were dictated to them, correspond to neuroanatomical models of decision-making (Gleichgerrcht et al. 2010).

Overall, the above results suggest that selection between two possible actions requires a greater involvement of high-level associative areas in frontal and parietal cortices than required for following simple commands.

3.3 Response Modality: Differences in Executed versus Imagined Movements

Motor imagery involves creating an internal mental representation of an overt action without any concurrent executed movement (Jeannerod 1995). In contrast, motor execution involves physically performing a movement. Classic neuroimaging studies revealed similar patterns of brain activity for both motor imagery and execution (Porro et al. 1996; Lotze & Halsband 2006). This led some authors to conclude they may be equivalent processes (Jeannerod 1995; Stephan et al. 1995). However, more recent works have revealed important differences in functional brain activation and connectivity between the two (James M. Kilner et al. 2004; Carrillo-de-la-Peña et al. 2008; Xu et al. 2014; Burianová et al. 2013; Machado et al. 2013). Consistent with these reports, we identified higher activation in left sensorimotor areas, including M1, S1 and the superior parietal lobule, as well as the right cerebellum for motor execution, as compared to motor imagery. In contrast, motor imagery was associated with higher activity in the right M1, S1, and left inferior frontal gyrus. The higher ipsilateral M1/S1 activity in this contrast may be reflecting inhibition during motor execution. Indeed, concurrent left M1 activation and right M1 deactivation has been previously reported in both EEG and fMRI studies involving right hand movement (Burke et al. 2004; Hayashi et al. 2008; Grefkes et al. 2008; Machado et al. 2013). The reported activity in the left inferior frontal gyrus has previously been seen in motor imagery studies (Gerardin et al. 2000; Szameitat et al. 2012), and further suggests an inhibitory process during motor imagery. The inferior frontal gyrus, specifically the right side, is associated with response inhibition in go/no-go and stop-signal tasks that require rapid inhibition of motor responses (Aron et al.

2004). Recently, some controversy regarding the exact role of the right IFG in this inhibitory mechanism has arisen (Hampshire 2015), with some researchers believing it helps orient attention to stop signals (Solbakk et al. 2014; Sharp et al. 2010), or keep track of arbitrary task rules dictating when to inhibit responses (Mostofsky & Simmonds 2008). Overall, studies increasingly suggest that the IFG works together with other frontal areas, including the pre-SMA (Sharp et al. 2010; Mostofsky & Simmonds 2008) and the dorsolateral prefrontal cortex (Mostofsky et al. 2003) to inhibit responses.

3.4 A lack of interaction between response and modality

One aim of our study was to investigate whether the differences between command following and action selection for communication are dependent on the modality in which the participant expresses their response (i.e. imagining or execution). Here, we failed to identify an interaction between modality (i.e. motor imagery and execution) and level of selection, even at very low statistical thresholds. A specific contrast exploring the possibility of a positive interaction, whether action selection elicited greater brain activity than command following in motor execution versus motor imagery conditions, also revealed no significant activity, even at uncorrected $p < 0.01$. Overall, our results do not provide evidence for an interaction between the cognitive resources required to make a response and the specific method (motor execution or imagery) employed. This may suggest that these two factors are dissociable, that is, the neural processes involved in following a command or selecting an action are not dependent on the modality in which the action is expressed. Therefore, it could theoretically be possible to express preserved cognitive abilities with one modality and not the other. This finding has special significance for DOC patients who cannot exhibit behavioural signs of awareness, but are capable of demonstrating covert awareness by modulating their brain activity.

3.5 Passive Movement elicits similar brain activity to executed movement

Another aim of this study was to characterize brain activity in response to passive movement, and compare it to volitionally executed movement to explore the existence of

a movement-decision hierarchy. Passive movement compared to rest elicited activity in left S1 and M1, as well as the right somatosensory association cortex, including S2 and the supramarginal gyrus. Activation in these areas is commonly seen in neuroimaging studies involving passive arm (Yu et al, 2011; Estevez et al, 2014), foot (Francis et al, 2009; Ciccarelli et al, 2006), and finger movements (Alary et al, 1998; Van de Winckel et al 2013). Activity was also seen in the left inferior frontal gyrus and the right central opercular cortex. Involvement of the inferior frontal gyrus may reflect the same inhibition of movement described previously for motor imagery conditions (see Section 3.3 above). Similar to motor imagery, participants were instructed not to move during passive conditions, but to keep their limbs completely relaxed as researchers moved them. The activity seen in the opercular cortex may reflect the somatosensory stimulation associated with the strap used to move participants' arms. Opercular cortex specifically has been activated following electrical stimulation of the median nerve, a technique used to elicit somatosensation in participants (Korvenoja et al, 1999). Interestingly, the passive condition compared to rest showed no activity in the pre-SMA, one of the brain areas involved with increased decision-making and autonomy during voluntary movement and motor planning (Lau et al. 2004; Haggard 2008; Gowen & Miall 2007; Jenkins et al. 2000; Nachev et al. 2005). This is not surprising, as participants did not have to choose to perform an action in response to command, or select among alternative actions to perform. In fact, participants had no control over their arm movements in this condition, and made no decision other than the choice to comply with researchers and remain relaxed during passive movement. However, the difference in pre-SMA activity between passive and active movement did not survive the statistical threshold when the two conditions were compared directly.

To further investigate brain activity in executed movement requiring varying degrees of decision making by the participant, we performed a One-Way ANOVA with three levels: action selection, command following, and passive movement. The contrast comparing conditions where participants selected and performed their own actions compared to command following conditions revealed brain activity similar to what was found previously in the factorial analysis described above. The contrast comparing command

following movements to passive movements revealed significant activity only in the primary auditory cortex. This is likely because participants heard auditory instructions (eg. “lift”, “slide”) in command following blocks, compared to silence during passive movement. Similarly, when we directly compared conditions where participants actively moved themselves (command following combined with action selection) to passive movement, no significant activity in any brain area was found.

Surprisingly, the inverse contrast (passive movement compared to active movement) revealed several regions of activity. Significant activation of the left inferior frontal gyrus, with a corresponding cluster in the right inferior frontal gyrus narrowly missing the significance cut-off at FWE corrected $p = 0.051$, could represent motor inhibition that is not required during conditions with actively executed movements (Jaeger et al. 2014). A large cluster of activity in contralateral S1 and somatosensory association cortex, as well as M1, was also seen. Similar activation in sensorimotor regions was seen when passive movement was compared to movement execution from the command following condition only.

The finding that passive movement elicited greater sensorimotor activity than active movement was unexpected. Neuroimaging studies comparing active movements performed by a participant to passive movements made by experimenters typically find stronger activation in sensorimotor areas during active movement (Yu et al, 2011; Estevez et al, 2014; Ciccarelli et al 2006; Van de Winckel et al 2013). Greater activation in the motor cortex is assumed to reflect its increased involvement when the participant plans and executes a movement themselves. Similarly, we might also expect to see more activity in frontal areas associated with movement decisions, such as the pre-SMA, when a participant actively performs a movement compared to passive conditions. In this experiment, pre-SMA involvement seems to be restricted to action selection conditions involving the highest level of decision-making, and therefore activity in this region is not observed when comparing combined forms of active movement, or solely command following, to passive movement. Alternately, a recent neuroimaging study comparing active and robot-assisted passive leg movements found greater activity in somatosensory

association areas (inferior parietal cortex) and premotor cortex, as well as frontal areas including medial frontal gyrus, anterior and posterior cingulate gyri, and even pre-SMA (Jaeger et al. 2014). The authors attribute the increased frontal activity to the participants' efforts to keep their limbs passive and inhibit active motor responses during the passive condition of their task. Furthermore, some neuroimaging studies involving hand movements do report similar a strength of activation between passive and active movement, with greater activity in only small regions in left M1 and S1 during active movement (Szameitat et al. 2012) or activity that is similar in strength and even more localized in passive movement (Formaggio et al. 2013). However, the significant and widespread sensorimotor activation seen in passive compared to active movement in our experiment is not consistent with the literature. Further experiments would be needed to determine exactly why sensorimotor activity was greater in passive compared to active movements. It is possible the sensory feedback from the Velcro strap around the participants' wrist, which was used by experimenters to move their arm, could contribute to the increased activity in somatosensory areas. However, this would not account for the increased activity seen in M1. One possibility is that the experimenter-lead passive movements were greater in range and magnitude than the movements actively performed by the participants. In 2011, an fMRI study by Yu and colleagues reported reduced brain activity when healthy volunteers made movements with less force than previous movements, as measured by a robotic manipulandum (Yu et al. 2011). Video recordings of the task did not reveal perceptively large variations between passive and active movements, although an automated mechanism to measure movement velocity, force and range would be required to accurately assess variations between movements. Inclusion of an MR compatible robotic or mechanical device to control passive movement, in place of an experimenter, would be useful in future experiments directly comparing active and passive movements. With our current experimental design, we cannot discount the possibility that participants unintentionally resisted or assisted the passive movement, despite instructions to remain completely relaxed. Such uninstructed movement could possibly explain the increased M1 involvement. Future neuroimaging experiments could use electromyography (EMG) to record participants' biceps brachii muscle activity during active and passive movement tasks. This would help identify whether participants

are actively engaging their arm muscles during passive movement conditions (Francis et al. 2009).

3.6 Implications for DOC Patients

Overall, the results from the fMRI paradigm in healthy participants indicate that selection between two possible actions requires a greater involvement of high-level associative areas in frontal and parietal cortices than required for following simple commands. Interestingly, seminal post-mortem neuropathological studies identified the presence of fronto-temporal contusions and white matter damage in most patients with a diagnosis of VS at the time of death (Kampfl et al. 1998; Maxwell et al. 2010). Kampfl et al analyzed structural MRI scans of 42 VS patients and found cortical contusions, most commonly in the frontal and temporal lobes, in almost half of patients. White matter damage in the frontal lobes (as well as temporal lobes and corona radiata) was reported in 65% of patients (Kampfl et al. 1998). A quantitative histopathological study on 48 brain-injured patients, classified as moderately disabled, severely disabled and VS, examined neuronal cell loss in the prefrontal, anterior cingulate and motor cortices. They found that the extent of neuronal cell loss was most pronounced in prefrontal regions, and that greater neuronal cell loss corresponded to diagnoses with more severe impairment (Maxwell et al. 2010).

Crucially, more recent structural and functional connectivity studies have revealed marked impairments in associative fronto-parietal areas in VS and MCS patients (Fernández-Espejo et al. 2012; Laureys et al. 1999; Laureys 2005; Juengling et al. 2005; Levine & Levine 2008). Importantly, this damage appeared to correlate with the complexity of the behaviors the patients were able to exhibit (Fernández-Espejo et al. 2012). Although neuropathological changes related to command following and communication have not explicitly been assessed in these studies, it seems reasonable to hypothesize that disruptions in these long-range fronto-parietal networks may explain

why most command following patients have difficulty with the higher decision-making demands associated with communicating with their responses. Future studies directly comparing brain damage in patients who can command follow versus those who can communicate will help to characterize any specific structural damage that may underlie this cognitive distinction.

Another aim of our study was to investigate whether the differences between command following and action selection are dependent on the modality in which the responses are expressed. In our experiment, the modality could be behavioural (motor execution) or mental (motor imagery). A large number of studies have reported covert command following and / or communication in patients who are entirely non-behavioural (Cruse et al. 2011; Goldfine et al. 2012; D. Cruse et al. 2012; Gibson et al. 2014; Coyle D, Stow J, McCreddie K, McElligott J, Carroll A 2014; Owen et al. 2006; Monti et al. 2010; Fernández-Espejo & Owen 2013; Forgacs et al. 2014; Schnakers et al. 2008; Lulé et al. 2013; Pan et al. 2014; Naci & Owen 2013; Monti et al. 2014; Bekinschtein et al. 2011; Bardin et al. 2011). However, some reports suggest that the opposite discrepancy between bedside and neuroimaging capabilities may also exist. For instance, Bardin and colleagues (2011) reported two brain injured patients, from a cohort of seven, who were capable of command following or communication in behavioural assessments but not in neuroimaging paradigms. They proposed that motor imagery requires the same cognitive resources (eg. working memory, task maintenance) that are needed to successfully communicate, and this creates a “resource allocation” problem in brain injured patients. That is, their ability to successfully perform both tasks simultaneously is impaired because the shared cognitive resources required are likely reduced in patients compared to healthy individuals (Bardin et al. 2011). Furthermore, some patients may demonstrate command following using one neuroimaging technique but not the other (Gibson, Fernandez-Espejo, et al., 2014).

Our experiment failed to identify an interaction, even at very low thresholds, between modality and level of selection, suggesting that these two factors may be dissociable. This finding is especially relevant for DOC patients, because it implies that the neural

mechanisms associated with command following and action selection are not dependent on whether the response is overt (motor behavior) or covert (motor imagery). This further supports the hypothesis that a lack of overt behavioural responses does not preclude the existence of preserved cognitive abilities indicative of consciousness in VS patients (Monti et al. 2010). The above discrepancies may then simply represent the well-known false-negatives in neuroimaging paradigms. The prevalence of false negative results in VS patients is difficult to estimate, because of the lack of a reliable “gold-standard” clinical measure to confirm whether a patient is conscious or not (Peterson et al. 2013). However, it is well known that a small proportion (15%) of conscious, healthy volunteers fail to show reliable appropriate brain activity in motor imagery paradigms (Fernández-Espejo et al. 2014; Cruse et al. 2011; Hampshire et al. 2013). Furthermore, abnormal or absent brain activity in these patients could result from multiple other factors, including their unique brain damage and arousal levels, as well as limitations with the neuroimaging technique used (eg. excessive motion artifacts).

This finding provides further support for the use of motor imagery fMRI tasks as a reliable proxy for overt command following and communication in brain-injured patients. A patient who can communicate by selecting between two mental responses in an fMRI scanner could potentially demonstrate the same level of conscious awareness as a patient communicating via behavioural responses at the bedside.

3.7 Passive Movement: Applications for DOC Patients

The passive movement condition in our task revealed a very similar pattern of neural activity to active movement, and these similarities centered mainly around sensorimotor regions. By contrast, frontal regions were recruited differently in passive and active movement, although these differences did not appear when the two were directly compared. Surprisingly, passive movement elicited brain activation equal to or greater than active movement. Further studies, with more precise monitoring of passive movements and any incidental muscle activity, are required to investigate this unexpected finding. In either case, our results suggest that passively moving a participant’s arm can

produce robust brain activity in the fMRI, providing a healthy baseline of activity for comparison with future passive movement experiments in DOC patients. Because passive tasks do not require effortful response from the patient, they can be performed in a wider group of patients, including comatose patients, who can neither move nor imagine moving to command. The intensity and extent of brain activity induced by somatosensory signals associated with passive movement could potentially indicate the functional preservation of a patient's sensorimotor pathways, which may complement prognostic information obtained in SSEP studies

To our knowledge, only one study has examined brain activity associated with passive movement in DOC patients. In a recent experiment by Horki et al., researchers used EEG to study attempted, imagined and passive movements in six MCS patients (Horki et al. 2014). In the motor imagery condition, patients were asked to imagine playing their favourite sport, while in the attempted movement condition, patients were instructed to try to dorsiflex their foot at the ankle. The passive condition was performed in only one patient, and involved a caregiver dorsiflexing the patient's ankle. One of the researchers' aims was to explore whether passive movement could be used to setup an initial classifier in a motor-based BCI, based on the similar sensorimotor activation seen in passive and active movement (Horki et al. 2014). Passive movement in the single patient tested could not be classified successfully above chance, however, the authors did report task-related changes in activity over sensorimotor related brain areas. Furthermore, they noted that when attempted foot movements followed passive foot movement, classification of EEG activity associated with these attempted movements was very accurate (Horki et al 2014).

The potential for passive or observed (Pistoia et al. 2013) movements to improve motor functioning in patients requires further investigation. Many DOC patients receive some form of physical therapy as part of their clinical care. This therapy is primarily designed to prevent muscle atrophy, although it may be possible that the passive movement could stimulate a patient's preserved motor pathways as well. Passive movement could also possibly serve as an indicator of prognosis for brain-injured patients in the acute stage. The absence of somatosensory evoked potentials (SSEPs) elicited by physically

stimulating the hand of coma patients is used clinically as an indicator of poor outcome (Gofton et al. 2009). It is possible that the presence of sensorimotor activity in response to passive movement may have some positive predictive ability in coma patients with an intact SSEP response. Passive movement is an intriguing topic that requires further exploration in this population, especially considering the frequency of motor impairments (Lapitskaya et al. 2013a) and the clinical importance of motor responses for demonstrating conscious awareness (Steven Laureys et al. 2004).

3.8 Conclusion

Our results provide neural evidence that action selection necessary for binary communication involves greater activity in higher associative areas in frontal and parietal regions than command following. This supports an important finding of clinical assessments in DOC patients; that communication involves higher-order cognition than simply responding to a command. We also demonstrated that the cognitive process behind selecting an action may be dissociable from the process of expressing it (through motor execution or imagery). Therefore, a patient may retain the cognitive ability to choose between two actions regardless of whether their ability to overtly execute actions is preserved or impaired. This result thus provides further support for the use of covert assessments of command following and communication as a feasible proxy for traditional bedside behavioural assessments. Finally, the establishment of healthy baseline data for neural responses to passive movement lays the foundation for future passive experiments exploring preserved sensorimotor function in these patients.

References

- Adams, J.H. et al., 1999. The neuropathology of the vegetative state after head injury The neuropathology of the vegetative state after head injury. *Journal of Clinical Pathology*, (September 2006), pp.804–806.
- Adams, J.H., Graham, D.I. & Jennett, B., 2000. The neuropathology of the vegetative state after an acute brain insult. *Brain : a journal of neurology*, 123 (Pt 7, pp.1327–1338.
- Aguirre, G.K., D'Esposito, M. 1999. Experimental design for brain fMRI. *Functional MRI*, Berlin: Springer-Verlag.
- Alary, F. et al., 1998. Event-related potentials elicited by passive movements in humans: characterization, source analysis, and comparison to fMRI. *NeuroImage*, 8(4), pp.377–390.
- Andrews, K. et al., 1996. Misdiagnosis of the vegetative state: retrospective study in a rehabilitation unit. *BMJ (Clinical research ed.)*, 313(7048), pp.13–16.
- Angelakis, E. et al., 2014. Transcranial direct current stimulation effects in disorders of consciousness. *Archives of Physical Medicine and Rehabilitation*, 95(2), pp.283–289. Available at: <http://dx.doi.org/10.1016/j.apmr.2013.09.002>.
- Aron, A.R., Robbins, T.W. & Poldrack, R. a., 2004. Inhibition and the right inferior frontal cortex. *Trends in Cognitive Sciences*, 8(4), pp.170–177.
- Bardin, J.C. et al., 2011. Dissociations between behavioural and functional magnetic resonance imaging-based evaluations of cognitive function after brain injury. *Brain*, 134(3), pp.769–782.
- Bekinschtein, T.A. et al., 2011. Functional imaging reveals movement preparatory activity in the vegetative state. *Frontiers in human neuroscience*, 5(January), p.5.
- Bergsneider, M. et al., 2001. Metabolic recovery following human traumatic brain injury based on FDG-PET: time course and relationship to neurological disability. *The Journal of head trauma rehabilitation*, 16(2), pp.135–148.
- De Biase, S. et al., 2014. The importance of polysomnography in the evaluation of prolonged disorders of consciousness: Sleep recordings more adequately correlate than stimulus-related evoked potentials with patients' clinical status. *Sleep Medicine*, 15(4), pp.393–400. Available at: <http://dx.doi.org/10.1016/j.sleep.2013.09.026>.
- Boly, M. et al., 2004. Auditory processing in severely brain injured patients: differences between the minimally conscious state and the persistent vegetative state. *Archives of Neurology*, 61(9), pp.233–8.
- Boly, M. et al., Cerebral processing of auditory and noxious stimuli in severely brain injured patients: differences between VS and MCS. *Neuropsychological rehabilitation*, 15(3-4), pp.283–289.
- Boly, M. et al., 2007. When thoughts become action: An fMRI paradigm to study volitional brain activity in non-communicative brain injured patients. *NeuroImage*, 36(3), pp.979–992. Available at: <http://dx.doi.org/10.1016/j.neuroimage.2007.02.047>.
- Brass, M. & Haggard, P., 2007. To do or not to do: the neural signature of self-control. *The Journal of neuroscience : the official journal of the Society for Neuroscience*, 27(34), pp.9141–9145.

- Bruno, M. a. et al., 2010. Disorders of consciousness: Moving from passive to resting state and active paradigms. *Cognitive Neuroscience*, 1(3), pp.193–203.
- Burianová, H. et al., 2013. Multimodal functional imaging of motor imagery using a novel paradigm. *NeuroImage*, 71, pp.50–58. Available at: <http://dx.doi.org/10.1016/j.neuroimage.2013.01.001>.
- Carrillo-de-la-Peña, M.T., Galdo-Álvarez, S. & Lastra-Barreira, C., 2008. Equivalent is not equal: Primary motor cortex (MI) activation during motor imagery and execution of sequential movements. *Brain Research*, 1226(Mi), pp.134–143.
- Childs, N., Mercer, W. & HW, C., 1993. Accuracy of diagnosis of persistent vegetative state. *Neurology*, 43(8), pp.1465–7.
- Cisek, P. & Kalaska, J.F., 2010. Neural mechanisms for interacting with a world full of action choices. *Annual review of neuroscience*, 33, pp.269–298.
- Coleman, M.R. et al., 2007. Do vegetative patients retain aspects of language comprehension? Evidence from fMRI. *Brain*, 130(10), pp.2494–2507.
- Coyle D, Stow J, McCreadie K, McElligott J, Carroll A, 2014. Sensorimotor Modulation Assessment and Brain-Computer Interface Training in Disorders of Consciousness. *Archives of Physical Medicine and Rehabilitation*, in press, pp.62–70.
- Cruse, D. et al., 2011. Bedside detection of awareness in the vegetative state: A cohort study. *The Lancet*, 378(9809), pp.2088–2094.
- Cruse, D. et al., 2012. Detecting Awareness in the Vegetative State: Electroencephalographic Evidence for Attempted Movements to Command. *PLoS ONE*, 7(11), pp.1–9.
- Cruse, D. et al., 2014. Positive Prognostication from Median-Nerve Somatosensory Evoked Cortical Potentials. *Neurocritical Care*, 21(2), pp.238–244. Available at: <http://link.springer.com/10.1007/s12028-014-9982-y>.
- Cruse, D. et al., 2012. Relationship between etiology and covert cognition in the minimally conscious state. *Neurology*, 78(11), pp.816–822.
- Deiber, M.P. et al., 1999. Mesial motor areas in self-initiated versus externally triggered movements examined with fMRI: effect of movement type and rate. *Journal of neurophysiology*, 81(6), pp.3065–3077.
- Estévez, N. et al., 2014. A Reliability Study on Brain Activation During Active and Passive Arm Movements Supported by an MRI-Compatible Robot. *Brain Topography*.
- Estraneo, a. et al., 2014. A multicentre study of intentional behavioural responses measured using the Coma Recovery Scale-Revised in patients with minimally conscious state. *Clinical Rehabilitation*. Available at: <http://cre.sagepub.com/cgi/doi/10.1177/0269215514556002>.
- Farrer, C. et al., 2003. Modulating the experience of agency: A positron emission tomography study. *NeuroImage*, 18(2), pp.324–333.
- Farrer, C. et al., 2008. The angular gyrus computes action awareness representations. *Cerebral Cortex*, 18(2), pp.254–261.

- Farrer, C. & Frith, C.D., 2002. Experiencing oneself vs another person as being the cause of an action: the neural correlates of the experience of agency. *NeuroImage*, 15(3), pp.596–603.
- Fernández-Espejo, D. et al., 2012. A role for the default mode network in the bases of disorders of consciousness. *Annals of Neurology*, 72(3), pp.335–343.
- Fernández-Espejo, D. et al., 2008. Cerebral response to speech in vegetative and minimally conscious states after traumatic brain injury. *Brain injury : [BI]*, 22(11), pp.882–890.
- Fernández-Espejo, D. et al., 2011. Diffusion weighted imaging distinguishes the vegetative state from the minimally conscious state. *NeuroImage*, 54(1), pp.103–112. Available at: <http://dx.doi.org/10.1016/j.neuroimage.2010.08.035>.
- Fernández-Espejo, D. et al., 2010. Reductions of thalamic volume and regional shape changes in the vegetative and the minimally conscious states. *Journal of neurotrauma*, 27(7), pp.1187–1193.
- Fernández-Espejo, D., Norton, L. & Owen, A.M., 2014. The clinical utility of fMRI for identifying covert awareness in the vegetative state: A comparison of sensitivity between 3T and 1.5T. *PLoS ONE*, 9(4), pp.1–9.
- Fernandez-Espejo D, Rossit S, Owen AM. I can only imagine; the overt versus covert paradox in the Vegetative State. *JAMA Neurology*, accepted.
- Fernández-Espejo, D. & Owen, A.M., 2013. Detecting awareness after severe brain injury. *Nature reviews. Neuroscience*, 14(11), pp.801–9. Available at: <http://www.ncbi.nlm.nih.gov/pubmed/24088810>.
- Fins, J.J., 2003. Constructing an ethical stereotaxy for severe brain injury: balancing risks, benefits and access. *Nat Rev Neuroscience*, 4(April), pp.3–7.
- Fischer, C., Dailler, F. & Morlet, D., 2008. Novelty P3 elicited by the subject's own name in comatose patients. *Clinical Neurophysiology*, 119(10), pp.2224–2230.
- Forgacs, P.B. et al., 2014. Preservation of electroencephalographic organization in patients with impaired consciousness and imaging-based evidence of command-following. *Annals of Neurology*, 76(6), pp.869–879.
- Formaggio, E. et al., 2013. Modulation of event-related desynchronization in robot-assisted hand performance: brain oscillatory changes in active, passive and imagined movements. *Journal of neuroengineering and rehabilitation*, 10(1), p.24. Available at: <http://www.pubmedcentral.nih.gov/articlerender.fcgi?artid=3598512&tool=pmcentrez&rendertype=abstract>.
- Francis, S. et al., 2009. fMRI analysis of active, passive and electrically stimulated ankle dorsiflexion. *NeuroImage*, 44(2), pp.469–479. Available at: <http://dx.doi.org/10.1016/j.neuroimage.2008.09.017>.
- Friston, K.J. et al., 1995. Characterizing Evoked Hemodynamics with fMRI. *NeuroImage*, 2(2), pp.157–165.
- Gerardin, E. et al., 2000. Partially overlapping neural networks for real and imagined hand movements. *Cerebral cortex (New York, N.Y. : 1991)*, 10(11), pp.1093–1104.

- Gibson, R.M. et al., 2014. Multiple tasks and neuroimaging modalities increase the likelihood of detecting covert awareness in patients with disorders of consciousness. *Frontiers in Human Neuroscience*, 8(November), pp.1–9. Available at: <http://journal.frontiersin.org/article/10.3389/fnhum.2014.00950/abstract>.
- Gill-Thwaites, H. & Munday, R., 2004. The Sensory Modality Assessment and Rehabilitation Technique (SMART): a valid and reliable assessment for vegetative state and minimally conscious state patients. *Brain Injury*, 18(12), pp.1255–69.
- Gleichgerricht, E. et al., 2010. Decision-making cognition in neurodegenerative diseases. *Nature reviews. Neurology*, 6(11), pp.611–623. Available at: <http://dx.doi.org/10.1038/nrneurol.2010.148>.
- Gofton, T.E. et al., 2009. Functional MRI study of the primary somatosensory cortex in comatose survivors of cardiac arrest. *Experimental Neurology*, 217(2), pp.320–327. Available at: <http://dx.doi.org/10.1016/j.expneurol.2009.03.011>.
- Goldfine, A.M. et al., 2012. Bedside detection of awareness in the vegetative state. *Lancet*, 379(9827), pp.1701–1702.
- Gowen, E. & Miall, R.C., 2007. Differentiation between external and internal cuing: An fMRI study comparing tracing with drawing. *NeuroImage*, 36(2), pp.396–410.
- Graham, D.I. et al., 2005. Novel aspects of the neuropathology of the vegetative state after blunt head injury. *Progress in Brain Research*, 150, pp.445–455.
- Grefkes, C. et al., 2008. Dynamic intra- and interhemispheric interactions during unilateral and bilateral hand movements assessed with fMRI and DCM. *NeuroImage*, 41(4), pp.1382–1394.
- Guger, C. et al., 2003. How many people are able to operate an EEG-based brain-computer interface (BCI)? *IEEE Transactions on Neural Systems and Rehabilitation Engineering*, 11(2), pp.145–147.
- Guldenmund, P. et al., 2012. Mindsight: Diagnostics in disorders of consciousness. *Critical Care Research and Practice*, 2012.
- Haggard, P., 2008. Human volition: towards a neuroscience of will. *Nature reviews. Neuroscience*, 9(12), pp.934–946.
- Hampshire, A. et al., 2013. Assessing residual reasoning ability in overtly non-communicative patients using fMRI. *NeuroImage: Clinical*, 2(1), pp.174–183. Available at: <http://dx.doi.org/10.1016/j.nicl.2012.11.008>.
- Hayashi, M.J. et al., 2008. Hemispheric asymmetry of frequency-dependent suppression in the ipsilateral primary motor cortex during finger movement: A functional magnetic resonance imaging study. *Cerebral Cortex*, 18(12), pp.2932–2940.
- Horki, P. et al., 2014. Detection of mental imagery and attempted movements in patients with disorders of consciousness using EEG. *Frontiers in Human Neuroscience*, 8(December), pp.1–9. Available at: <http://journal.frontiersin.org/article/10.3389/fnhum.2014.01009/abstract>.
- Jaeger, L. et al., 2014. Brain activation associated with active and passive lower limb stepping. *Frontiers in Human Neuroscience*, 8(October), pp.1–14. Available at: <http://journal.frontiersin.org/article/10.3389/fnhum.2014.00828/abstract>.

- Jahanshahi, M. et al., 1995. Self-Initiated Versus Externally Triggered Movements .I. an Investigation Using Measurement of Regional Cerebral Blood-Flow With Pet and Movement-Related Potentials in Normal and Parkinsons-Disease Subjects. *Brain*, 118, pp.913–933. Available at: <http://discovery.ucl.ac.uk/128510/>.
- James M. Kilner, Paulignan, Y. & Boussaoud, D., 2004. Functional connectivity during real vs imagined visumotor tasks: an EEG study. *Neuroreport*, 15(4), pp.637 – 642.
- Jankelowitz, S.K. & Colebatch, J.G., 2002. Movement-related potentials associated with self-paced, cued and imagined arm movements. *Experimental Brain Research*, 147(1), pp.98–107.
- Jeannerod, M., 1995. Mental imagery in the motor context. *Neuropsychologia*, 33(11), pp.1419–1432.
- Jenkins, I.H. et al., 2000. Self-initiated versus externally triggered movements. II. The effect of movement predictability on regional cerebral blood flow. *Brain : a journal of neurology*, 123 (Pt 6, pp.1216–1228.
- Jennett, B. et al., 2001. Neuropathology in vegetative and severely disabled patients after head injury. *Neurology*, 56(4), pp.486–490.
- Jin, S.-H. & Chung, C.K., 2012. Messages from the Brain Connectivity Regarding Neural Correlates of Consciousness. *Experimental Neurobiology*, 21(3), p.113.
- Juengling, F.D. et al., 2005. Separating functional and structural damage in persistent vegetative state using combined voxel-based analysis of 3-D MRI and FDG-PET. *Journal of the neurological sciences*, 228(2), pp.179–184.
- Kalmar, K. & Giacino, J.T., 2007. The JFK Coma Recovery Scale--Revised. *Neuropsychological rehabilitation*, 15(3-4), pp.454–460.
- Kampfl, a et al., 1998. The persistent vegetative state after closed head injury: clinical and magnetic resonance imaging findings in 42 patients. *Journal of neurosurgery*, 88(5), pp.809–816.
- Korvenoja et al., 1999. Activation of multiple cortical areas in response to somatosensory stimulation: combined magnetoencephalographic and functional magnetic resonance imaging. *Human Brain Mapping*, 8, pp13-27.
- Kübler, A. & Kotchoubey, B., 2007. Brain-computer interfaces in the continuum of consciousness. *Current opinion in neurology*, 20(6), pp.643–649.
- Lapitskaya, N. et al., 2013a. Abnormal corticospinal excitability in patients with disorders of consciousness. *Brain Stimulation*, 6(4), pp.590–597. Available at: <http://dx.doi.org/10.1016/j.brs.2013.01.002>.
- Lapitskaya, N. et al., 2013b. Abnormal corticospinal excitability in patients with disorders of consciousness. *Brain Stimulation*, 6(4), pp.590–597.
- Lau, H.C. et al., 2004. Attention to intention. *Science (New York, N.Y.)*, 303(5661), pp.1208–10. Available at: <http://www.ncbi.nlm.nih.gov/pubmed/14976320>.
- Laureys, S. et al., 2004. Cerebral processing in the minimally conscious state. *Neurology*, 63(5), pp.916–918.

- Laureys, S. et al., 2002. Cortical processing of noxious somatosensory stimuli in the persistent vegetative state. *NeuroImage*, 17(2), pp.732–741.
- Laureys, S. et al., 1999. Impaired effective cortical connectivity in vegetative state: preliminary investigation using PET. *NeuroImage*, 9(4), pp.377–382.
- Laureys, S., 2005. The neural correlate of (un)awareness: Lessons from the vegetative state. *Trends in Cognitive Sciences*, 9(12), pp.556–559.
- Laureys, S., Owen, A.M. & Schiff, N.D., 2004. Brain function in coma, vegetative state, and related disorders. *The Lancet*, 3(September), pp.537–546.
- Levine, B. & Levine, B., 2008. The Toronto traumatic brain injury study. *Neurology*, pp.771–778.
- Logi, F. et al., 2003. The prognostic value of evoked responses from primary somatosensory and auditory cortex in comatose patients. *Clinical Neurophysiology*, 114(9), pp.1615–1627.
- Lotze, M. & Halsband, U., 2006. Motor imagery. *Journal of Physiology Paris*, 99(4-6), pp.386–395.
- Lulé, D. et al., 2013. Probing command following in patients with disorders of consciousness using a brain-computer interface. *Clinical Neurophysiology*, 124(1), pp.101–106.
- Machado, S. et al., 2013. Changes in Cortical Activity During Real and Imagined Movements : an ERP Study. *Clinical Practice & Epidemiology in Mental Health*, 9, pp.196–201.
- Maxwell, W.L. et al., 2010. Stereology of cerebral cortex after traumatic brain injury matched to the Glasgow Outcome Score. *Brain*, 133(1), pp.139–160.
- McCormick, D. a & Bal, T., 1997. Sleep and arousal: thalamocortical mechanisms. *Annual review of neuroscience*, 20, pp.185–215.
- Menon DK, Owen AM, Williams EJ, Minhas PS, Allen CMC, Boniface SJ, Pickard JD, W.B.I.C.T., 1998. Cortical processing in persistent vegetative state. *Lancet*, 352(9134), pp.1148–1149.
- Michelon, P., Vettel, J.M. & Zacks, J.M., 2006. Lateral somatotopic organization during imagined and prepared movements. *Journal of neurophysiology*, 95(2), pp.811–822.
- Mokienko, O. a et al., 2013. Increased motor cortex excitability during motor imagery in brain-computer interface trained subjects. *Frontiers in Computational Neuroscience*, 7(November), p.168. Available at:
<http://www.pubmedcentral.nih.gov/articlerender.fcgi?artid=3837244&tool=pmcentrez&rendertype=abstract>.
- Monti, M.M. et al., 2014. Thalamo-frontal connectivity mediates top-down cognitive functions in disorders of consciousness. *Neurology*, 84, pp.167–173.
- Monti, M.M. et al., 2010. Willful Modulation of Brain Activity in Disorders of Consciousness. *the New England Journal of Medicine* *the New England Journal of Medicine*, 362(7), pp.579–589.
- Monti, M.M., Coleman, M.R. & Owen, A.M., 2009. Neuroimaging and the vegetative state: Resolving the behavioral assessment dilemma? *Annals of the New York Academy of Sciences*, 1157, pp.81–89.

- Monti, M.M., Pickard, J.D. & Owen, A.M., 2013. Visual cognition in disorders of consciousness: From V1 to top-down attention. *Human Brain Mapping*, 34(6), pp.1245–1253.
- Mostofsky, S.H. et al., 2003. fMRI evidence that the neural basis of response inhibition is task-dependent. *Cognitive Brain Research*, 17(2), pp.419–430.
- Mostofsky, S.H. & Simmonds, D.J., 2008. Response inhibition and response selection: two sides of the same coin. *Journal of cognitive neuroscience*, 20(5), pp.751–761.
- Multi-Society Task Force on PVS, 1994. Medical aspects of the persistent vegetative state (1). The Multi-Society Task Force on PVS. *New England Journal of Medicine*, 330(21), pp.1499–508.
- Nachev, P. et al., 2005. Europe PMC Funders Group Volition and conflict in human medial frontal cortex. *Curr Biol*, 15(2), pp.122–128.
- Nachev, P. et al., 2007. The role of the pre-supplementary motor area in the control of action. *NeuroImage*, 36(SUPPL. 2), pp.T155–T163. Available at: <http://dx.doi.org/10.1016/j.neuroimage.2007.03.034>.
- Naci, L. et al., 2014. A common neural code for similar conscious experiences in different individuals. *Proc Natl Acad Sci U S A*, pp.1–6.
- Naci, L. et al., 2013. The Brain's Silent Messenger: Using Selective Attention to Decode Human Thought for Brain-Based Communication. *Journal of Neuroscience*, 33(22), pp.9385–9393. Available at: <http://www.jneurosci.org/cgi/doi/10.1523/JNEUROSCI.5577-12.2013>.
- Naci, L. & Owen, A.M., 2013. Making every word count for nonresponsive patients. *JAMA neurology*, 70(10), pp.1235–41. Available at: <http://www.ncbi.nlm.nih.gov/pubmed/23939634>.
- Noirhomme, Q. et al., 2010. Brain connectivity in pathological and pharmacological coma. *Frontiers in systems neuroscience*, 4(December), p.160.
- Owen, A.M. et al., 2006. Detecting Awareness in the Vegetative State. *Science*, 313(5792), pp.7–8.
- Owen, A.M., 2011. Detecting Consciousness: A Unique Role for Neuroimaging. *Annual Review of Psychology*, 64(1), p.121008173700008.
- Owen, A.M. et al., 2002. Detecting residual cognitive function in persistent vegetative state. *Neurocase*, 8(5), pp.394–403.
- Pan, J. et al., 2014. Detecting awareness in patients with disorders of consciousness using a hybrid brain-computer interface. *Journal of neural engineering*, 11(5), p.056007. Available at: <http://www.ncbi.nlm.nih.gov/pubmed/25082743>.
- Perrin, F. et al., 2006. Brain response to one's own name in vegetative state, minimally conscious state, and locked-in syndrome. *Archives of neurology*, 63(4), pp.562–569.
- Peterson, A. et al., 2013. Assessing decision-making capacity in the behaviorally nonresponsive patient with residual covert awareness. *AJOB Neuroscience*, 4(4), pp.3–14. Available at: <http://www.tandfonline.com/doi/abs/10.1080/21507740.2013.821189>.
- Pistoia, F. et al., 2013. Corticomotor facilitation in vegetative state: Results of a pilot study. *Archives of Physical Medicine and Rehabilitation*, 94(8), pp.1599–1606.

- Porro, C. a et al., 1996. Primary motor and sensory cortex activation during motor performance and motor imagery: a functional magnetic resonance imaging study. *The Journal of neuroscience : the official journal of the Society for Neuroscience*, 16(23), pp.7688–7698.
- Rudolf, J. et al., 1999. Cerebral glucose metabolism in acute and persistent vegetative state. *J Neurosurg Anesthesiol*, 11, pp.17–24.
- Schiff, N.D., 2008. Central thalamic contributions to arousal regulation and neurological disorders of consciousness. *Annals of the New York Academy of Sciences*, 1129, pp.105–118.
- Schiff, N.D., 2010. Recovery of consciousness after brain injury: a mesocircuit hypothesis. *Trends in Neurosciences*, 33(1), pp.1–9.
- Schnakers, C., 2012. Clinical assessment of patients with disorders of consciousness. *Archives Italiennes de Biologie*, 150(2-3), pp.36–43.
- Schnakers, C. et al., 2009. Diagnostic accuracy of the vegetative and minimally conscious state: clinical consensus versus standardized neurobehavioral assessment. *BMC neurology*, 9, p.35.
- Schnakers, C. et al., 2008. Voluntary brain processing in disorders of consciousness. *Neurology*, 71(20), pp.1614–1620.
- Sharp, D.J. et al., 2010. Distinct frontal systems for response inhibition, attentional capture, and error processing. *Proceedings of the National Academy of Sciences of the United States of America*, 107(13), pp.6106–6111.
- Shiel, A. et al., 2000. The Wessex Head Injury Matrix (WHIM) main scale: a preliminary report on a scale to assess and monitor patient recovery after severe head injury. *Clinical rehabilitation*, 14(4), pp.408–416.
- Smith, D.H., Meaney, D.F. & Shull, W.H., 2003. Diffuse axonal injury in head trauma. *J Head Trauma Rehabil*, 18(4), pp.307–316. Available at: http://www.ncbi.nlm.nih.gov/entrez/query.fcgi?cmd=Retrieve&db=PubMed&dopt=Citation&list_uids=16222127.
- Solbakk, A.-K. et al., 2014. Impact of Orbitofrontal Lesions on Electrophysiological Signals in a Stop Signal Task. *J Cogn Neurosci*, 26(7), pp.1528–1545.
- Stephan, K. et al., 1995. Functional-Anatomy of the Mental Representation of Upper Extremity Movements in Healthy-Subjects. *Journal of neurophysiology*, 73(1). Available at: <http://discovery.ucl.ac.uk/595965/>.
- Szameitat, A.J. et al., 2012. Cortical activation during executed, imagined, observed, and passive wrist movements in healthy volunteers and stroke patients. *NeuroImage*, 62(1), pp.266–280. Available at: <http://dx.doi.org/10.1016/j.neuroimage.2012.05.009>.
- Teasdale, G. & Jennett, B., 1974. Assessment of Coma and Impaired Consciousness: A Practical Scale. *The Lancet*, 304(7872), pp.81–84.
- De Tommaso, M. et al., 2013. Pain in prolonged disorders of consciousness: Laser evoked potentials findings in patients with vegetative and minimally conscious states. *Brain Injury*, 27(7-8), pp.962–972. Available at:

<http://ovidsp.ovid.com/ovidweb.cgi?T=JS&PAGE=reference&D=psyc8&NEWS=N&AN=2013-22828-027>.

- Tsakiris, M. et al., 2007. Neural signatures of body ownership: A sensory network for bodily self-consciousness. *Cerebral Cortex*, 17(10), pp.2235–2244.
- Vanhaudenhuyse, A. et al., 2012. *Coma and Disorders of Consciousness* C. Schnakers & S. Laureys, eds., Springer London. Available at: <http://link.springer.com/book/10.1007%2F978-1-4471-2440-5>.
- Vanhaudenhuyse, A., Laureys, S. & Perrin, F., 2008. Cognitive event-related potentials in comatose and post-comatose states. *Neurocritical Care*, 8(2), pp.262–270.
- Weeks, R. a et al., 2001. Comparison of auditory, somatosensory, and visually instructed and internally generated finger movements: a PET study. *NeuroImage*, 14(1 Pt 1), pp.219–230.
- Whyte, J., DiPasquale, M.C. & Vaccaro, M., 1999. Assessment of command-following in minimally conscious brain injured patients. *Archives of Physical Medicine and Rehabilitation*, 80(6), pp.653–660.
- Wiese, H. et al., 2004. Movement preparation in self-initiated versus externally triggered movements: An event-related fMRI-study. *Neuroscience Letters*, 371(2-3), pp.220–225.
- Wijdicks, E.F.M. et al., 2005. Validation of a new coma scale: The FOUR score. *Annals of Neurology*, 58(4), pp.585–593.
- Xu, L. et al., 2014. Motor execution and motor imagery: A comparison of functional connectivity patterns based on graph theory. *Neuroscience*, 261, pp.184–194.
- Yu, N. et al., 2011. FMRI assessment of upper extremity related brain activation with an MRI-compatible manipulandum. *International Journal of Computer Assisted Radiology and Surgery*, 6(3), pp.447–455.

Appendix I

For all analyses in this thesis, the FSL Harvard-Oxford Cortical and Subcortical Structural Atlases were used for anatomical identification, which can be found at this link <http://fsl.fmrib.ox.ac.uk/fsl/fslwiki/Atlases>. The authors of the atlas have asked for the following statement to be included when acknowledging the atlas: We are very grateful for the training data for FIRST, particularly to David Kennedy at the CMA, and also to: Christian Haselgrove, Centre for Morphometric Analysis, Harvard; Bruce Fischl, Martinos Center for Biomedical Imaging, MGH; Janis Breeze and Jean Frazier, Child and Adolescent Neuropsychiatric Research Program, Cambridge Health Alliance; Larry Seidman and Jill Goldstein, Department of Psychiatry of Harvard Medical School; Barry Kosofsky, Weill Cornell Medical Center.

Appendix II: Ethics



Research Ethics

Use of Human Participants - Ethics Approval Notice

Principal Investigator: Dr. Adrian Owen
 File Number: 100070
 Review Level: Delegated
 Approved Local Adult Participants: 500
 Approved Local Minor Participants: 0
 Protocol Title: Neural mechanisms of executive control 17886E
 Department & Institution: Social Science/ Psychology, Western University
 Sponsor:
 Ethics Approval Date: May 07, 2013 Expiry Date: December 31, 2017
 Documents Reviewed & Approved & Documents Received for Information:

Document Name	Comments	Version Date
Change in Study Personnel		
Revised Western University Protocol		
Revised Letter of Information & Consent		
Advertisement	Revised	

This is to notify you that The University of Western Ontario Research Ethics Board for Health Sciences Research Involving Human Subjects (HSREB) which is organized and operates according to the Tri-Council Policy Statement: Ethical Conduct of Research Involving Humans and the Health Canada/CH Good Clinical Practice Practices: Consolidated Guidelines; and the applicable laws and regulations of Ontario has reviewed and granted approval to the above referenced revision(s) or amendment(s) on the approval date noted above. The membership of this REB also complies with the membership requirements for REB's as defined in Division 5 of the Food and Drug Regulations.

The ethics approval for this study shall remain valid until the expiry date noted above assuming timely and acceptable responses to the HSREB's periodic requests for surveillance and monitoring information. If you require an updated approval notice prior to that time you must request it using the University of Western Ontario Updated Approval Request Form.

Members of the HSREB who are named as investigators in research studies, or declare a conflict of interest, do not participate in discussion related to, nor vote on, such studies when they are presented to the HSREB.

The Chair of the HSREB is Dr. Joseph Gilbert. The HSREB is registered with the U.S. Department of Health & Human Services under the IRB registration number IRB 0000940.

Ethics Officer to Contact for Further Information

Erika Basile (ebasile@uwo.ca)	Trace Kelly (trace.kelly@uwo.ca)	Stained Walcott (swalcot@uwo.ca)
----------------------------------	-------------------------------------	-------------------------------------

This is an official document. Please retain the original in your files.

Curriculum Vitae

Name: Natalie Osborne

Post-secondary Education and Degrees: University of Guelph
Guelph, Ontario, Canada
2008-2012 B.Sc. (Honours Biomedical Sciences)

The University of Western Ontario
London, Ontario, Canada
2013-2015 M.Sc. (Psychology)

Honours and Awards: Ontario Graduate Scholarship (OGS)
2013-2014, 2014-2015

Western Graduate Research Scholarship
2013-2014, 2014-2015

Biomedical Sciences Research Award of Merit
June 2012

Related Work Experience Teaching Assistant
The University of Western Ontario
2013-2015

Publications:

Osborne, N. Owen, A & Fernández-Espejo, D. The dissociation between command following and communication in disorders of consciousness: an fMRI study in healthy subjects. *Frontiers in Human Neuroscience*. Accepted, Aug. 24th 2015.

Osborne, N., Levy, AM., & Leri, F. Interaction between Classical and Instrumental conditioning during passive and active intravenous administration of heroin. in-preparation (*this paper is based on work from my undergraduate thesis project*)

Presentations:

Osborne, N., Owen, A. & Fernández-Espejo, D. (2015). Residual sensorimotor function in Disorders of Consciousness. Poster presented at the 19th Annual Meeting of the Association for the Scientific Study of Consciousness. Paris, France. July 7th–10th, 2015.

Osborne, N., Owen, A. & Fernández-Espejo, D. (2015). Investigating brain responses to passive movements of the arm in disorders of consciousness. Poster presented at the 25th Annual Rotman Research Institute Conference. Toronto, ON, Canada, March 9th–11th, 2015.