Western University
Scholarship@Western

Anthropology Presentations | Anthropology

5-1-2009

Paget ' s Disease (Osteitis Deformans) in Archaeological Remains: A Radiographic Differential

Andrew D. Wade
The University of Western Ontario, awade4@uwo.ca

Gregory J. Garvin
The University of Western Ontario, ggarvin@sympatico.ca

David W. Holdsworth
The University of Western Ontario, dholdswo@uwo.ca

Follow this and additional works at: http://ir.lib.uwo.ca/anthropres

Part of the Archaeological Anthropology Commons, and the Bioimaging and biomedical optics Commons

Citation of this paper:

Wade, Andrew D.; Garvin, Gregory J.; and Holdsworth, David W., "Paget ' s Disease (Osteitis Deformans) in Archaeological Remains: A Radiographic Differential" (2009). *Anthropology Presentations.* Paper 7.
http://ir.lib.uwo.ca/anthropres/7

Paget's Disease (*Osteitis Deformans*) in Archaeological Remains: A Radiographic Differential

Andrew D Wade[1], Gregory J Garvin[2], David W Holdsworth[3]

Department of [1]Anthropology and [2]Schulich School of Medicine and Dentistry, University of Western Ontario & [3]St.Joseph's Health Care, London

Introduction

Paget's disease of bone is a metabolic bone disease of unknown etiology and is the most likely disease to cause secondary bone cancer; a prevalence that increases with age[1]. With the increasing age of modern populations, the importance of better understanding this disease will likewise increase. While *in vivo* tests for the disease cannot be performed in skeletal samples, radiographic views of archaeological remains can provide insight into the origins and natural history of the disease.

Paget's Disease

Disrupts bone remodelling [2]:

- increase in bone resorption
- increase in bone formation
- formation of weaker osteoid
- most common in males over 40

Untreated it can cause [2]:

- bowing of the long bones
- constriction of joints
- constriction of eyes
- constriction of brain
- secondary osteosarcoma

Methods & Materials

The case discussed here [3] is an individual from the Grant skeletal collection; part of a sample selected for a study of age-related trabecular change in the pubis [4].

Individual 669

- 66 year old male
- died of a heart attack

Plain film x-rays:

- left pubis
- both pelves
- both femurs
- spine
- skull

CT scans:

- left pubis
- both pelves
- both femurs
- spine
- skull

Micro-CT scan:

- left pubis

Pelvis

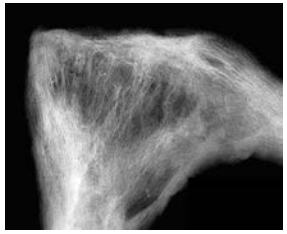

This plain film radiograph of the left pubis, *demonstrating diffuse sclerosis, well-defined lucencies, cortical thickening, and significant trabecular thickening*, was the initial indicator of a pathological condition in this individual.

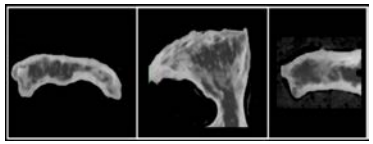

CT and micro-CT scans of the left pubis also demonstrated greatly increased cortical thickness and a dramatic rarification of trabeculae.

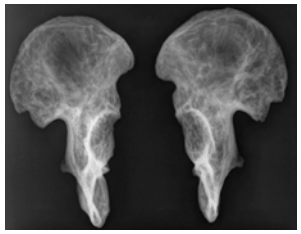

Plain film radiographs of the pelves exhibit diffuse sclerosis, well-defined lucencies, cortical thickening, and fewer but thicker trabeculae.

Spine

Plain film radiographs of the cervical spine show minimal-to-mild sclerosis of the atlas (C1), mild sclerosis of the axis (C2). Cervical vertebrae, C4 and C7, are diffusely sclerotic.

The CT scan of the cervical spine also reveals greatly thickened cortex and coarse, irregular trabeculae in C4 and C7.

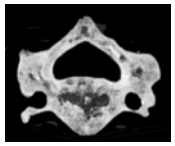

Plain film radiographs of the lumbar spine show involvement of the 1st and 3rd lumbar vertebrae, with thickening of both trabeculae and end plates.

Skull

Plain film radiographs of the skull demonstrate minimal pathological involvement, with only the right frontal bone demonstrating patchy sclerosis laterally.

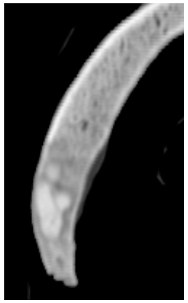

The CT scan of the skull also shows patchy bilateral sclerosis, with well-defined surrounding lucency and cranial thickening.

Femur

Plain film radiographs and the CT scan of the femora demonstrate indications of a pathological process in the proximal half of the left femur. The cortex and trabeculae the left femur are thickened relative to the right.

Differential Diagnosis

Paget's Disease of Bone [2]

- ✓ regional involvement
- ✓ mild expansion
- ✓ cortical thickening
- ✓ trabecular thickening
- ✓ trabecular rarification

Osteitis Ilii Condensans [5]

- ✗ increased density of ilium
- ✗ no trabecular rarification

Fibrous Dysplasia

- ✓ expansion of bone
- ✓ variable density
- ✗ ground glass opacity
- ✗ cortical thinning

Metastatic Cancer [5]

- ✗ isolated sclerotic lesions
- ✗ irregular bony expansion

Hyperphosphatasia [2] ("Juvenile Paget's")

- ✓ similar to Paget's
- ✗ shortened stature
- ✗ skeletal malformation

Conclusions

This case study demonstrates the power of radiography, particularly CT and micro-CT, in diagnosing pathological conditions such as Paget's disease of bone. The cultural sensitivity and importance of archaeological human remains precludes the use of destructive techniques in their analysis. Where biochemistry and bone scans are also impossible, the ability to non-destructively assess the thickness and quality of bone is key to an accurate differential diagnosis of Paget's disease of bone.

Literature cited

[1] Moore TE, King AR, Kathol MH, El-Khoury GY, Palmer R, Downey PR. 1991. Sarcoma in Paget disease of bone: Clinical, radiologic, and pathologic features in 22 cases. *American Journal of Roentgenology* 156 : 119-1203

[2] Kanis JA. 1998. *Pathophysiology and Treatment of Paget's Disease of Bone, Second edition.* Martin Dunitz: London, UK

[3] Wade AD, Garvin G, Holdsworth DW. Submitted. CT and micro-CT analysis of a case of Paget's disease (osteitis deformans) in the Grant skeletal collection. *International Journal of Osteoarchaeology*

[4] Wade AD. 2008. Radiological assessment of age-related change in the trabecular structure of the human os *pubis.* MA Thesis. University of Western Ontario

[5] Cushing FR, and Bone HG. 2002. Radiographic diagnosis and laboratory evaluation of Paget's disease of bone. *Clinical Review in Bone and Mineral Metabolism* 1(2) : 115-134

Acknowledgments

Scanning time was donated by St. Joseph's Healthcare, London (CT), by the Toronto Hospital for Sick Children (CR, DR, & CT), and by the Robarts Research Institute (micro-CT). We thank Karen Betteridge and Rosemary Miller at St.Joseph's, Stephanie Holowka at Sick Kid's, and Joseph Umoh at Robarts for technical assistance. Skeletal samples were provided by the Grant Skeletal Collection.

For further information

Please contact *awade4@uwo.ca*.
Andrew Wade
c/o Department of Anthropology,
Social Science Centre
University of Western Ontario,
London, ON, N6A 5C2

Western