Western University
Scholarship@Western

Anthropology Presentations | Anthropology

4-1-2010

Another Hole in the Head? Brain Treatment in Ancient Egyptian Mummies

Andrew D. Wade
The University of Western Ontario, awade4@uwo.ca

Andrew J. Nelson
The University of Western Ontario, anelson@uwo.ca

Gregory J. Garvin
The University of Western Ontario, ggarvin@sympatico.ca

Follow this and additional works at: http://ir.lib.uwo.ca/anthropres

Part of the Archaeological Anthropology Commons

Citation of this paper:
Wade, Andrew D.; Nelson, Andrew J.; and Garvin, Gregory J., "Another Hole in the Head? Brain Treatment in Ancient Egyptian Mummies" (2010). *Anthropology Presentations.* Paper 5.
http://ir.lib.uwo.ca/anthropres/5

Another Hole in the Head? Brain Treatment in Ancient Egyptian Mummies

Andrew D Wade[1], Andrew J Nelson[1], Gregory J Garvin[2]

[1]Department of Anthropology, University of Western Ontario & [2]St. Joseph's Health Care, London

Introduction

Perhaps the most sensational and best-known feature of Egyptian mummification, the removal of the brain, is commonly attributed to the New Kingdom onward (e.g. [1]). Variability both within and between excerebration techniques, however, is poorly appreciated in the literature [2], and reporting of excerebration is often inconsistent, greatly simplified, or simply absent in descriptions of mummified remains, making detailed comparative studies difficult if not impossible.

The goals of this study were to demonstrate:

- variability in mummy excerebration techniques
- temporal and status trends in brain treatment
- the limitations of the literature for large studies

This study focuses on computed tomography (CT), as a non-destructive gold standard for mummies studies, in the examination of three primary treatments of the brain in mummification:

(1) transnasal craniotomy (TNC)
(2) transforaminal craniotomy (TFC)
(3) the absence of excerebration

in relation to their radiological indications and their variations with time and status.

Ancient Sources

Ancient Egyptian descriptions of the mummification process are extremely rare, limited to two ritual papyri and to scenes from the coffin of Djedbastiufankh. Herodotus discussed excerebration as part of the most elaborate mummification rituals. While he provided the most complete account of the mummification process in the ancient literature, its utility is limited in consideration of the mummification practice as it evolved over three millennia and by its imprecise observations.

Samples

Sample of 125 dated mummies described in the literature:

- 92 transnasal craniotomies (TNC)
- 6 transforaminal craniotomies (TFC)
- 27 intact brains

Direct radiological survey of 6 additional mummies:

- 1: Lady Hudson – *Roman Period*
- 2: Djedmaatesankh – *22nd Dynasty*
- 3: Pa-Ib – *Late Period*
- 4: ROM 910.5.3 – *21st Dynasty*
- 5: Hetep-Bastet – *26th Dynasty*
- 6: Sulman Mummy – *Ptolemaic Period*

Transnasal Craniotomy

Transnasal craniotomy (**TNC**) is the most widely applicable description [3] of the best-known Egyptian excerebration process in which a trocar-like tool is inserted into the nose to perforate the thin table of bone between it and the anterior cranial fossa. The lacy cribriform plate is, as the path of least resistance, presumed to be the embalmer's target, but the sphenoid, nasal septum, pituitary fossa, and orbits are also often affected.

A preference for entry through one nostril, the left, over the other is often cited (e.g. [4]), but this distinction is often difficult to evaluate.

In some cases, following extraction of the brain and cleansing of the cranial cavity, embalmers filled the cranial cavity with large quantities of linen or variable quantities of resin. Finally, the nasal passage and artificial foramen were then typically sealed with resin-impregnated rolls (tampons) of linen.

Figures 1 to 3 (top row) illustrate some of this wide variability in the crania of three individuals.

Transforaminal Craniotomy

Removal of the brain by way of the foramen magnum, or transforaminal craniotomy (**TFC**), is not a well-documented or well-understood excerebration technique and only a handful of likely examples (e.g. [5], [6]) have been reported.

Mummies in which the brain is absent and in which the ethmoid and sphenoid are undamaged are assumed to have undergone this method. It is supposed that mummies of this description, showing damage to the atlas and axis or lower cervical vertebrae, are further evidence of trans-foraminal craniotomy. Discrete damage to the skin at the posterior of the skull base, or wrappings that intrude into the foramen magnum, are also suggestive of an embalming incision at the base of the skull for the purpose of TFC.

A geographic pattern has been proposed, with TFC carried out by a Memphite school of Embalming and TNC carried out by a Theban school [7], but has not yet been tested.

Figure 5 (bottom row, middle) illustrates these features in an suspected case of transforaminal craniotomy.

Intact Crania

In many mummies the brain was not removed, by either the transnasal or transforaminal route, but left intact. While the possibility of mummification of the brain was questioned by early researchers, Smith ([8]:377) confirms the presence of intact mummified brains in skeletal remains stating that,

> *[t]he intracranial masses undoubtedly consist of brain material which must have become dried and preserved by the operation of natural processes. The brain is preserved in this manner in the vast majority of the bodies in Egyptian cemeteries. I have seen a prehistoric cemetery containing nearly 500 bodies, in every one of which the brain was preserved...*

Since that time, intact mummified brains have been clearly identified in numerous Egyptian mummies (e.g. [9]).

Figures 4 and 6 (bottom row, ends) illustrate the radiological appearance of the brain and its disposition in two intact crania.

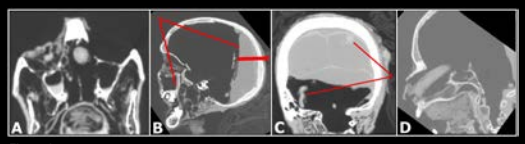

Figure 1. CT scan of Lady Hudson, showing (A) the damaged orbit and ethmoid air cells, (B) resin pooled in the posterior of the cranium and maxillary sinus (thin lines), a potential sphenoid fragment (thick line), (C) resin-impregnated linen rolls (indicated), and (D) the nasal tampon.

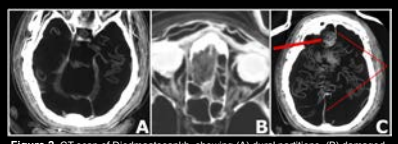

Figure 2. CT scan of Djedmaatesankh, showing (A) dural partitions, (B) damaged ethmoid air cells, (C) a nasal tampon (thick line), and the severed falx cerebri (thin lines) crossed by linen packing.

Figure 3. CT scan of Pa-Ib, showing (A) the absence of brain and dura, (B) the damaged orbit and ethmoid air cells, (C) the damaged sphenoid, and (D) resin and bone fragments in posterior cranium.

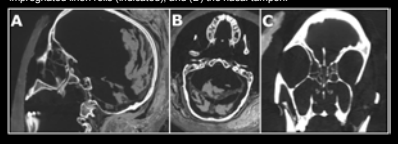

Figure 4. CT scan of ROM 910.5.3, showing (A) the intact brain, (B) the dural partitions, and (C) the intact turbinates, nasal septum, and ethmoid air cells.

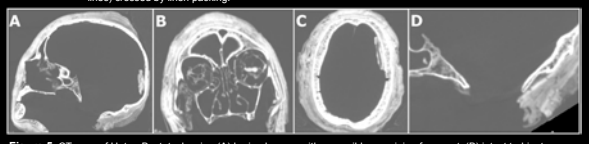

Figure 5. CT scan of Hetep-Bastet, showing (A) brain absence with a possible remaining fragment, (B) intact turbinates, nasal septum, and ethmoid air cells, (C) resin-impregnated linen adherent to the cranium internally, and (D) the margin of the wrappings in relation to the foramen magnum.

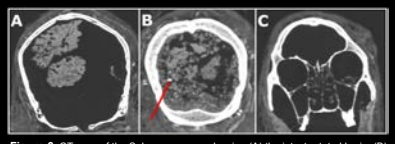

Figure 6. CT scan of the Sulman mummy, showing (A) the intact rotated brain, (B) granular fragmentation of the brain posteriorly, a potential basilar occiput fragment (indicated), and (C) intact turbinates, nasal septum, and ethmoid air cells.

Brain Treatment Trends

Where descriptions permitted, the sample was considered with respect to status. Status was divided coarsely into Elite and Commoner remains, following Kemp who divides Egyptian society into three status groups; "*literate men…those subordinate to them (doorkeepers, soldiers, quarrymen, and so on), and the illiterate peasantry*" ([10]:81) who were not mummified.

For all three brain treatments, elite use preceded commoner use in this sample by two to three historic periods (Figure 7, below), lending support to Strouhal's assertion ([11]:860) that "[e]very new achievement was reserved initially for the king, later for the members of his family and the highest officials, and only gradually became accessible to members of the middle class". Given that the earliest secure examples of TNC are nobles and queens in the Middle Kingdom, it is logical that the origin of TNC belongs to an even earlier period.

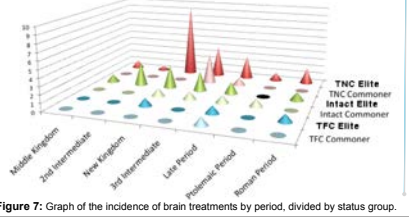

Figure 7: Graph of the incidence of brain treatments by period, divided by status group.

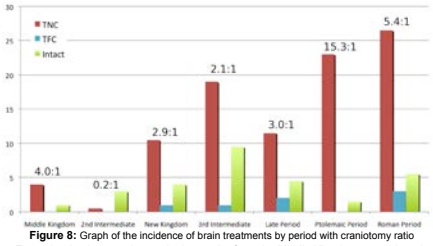

Figure 8: Graph of the incidence of brain treatments by period with craniotomy ratio

Excerebration became increasingly popular from the Middle Kingdom onward, and likely finds its peak popularity in the Ptolemaic and Roman Periods (Figure 8, above). The ratio of excerebrated-to-intact crania (over each bar set), primarily TNC, is 15:1 in the Ptolemaic Period and 5:1 in the Roman Period. The number of mummies exhibiting craniotomies in the Late Period decreases relative to the apparent trend, but, owing to a scarcity of Late Period mummies generally [12], this number remains an indicator of substantial application of the TNC treatment.

G-tests showed no significant difference ($p = .628$) between distributions from the New Kingdom to Late Period, for all three treatments, and a significant difference between these three and the Ptolemaic Period ($p = .001$). The difference between the Ptolemaic and Roman Periods was not conservatively significant ($p = .097$), although the pattern may still be of cultural importance, inviting further investigation of other ways these two periods might differ.

Discussion

Details related to the transnasal route, including side preference and the extent of direct and indirect damage, often go unreported in the literature. Descriptions inconsistently reported the presence of brain remnants, dural remnants, bone fragments, and packing materials. As a result, assessment of brain treatment was limited here to broad categories (TNC, TFC, Intact).

The traditional understanding of the Late-to-Roman Periods, as being increasingly in favour of external elaborations (e.g., complex geometric wrappings) rather than internal mummification features, appears to be strongly contradicted by the increased incidence and prevalence of excerebration, specifically TNC, in these periods. The sharp decrease in excerebration and TNC prevalence in the Roman Period may indicate the general decline in intensive mummification toward the end of the Roman Period. Additionally, TNC presence in a substantial number of commoner mummies belies the emphasis placed on it by Herodotus as a feature specific to the most elaborate (elite) of mummification procedures.

These findings necessitate closer examination of:

- variable mummification features in these periods
- how the Ptolemaic differs from prior periods
- how those differences impacted mortuary ritual

Conclusions

In spite of an apparent high degree of variability, the literature continues to focus on stereotypes, modern and classical. Reporting limitations in the literature highlight the need for detailed, consistent descriptions of Egyptian mummified remains. Despite the inadequacy of much of the literature to provide details for large-scale comparative studies, there is evidence of substantial variability. Some is expressed in this sample, which demonstrated an unexpected increase in excerebration peaking in the Ptolemaic; the possibility of very early beginnings for TNC, even as early as the Fourth Dynasty; and the precedence of elite mummification and excerebration to that of the middle class. Detailed, large-scale examinations of this and other mummification traditions, and their meanings, are required to further our understanding of this important early complex society.

IMPACT Mummy dBase

Currently, an international, collaborative Egyptian mummy database, is being established by the authors at Western to undertake large-scale radiological examinations of variability in patterns of health and disease and of mummification practices within and between time periods.

Literature Cited

[1] Iskander Z. 1980 Mummification in ancient Egypt: Development, history, and techniques. In: Harris JE, Wente EF, editors. An X-ray Atlas of the Royal Mummies. Chicago: University of Chicago Press. p.1-51
[2] Nelson AJ, Conlogue G, Beckett R, Posh J, Chhem R, Wright E, Rogers J. 2007. Multimodal analyses of variability in transnasal craniotomy lesions in Egyptian mummies. Paleopathology Association meeting, March 27, 2007
[3] Aufderheide AC. 1998. The Cambridge encyclopedia of human paleopathology. Cambridge: Cambridge University Press
[4] Pirsig W, Parsche F. 1991. Instruments for transnasal brain removal during embalming by the ancient Egyptians. International Journal of Anthropology 6(1):67-74
[5] Merigaud S. 2007. Etude paleoradiologique des deux momies Egyptiennes du Musee des Beaux Arts et d'Archaeologie de Besancon. MD Thesis, Universite de Franche Comte
[6] Nelson AJ. 2008. Preliminary report on the radiological examination of Hetep-Bastet. Internal Report for Galerie de l'Universite du Quebec a Montreal (UQAM), December 16, 2008
[7] Shafik M, Selim A, El Sheikh I, Hawass Z. 2008. Computed tomography of King Tut-Ankh-Amen. The Ambassadors Online Magazine 11(23):Selected Study 3 <http://ambassadors.net/archives/issue23/selectedstudy3.htm>
[8] Smith GE. 1902. On the natural preservation of the brain in the ancient Egyptians. Journal of Anatomy and Physiology July:375-381
[9] Lewin PK, Harwood-Nash DC. 1977. X-ray computed axial tomography of an ancient Egyptian brain. IRCS Medical Science: Anatomy and Human Biology: Biomedical Technology: Nervous System 5:78
[10] Kemp BJ. 1983. Old Kingdom, Middle Kingdom and Second Intermediate Period *c.* 2686-1552 BC. In: Trigger BG, Kemp BJ, O'Connor D, Lloyd AB, editors. Ancient Egypt: A social history. Cambridge: Cambridge University Press. p.71-182
[11] Strouhal E. 1995. Secular changes of embalming methods in ancient Egypt. Proceedings of the I World Congress on Mummy Studies. Santa Cruz de Tenerife, Canary Islands: Museo Arqueologico. p.859-866
[12] Aufderheide AC. 2003. The scientific study of mummies. Cambridge: Cambridge University Press

Acknowledgments

The authors would like to thank Drs. Gerald Conlogue and Ronald Beckett of Quinnipiac University for access to the Pa-Ib data; Stephanie Holowka of Toronto's Sick Kids Hospital for access to the Djedmaatesankh data; the Royal Ontario Museum and Université du Québec à Montréal for the opportunities to scan their mummies; and the St. Joseph's Health Care radiology department for their training and assistance. Funding for this project was provided by a SSHRC CGS (ADW), an Ontario Graduate Scholarship (ADW), and a Faculty Scholar Grant (AJN). Funding for the ROM scans was provided by the Deans of Social Science and Medicine and the VP Research at Western.

For further information

Please contact *awade4@uwo.ca*.
Andrew Wade
c/o Department of Anthropology,
Social Science Centre
University of Western Ontario,
London, ON, N6A 5C2